



www.ofthalmoloji.org

E-ISSN: 2149-8709

TURKISH JOURNAL OF OPHTHALMOLOGY

TURKISH JOURNAL OF OPHTHALMOLOGY

TJO

Perspective

The COVID-19 Pandemic: Clinical Information for Ophthalmologists

Banu Bozkurt et al.; Konya, Izmir, Istanbul, Mersin, Ankara, Turkey

Research Articles

Investigation of TGFBI (transforming growth factor beta-induced) Gene Mutations in Families with Granular Corneal Dystrophy Type 1 in the Konya Region

Fatma Malkondu et al.; Konya, Turkey

Anterior Segment Analysis and Evaluation of Corneal Biomechanical Properties in Children with Joint Hypermobility

Sadık Etkay Bayramoğlu et al.; Istanbul, Diyarbakir, Şanlıurfa, Turkey

Correlation of Ocular Surface Disease and Quality of Life in Indian Glaucoma Patients: BAC-preserved versus BAC-free Travoprost

Suresh Kumar et al.; Chandigarh, India

The Effect of Inferior Oblique Muscle Z-Myotomy in Patients with Primary Inferior Oblique Overaction

Hasan Kızıltoprak et al.; Bingöl, Ankara, Van, Turkey

Can Complete Blood Count Parameters Predict Retinopathy of Prematurity?

Ayşe İpek Akyüz Ünsal et al.; Aydın, Turkey

Characteristics and Seasonal Variations of Rhegmatogenous Retinal Detachment in the Eastern Black Sea Region of Turkey: 8-Year Results

Hidayet Erdöl et al.; Trabzon, Turkey

Review

Artifacts and Anatomic Variations in Optical Coherence Tomography

Atilla Bayer and Ahmet Akman; Ankara, Turkey

Case Reports

Fungal Keratitis, or Misled by a Small Insect?

Betül Nureşan Bayraktutar et al.; Boston, USA; Istanbul, Turkey

Unusual Association of Inverse Retinitis Pigmentosa, Scleromalacia, and Neovascular Glaucoma

Ayşe Gül Koçak Alintaş et al.; Ankara, Hatay, Turkey

Anterior Chamber Migration of Ozurdex Implants

Özcan Kayıkçıoğlu et al.; Manisa, Uşak, Turkey

Acute Macular Neuroretinopathy in Purtscher Retinopathy

Berrak Şekeryapan Gediz; Ankara, Turkey

TURKISH JOURNAL OF OPHTHALMOLOGY



www.ofthalmoloji.org

TJO

Editor-in-Chief

Murat İRKEÇ, MD

Hacettepe University Faculty of Medicine, Department of Ophthalmology, Ankara, Turkey

Areas of Interest: Cornea and Ocular Surface Disease, Glaucoma, Allergy and Immunology

E-mail: mirkec@hacettepe.edu.tr

ORCID ID: orcid.org/0000-0001-8892-4811

Associate Editors

Tomris ŞENGÖR, MD

İstanbul Bilim University Faculty of Medicine, Department of Ophthalmology, İstanbul, Turkey

Areas of Interest: Cornea and Ocular Surface Disease, Contact Lens

E-mail: tomris.sengor@gmail.com

ORCID ID: orcid.org/0000-0002-9436-5582

Sait EĞRİLMEZ, MD

Ege University Faculty of Medicine, Department of Ophthalmology, İzmir, Turkey

Areas of Interest: Cornea and Ocular Surface Disease, Contact Lens, Refraction, Cataract and Refractive Surgery

E-mail: saitegrilmez@gmail.com

ORCID ID: orcid.org/0000-0002-6971-527X

Özlem YILDIRIM, MD

Mersin University Faculty of Medicine, Department of Ophthalmology, Mersin, Turkey

Areas of Interest: Uveitis, Medical Retina, Glaucoma

E-mail: dryildirimoz@hotmail.com

ORCID ID: orcid.org/0000-0002-3773-2497

Banu BOZKURT, MD, FEBO

Selçuk University Faculty of Medicine, Department of Ophthalmology, Konya, Turkey

Areas of Interest: Cornea and Ocular Surface Disease, Glaucoma, Allergy and Immunology

E-mail: drbanubozkurt@yahoo.com

ORCID ID: orcid.org/0000-0002-9847-3521

Statistical Board

Ahmet DİRİCAN

İstanbul University İstanbul Faculty of Medicine, Department of Biostatistics and Medical Informatics, İstanbul, Turkey

English Language Editor

Jacqueline Renee GUTENKUNST, Maryland, USA

Publishing House

Molla Gürani Mah. Kaçamak Sokak No: 21,
34093 Fındıkzade-İstanbul-Turkey

Publisher Certificate Number: 14521

Phone: +90 212 621 99 25 Fax: +90 212 621 99 27

E-mail: info@galenos.com.tr

Online Publishing Date: May 2020

International scientific journal published bimonthly.

E-ISSN: 2149-8709



Advisory Board

Yonca AYDIN AKOVA,

Bayındır Kavaklıdere Hospital, Ophthalmology Clinic, Ankara, Turkey

Mustafa Kemal ARICI,

Bezmialem Vakıf University Faculty of Medicine, Department of Ophthalmology, İstanbul, Turkey

Atila BAYER,

Ophthalmology, Dünyagöz Hospital, Ankara, Turkey

Kamil BİLGİHAN,

Gazi University Faculty of Medicine, Department of Ophthalmology, Ankara, Turkey

İzzet CAN,

Ophthalmology, Independent Practitioner, Ankara, Turkey

Jose M. BENİTEZ-del-CASTILLO,

Universidad Complutense de Madrid, Hospital Clinico San Carlos, Department of Ophthalmology, Madrid, Spain

Murat DOĞRU,

Keio University Faculty of Medicine, Department of Ophthalmology, Tokyo, Japan

Şansal GEDİK,

Selçuk University Faculty of Medicine, Department of Ophthalmology, Konya, Turkey

Ömür UÇAKHAN GÜNDÜZ,

Ankara University Faculty of Medicine, Department of Ophthalmology, Ankara, Turkey

Banu Melek HOŞAL,

Ankara University Faculty of Medicine, Department of Ophthalmology, Ankara, Turkey

Sibel ÇALIŞKAN KADAYIFÇILAR,

Hacettepe University Faculty of Medicine, Department of Ophthalmology, Ankara, Turkey

Murat KARAÇORLU,

İstanbul Retina Institute, Ophthalmology Clinic, İstanbul, Turkey

Sarper KARAKÜÇÜK,

Anadolu Medical Center, Ophthalmology Clinic, Kocaeli, Turkey

Tero KİVELÄ,

University of Helsinki, Helsinki University Hospital, Department of Ophthalmology, Helsinki, Finland

Hayyam KIRATLI,

Hacettepe University Faculty of Medicine, Department of Ophthalmology, Ankara, Turkey

Anastasios G.P. KONSTAS,

Aristotle University of Thessaloniki, Department of Ophthalmology, Thessaloniki, Greece

Anat LOEWENSTEIN,

Tel Aviv University Sackler Faculty of Medicine, Department of Ophthalmology, Tel Aviv, Israel

Mehmet Cem MOCAN,

University of Illinois at Chicago, Department of Ophthalmology and Visual Sciences, Chicago

Pınar AYDIN O'DWYER,

Ophthalmology, Independent Practitioner, Ankara, Turkey

Şengül ÖZDEK,

Gazi University Faculty of Medicine, Department of Ophthalmology, Ankara, Turkey

Hakan ÖZDEMİR,

Bezmialem Vakıf University Faculty of Medicine, Department of Ophthalmology, İstanbul, Turkey

Banu TURGUT ÖZTÜRK,

Selçuk University Faculty of Medicine, Department of Ophthalmology, Konya, Turkey

Seyhan Bahar ÖZKAN,

Adnan Menderes University Faculty of Medicine, Department of Ophthalmology, Aydın, Turkey

Afsun ŞAHİN,

Koç University Faculty of Medicine, Department of Ophthalmology, İstanbul, Turkey

H. Nida ŞEN,

George Washington University, National Eye Institute, Department of Ophthalmology, Washington, USA

İlknur TUĞAL-TUTKUN,

İstanbul University İstanbul Faculty of Medicine, Department of Ophthalmology, İstanbul, Turkey

Nilgün YILDIRIM,

Eskişehir Osmangazi University Faculty of Medicine, Department of Ophthalmology, Eskişehir, Turkey

Nurşen YÜKSEL,

Kocaeli University Faculty of Medicine, Department of Ophthalmology, Kocaeli, Turkey

The Turkish Journal of Ophthalmology is an official journal of the Turkish Ophthalmological Association.

On Behalf of Turkish Ophthalmological Association Owner

Osman Şevki ARSLAN,

İstanbul University Cerrahpaşa Faculty of Medicine, Department of Ophthalmology, İstanbul, Turkey

TURKISH JOURNAL OF OPHTHALMOLOGY



www.ofthalmoloji.org

TJO

ABOUT US

The Turkish Journal of Ophthalmology (TJO) is the only scientific periodical publication of the Turkish Ophthalmological Association and has been published since January 1929. In its early years, the journal was published in Turkish and French. Although there were temporary interruptions in the publication of the journal due to various challenges, the Turkish Journal of Ophthalmology has been published continually from 1971 to the present.

The Turkish Journal of Ophthalmology is currently published in Turkish and English languages. TJO is an independent international periodical journal based on single-blind peer-review principle. TJO is regularly published six times a year and special issues are occasionally released. The aim of TJO is to publish original research papers of the highest scientific and clinical value at an international level. Furthermore, review articles, case reports, editorial comments, letters to the editor, educational contributions and congress/meeting announcements are released.

The target audience includes specialists and physicians in training in ophthalmology in all relevant disciplines.

The editorial policies are based on the "Recommendations for the Conduct, Reporting, Editing, and Publication of Scholarly Work in Medical Journals (ICMJE Recommendations)" by the International Committee of Medical Journal Editors (2013, archived at <http://www.icmje.org/>) rules.

The Turkish Journal of Ophthalmology is indexed in the **PubMed/MEDLINE, PubMed Central (PMC), Web of Science-Emerging Sources Citation Index (ESCI), Scopus, TUBITAK/ULAKBIM, Directory of Open Access Journals (DOAJ), EBSCO Database, CINAHL, Proquest, Embase, British Library, Index Copernicus, J-Gate, ROOT INDEXING, IdealOnline, Turk Medline, Hinari, GOALI, ARDI, OARE** and **Turkish Citation Index**.

Open Access Policy

This journal provides immediate open access to its content on the principle that making research freely available to the public supports a greater global exchange of knowledge.

Open Access Policy is based on the rules of the Budapest Open Access Initiative (BOAI) <http://www.budapestopenaccessinitiative.org/>. By "open access" to peer-reviewed research literature, we mean its free availability on the public internet, permitting any users to read, download, copy, distribute, print, search, or link to the full texts of these articles, crawl them for indexing, pass them as data to software, or use them for any other lawful purpose, without financial, legal, or technical barriers other than those inseparable from gaining access to the internet itself. The only constraint on reproduction and distribution, and the only role for copyright in this domain, should be to give authors control over the integrity of their work and the right to be properly acknowledged and cited.

Subscription Information

TJO is sent free of charge to subscribers. Address changes should be immediately reported to the affiliates and to the managing editor. Subscribers who do not receive the journal in the relevant time period should contact the managing editor. All published volumes in full text can be reached free of charge through the website www.ofthalmoloji.org. Requests for subscription should be addressed to the Turkish Ophthalmological Association.

Manuscripts can only be submitted electronically through the Journal Agent website (<http://journalagent.com/tjo/>) after creating an account. This system allows online submission and review.

Membership Procedures

Turkish Ophthalmological Association

Bank Account: Yapı Kredi Bankası, Şehremini Şubesi 65774842

IBAN: TR10 0006 7010 0000 0065 7748 42

Annual Subscription: Domestic: 100.-TL (Tax Incl)

Abroad: 100 USD (Tax Incl.)

Correspondence Address

Editor-in-Chief, Murat İrkeç, MD, Professor in Ophthalmology
Hacettepe University Faculty of Medicine, Department of Ophthalmology
06100 Sıhhiye-Ankara-Turkey

Phone: +90 212 801 44 36/37 Fax: +90 212 801 44 39

E-mail: mirkec@hacettepe.edu.tr

Secretary, Selvinaz Arslan

E-mail: dergi@ofthalmoloji.org - sekreter@ofthalmoloji.org

Address: Avrupa Konutları Kale, Maltepe Mah. Yedikule Çırpıcı Yolu Sk.

9. Blok No: 2 Kat:1 Ofis:1 Zeytinburnu-Istanbul-Turkey

Phone: +90 536 656 87 26 Fax: +90 212 801 44 39

Web Page: www.ofthalmoloji.org

Permissions

Requests for permission to reproduce published material should be sent to the editorial office.

Editor-in-Chief: Murat İrkeç, MD, Professor in Ophthalmology

Address: Avrupa Konutları Kale, Maltepe Mah. Yedikule Çırpıcı Yolu Sk.

9. Blok No: 2 Kat:1 Ofis:1 Zeytinburnu-Istanbul-Turkey

Phone: +90 212 801 44 36/37 Fax: +90 212 801 44 39

Web Page: www.ofthalmoloji.org

E-mail: dergi@ofthalmoloji.org - sekreter@ofthalmoloji.org

Advertisement

Applications for advertisement should be addressed to the editorial office.

Address: Avrupa Konutları Kale, Maltepe Mah. Yedikule Çırpıcı Yolu Sk.

9. Blok No: 2 Kat:1 Ofis:1 Zeytinburnu-Istanbul-Turkey

Phone: +90 212 801 44 36/37 Fax: +90 212 801 44 39

Web Page: www.ofthalmoloji.org

E-mail: dergi@ofthalmoloji.org - sekreter@ofthalmoloji.org

Publisher Corresponding Address

Publisher: Erkan Mor

Galenos Yayınevi Tic. Ltd. Şti.

Address: Molla Gürani Mah. Kaçamak Sk. No: 21, 34093

Fındıkzade-Istanbul-Turkey

Phone: +90 212 621 99 25 Fax: +90 212 621 99 27

E-mail: info@galenos.com.tr

Instructions for Authors

Instructions for authors are published in the journal and on the website www.ofthalmoloji.org

Material Disclaimer

The author(s) is (are) responsible for the articles published in the Turkish Journal of Ophthalmology.

The editor, editorial board and publisher do not accept any responsibility for the articles.

The journal is printed on acid-free paper.

This work is licensed under a Creative Commons Attribution-Non Commercial-No Derivatives 4.0 International License.

INSTRUCTIONS TO AUTHORS

The Turkish Journal of Ophthalmology is an official peer-reviewed publication of the Turkish Ophthalmological Association. Accepted manuscripts are printed in Turkish and published online in both Turkish and English languages. Manuscripts written in Turkish should be in accordance with the Turkish Dictionary and Writing Guide ("Türkçe Sözlüğü ve Yazım Kılavuzu") of the Turkish Language Association. Turkish forms of ophthalmology-related terms should be checked in the TODNET Dictionary ("TODNET Sözlüğü" <http://www.todnet.org/sozlu/>) and used accordingly.

The Turkish Journal of Ophthalmology does not charge any article submission or processing charges.

A manuscript will be considered only with the understanding that it is an original contribution that has not been published elsewhere.

Reviewed and accepted manuscripts are translated either from Turkish to English or from English to Turkish by the Journal through a professional translation service. Prior to publishing, the translations are submitted to the authors for approval or correction requests, to be returned within 7 days. If no response is received from the corresponding author within this period, the translation is checked and approved by the editorial board.

The abbreviation of the Turkish Journal of Ophthalmology is TJO, however, it should be denoted as Turk J Ophthalmol when referenced. In the international index and database, the name of the journal has been registered as Turkish Journal of Ophthalmology and abbreviated as Turk J Ophthalmol.

The scientific and ethical liability of the manuscripts belongs to the authors and the copyright of the manuscripts belongs to the Turkish Journal of Ophthalmology. Authors are responsible for the contents of the manuscript and accuracy of the references. All manuscripts submitted for publication must be accompanied by the Copyright Transfer Form. Once this form, signed by all the authors, has been submitted, it is understood that neither the manuscript nor the data it contains have been submitted elsewhere or previously published and authors declare the statement of scientific contributions and responsibilities of all authors.

All manuscripts submitted to the Turkish Journal of Ophthalmology are screened for plagiarism using the 'iThenticate' software. Results indicating plagiarism may result in manuscripts being returned or rejected.

Experimental, clinical and drug studies requiring approval by an ethics committee must be submitted to the Turkish Journal of Ophthalmology with an ethics committee approval report confirming that the study was conducted in accordance with international agreements and the Declaration of Helsinki (revised 2013) (<https://www.wma.net/policies-post/wma-declaration-of-helsinki-ethical-principles-for-medical-research-involving-human-subjects/>). The approval of the ethics committee and the fact that informed consent was given by the patients should be indicated in the Materials and Methods section. In experimental animal studies, the authors should indicate that the procedures followed were in accordance with animal rights as per the Guide for the Care and Use of Laboratory Animals (<http://oacu.od.nih.gov/regs/guide/guide.pdf>) and they should obtain animal ethics committee approval.

Authors must provide disclosure/acknowledgment of financial or material support, if any was received, for the current study.

If the article includes any direct or indirect commercial links or if any institution provided material support to the study, authors must state in the cover letter that they have no relationship with the commercial product, drug, pharmaceutical company, etc. concerned; or specify the type of relationship (consultant, other agreements), if any.

Authors must provide a statement on the absence of conflicts of interest among the authors and provide authorship contributions.

The Turkish Journal of Ophthalmology is an independent international journal based on single-blind peer-review principles. The manuscript is assigned to the Editor-in-Chief, who reviews the manuscript and makes an initial decision based on manuscript quality and editorial priorities. Manuscripts that pass initial evaluation are sent for external peer review, and the Editor-in-Chief assigns an Associate Editor. The Associate Editor sends the manuscript to three reviewers (internal and/or external reviewers). The reviewers must review the manuscript within 21 days. The Associate Editor recommends a decision based on the reviewers' recommendations and returns the manuscript to the Editor-in-Chief. The Editor-in-Chief makes a final decision based on editorial priorities, manuscript quality, and reviewer recommendations. If there are any conflicting recommendations from reviewers, the Editor-in-Chief can assign a new reviewer.

The scientific board guiding the selection of the papers to be published in the Journal consists of elected experts of the Journal and if necessary, selected from national and international authorities. The Editor-in-Chief, Associate Editors, biostatistics expert and English language consultant may make minor corrections to accepted manuscripts that do not change the main text of the paper.

In case of any suspicion or claim regarding scientific shortcomings or ethical infringement, the Journal reserves the right to submit the manuscript to the supporting institutions or other authorities for investigation. The Journal accepts the responsibility of initiating action but does not undertake any responsibility for an actual investigation or any power of decision.

The Editorial Policies and General Guidelines for manuscript preparation specified below are based on "Recommendations for the Conduct, Reporting, Editing, and Publication of Scholarly Work in Medical Journals (ICMJE Recommendations)" by the International Committee of Medical Journal Editors (2013, archived at <http://www.icmje.org/>).

Preparation of research articles, systematic reviews and meta-analyses must comply with study design guidelines: CONSORT statement for randomized controlled trials (Moher D, Schulz KF, Altman D, for the CONSORT Group. The CONSORT statement revised recommendations for improving the quality of reports of parallel group randomized trials. *JAMA* 2001; 285: 1987-91) (<http://www.consort-statement.org/>);

PRISMA statement of preferred reporting items for systematic reviews and meta-analyses (Moher D, Liberati A, Tetzlaff J, Altman DG, The PRISMA Group. Preferred Reporting Items

for Systematic Reviews and Meta-Analyses: The PRISMA Statement. *PLoS Med* 2009; 6(7): e1000097.) (<http://www.prisma-statement.org/>);

STARD checklist for the reporting of studies of diagnostic accuracy (Bossuyt PM, Reitsma JB, Bruns DE, Gatsonis CA, Glasziou PP, Irwig LM, et al., for the STARD Group. Towards complete and accurate reporting of studies of diagnostic accuracy: the STARD initiative. *Ann Intern Med* 2003;138:40-4.) (<http://www.stard-statement.org/>);

STROBE statement, a checklist of items that should be included in reports of observational studies (<http://www.strobe-statement.org/>);

MOOSE guidelines for meta-analysis and systemic reviews of observational studies (Stroup DF, Berlin JA, Morton SC, et al. Meta-analysis of observational studies in epidemiology: a proposal for reporting Meta-analysis of observational Studies in Epidemiology (MOOSE) group. *JAMA* 2000; 283: 2008-12).

GENERAL GUIDELINES

Manuscripts can only be submitted electronically through the Journal Agent website (<http://journalagent.com/tjo/>) after creating an account. This system allows online submission and review.

The manuscripts are archived according to ICMJE, Index Medicus (Medline/PubMed) and Ulakbim-Turkish Medicine Index Rules.

Format: Manuscripts should be prepared using Microsoft Word, size A4 with 2.5 cm margins on all sides, 12 pt Arial font and 1.5 line spacing.

Abbreviations: Abbreviations should be defined at first mention and used consistently thereafter. Internationally accepted abbreviations should be used; refer to scientific writing guides as necessary.

Cover letter: The cover letter should include statements about manuscript type, single-journal submission affirmation, conflict of interest statement, sources of outside funding, equipment (if applicable), approval of language for articles in English and approval of statistical analysis for original research articles.

REFERENCES

Authors are solely responsible for the accuracy of all references.

In-text citations: References should be indicated as a superscript immediately after the period/full stop of the relevant sentence. If the author(s) of a reference is/are indicated at the beginning of the sentence, this reference should be written as a superscript immediately after the author's name. If relevant research has been conducted in Turkey or by Turkish investigators, these studies should be given priority while citing the literature.

Presentations presented in congresses, unpublished manuscripts, theses, Internet addresses, and personal interviews or experiences should not be indicated as references. If such references are used, they should be indicated in parentheses at the end of the relevant sentence in the text, without reference number and written in full, in order to clarify their nature.

References section: References should be numbered consecutively in the order in which they are first mentioned in the text. All authors should be listed regardless of number.

INSTRUCTIONS TO AUTHORS

The titles of journals should be abbreviated according to the style used in the Index Medicus.

Reference Format

Journal: Last name(s) of the author(s) and initials, article title, publication title and its original abbreviation, publication date, volume, the inclusive page numbers. Example: Collin JR, Rathbun JE. Involitional entropion: a review with evaluation of a procedure. Arch Ophthalmol. 1978;96:1058-1064.

Book: Last name(s) of the author(s) and initials, chapter title, book editors, book title, edition, place of publication, date of publication and inclusive page numbers of the extract cited. Example: Herbert L. The Infectious Diseases (1st ed). Philadelphia; Mosby Harcourt; 1999:11;1-8.

Book Chapter: Last name(s) of the author(s) and initials, chapter title, book editors, book title, edition, place of publication, date of publication and inclusive page numbers of the cited piece.

Example: O'Brien TP, Green WR. Periocular Infections. In: Feigin RD, Cherry JD, eds. Textbook of Pediatric Infectious Diseases (4th ed). Philadelphia; W.B. Saunders Company; 1998:1273-1278.

Books in which the editor and author are the same person: Last name(s) of the author(s) and initials, chapter title, book editors, book title, edition, place of publication, date of publication and inclusive page numbers of the cited piece. Example: Solcia E, Capella C, Kloppel G. Tumors of the exocrine pancreas. In: Solcia E, Capella C, Kloppel G, eds. Tumors of the Pancreas. 2nd ed. Washington: Armed Forces Institute of Pathology; 1997:145-210.

TABLES, GRAPHICS, FIGURES, AND IMAGES

All visual materials together with their legends should be located on separate pages that follow the main text.

Images: Images (pictures) should be numbered and include a brief title. Permission to reproduce pictures that were published elsewhere must be included. All pictures should be of the highest quality possible, in JPEG format, and at a minimum resolution of 300 dpi.

Tables, Graphics, Figures: All tables, graphics or figures should be enumerated according to their sequence within the text and a brief descriptive caption should be written. Any abbreviations used should be defined in the accompanying legend. Tables in particular should be explanatory and facilitate readers' understanding of the manuscript, and should not repeat data presented in the main text.

BIOSTATISTICS

To ensure controllability of the research findings, the study design, study sample, and the methodological approaches and applications should be explained and their sources should be presented.

The "P" value defined as the limit of significance along with appropriate indicators of measurement error and uncertainty (confidence interval, etc.) should be specified. Statistical terms, abbreviations and symbols used in the article should be described and the software used should be defined. Statistical terminology (random, significant, correlation, etc.) should not be used in non-statistical contexts.

All results of data and analysis should be presented in the Results section as tables, figures and graphics; biostatistical methods used and application details should be presented

in the Materials and Methods section or under a separate title.

MANUSCRIPT TYPES

Original Articles

Clinical research should comprise clinical observation, new techniques or laboratories studies. Original research articles should include title, structured abstract, key words relevant to the content of the article, introduction, materials and methods, results, discussion, study limitations, conclusion references, tables/figures/images and acknowledgement sections. Title, abstract and key words should be written in both Turkish and English. The manuscript should be formatted in accordance with the above-mentioned guidelines and should not exceed sixteen A4 pages.

Title Page: This page should include the title of the manuscript, short title, name(s) of the authors and author information. The following descriptions should be stated in the given order:

1. Title of the manuscript (Turkish and English), as concise and explanatory as possible, including no abbreviations, up to 135 characters
2. Short title (Turkish and English), up to 60 characters
3. Name(s) and surname(s) of the author(s) (without abbreviations and academic titles) and affiliations
4. Name, address, e-mail, phone and fax number of the corresponding author
5. The place and date of scientific meeting in which the manuscript was presented and its abstract published in the abstract book, if applicable

Abstract: A summary of the manuscript should be written in both Turkish and English. References should not be cited in the abstract. Use of abbreviations should be avoided as much as possible; if any abbreviations are used, they must be taken into consideration independently of the abbreviations used in the text. For original articles, the structured abstract should include the following sub-headings:

Objectives: The aim of the study should be clearly stated.

Materials and Methods: The study and standard criteria used should be defined; it should also be indicated whether the study is randomized or not, whether it is retrospective or prospective, and the statistical methods applied should be indicated, if applicable.

Results: The detailed results of the study should be given and the statistical significance level should be indicated.

Conclusion: Should summarize the results of the study, the clinical applicability of the results should be defined, and the favorable and unfavorable aspects should be declared.

Keywords: A list of minimum 3, but no more than 5 key words must follow the abstract. Key words in English should be consistent with "Medical Subject Headings (MESH)" (www.nlm.nih.gov/mesh/MBrowser.html). Turkish key words should be direct translations of the terms in MESH.

Original research articles should have the following sections: **Introduction:** Should consist of a brief explanation of the topic and indicate the objective of the study, supported by information from the literature.

Materials and Methods: The study plan should be clearly described, indicating whether the study is randomized or not, whether it is retrospective or prospective, the number of trials, the characteristics, and the statistical methods used.

Results: The results of the study should be stated, with tables/figures given in numerical order; the results should

be evaluated according to the statistical analysis methods applied. See General Guidelines for details about the preparation of visual material.

Discussion: The study results should be discussed in terms of their favorable and unfavorable aspects and they should be compared with the literature. The conclusion of the study should be highlighted.

Study Limitations: Limitations of the study should be discussed. In addition, an evaluation of the implications of the obtained findings/results for future research should be outlined.

Conclusion: The conclusion of the study should be highlighted.

Acknowledgements: Any technical or financial support or editorial contributions (statistical analysis, English/Turkish evaluation) towards the study should appear at the end of the article.

References: Authors are responsible for the accuracy of the references. See General Guidelines for details about the usage and formatting required.

Case Reports

Case reports should present cases which are rarely seen, feature novelty in diagnosis and treatment, and contribute to our current knowledge. The first page should include the title in Turkish and English, an unstructured summary not exceeding 150 words, and key words. The main text should consist of introduction, case report, discussion and references. The entire text should not exceed 5 pages (A4, formatted as specified above).

Review Articles

Review articles can address any aspect of clinical or laboratory ophthalmology. Review articles must provide critical analyses of contemporary evidence and provide directions of current or future research. Most review articles are commissioned, but other review submissions are also welcome. Before sending a review, discussion with the editor is recommended.

Reviews articles analyze topics in depth, independently and objectively. The first chapter should include the title in Turkish and English, an unstructured summary and key words. Source of all citations should be indicated. The entire text should not exceed 25 pages (A4, formatted as specified above).

Letters to the Editor

Letters to the Editor should be short commentaries related to current developments in ophthalmology and their scientific and social aspects, or may be submitted to ask questions or offer further contributions in response to work that has been published in the Journal. Letters do not include a title or an abstract; they should not exceed 1,000 words and can have up to 5 references.

CORRESPONDENCE

All correspondence should be directed to the TJO editorial board:

Post: Turkish Ophthalmological Association
Avrupa Konutları Kale, Maltepe Mah. Yedikule Çırpıcı Yolu
Sk. 9. Blok No: 2 Kat:1 Ofis:1 Zeytinburnu-Istanbul-Turkey
Phone: +90 212 801 44 36/37 Fax: +90 212 801 44 39

Web Page: www.ofthalmoloji.org

E-mail: dergi@ofthalmoloji.org / sekreter@ofthalmoloji.org

TURKISH JOURNAL OF OPHTHALMOLOGY



TJO

CONTENTS

Perspective

- 59 The COVID-19 Pandemic: Clinical Information for Ophthalmologists
Banu Bozkurt, Sait Eğrişmez, Tomris Şengör, Özlem Yıldırım, Murat Irkeç; Konya, İzmir, İstanbul, Mersin, Ankara, Turkey

Research Articles

- 64 Investigation of TGFBI (transforming growth factor beta-induced) Gene Mutations in Families with Granular Corneal Dystrophy Type 1 in the Konya Region
Fatma Malkondu, Hilal Arıkoğlu, Dudu Erkoç Kaya, Banu Bozkurt, Fehmi Özkan; Konya, Turkey
- 71 Anterior Segment Analysis and Evaluation of Corneal Biomechanical Properties in Children with Joint Hypermobility
Sadık Etki Bayramoğlu, Nihat Sayın, Dilbade Yıldız Ekinci, Nuray Aktay Ayaz, Mustafa Çakan; İstanbul, Diyarbakır, Şanlıurfa, Turkey
- 75 Correlation of Ocular Surface Disease and Quality of Life in Indian Glaucoma Patients: BAC-preserved versus BAC-free Travoprost
Suresh Kumar, Tanu Singh, Parul Ichhpujani, Sanchi Vohra, Sahil Thakur; Chandigarh, India
- 82 The Effect of Inferior Oblique Muscle Z-Myotomy in Patients with Primary Inferior Oblique Overaction
Hasan Kızıltoprak, Hakan Halit Yaşar, Kemal Tekin; Bingöl, Ankara, Van, Turkey
- 87 Can Complete Blood Count Parameters Predict Retinopathy of Prematurity?
Ayşe İpek Akyüz Ünsal, Özge Key, Duygu Güler, İmran Kurt Omurlu, Ayşe Anık, Buket Demirci, Sema Dünder; Aydın, Turkey
- 94 Characteristics and Seasonal Variations of Rhegmatogenous Retinal Detachment in the Eastern Black Sea Region of Turkey: 8-Year Results
Hidayet Erdöl, Dilek Uzlu, Mehmet Kola; Trabzon, Turkey

Review

- 99 Artifacts and Anatomic Variations in Optical Coherence Tomography
Atilla Bayer, Ahmet Akman; Ankara, Turkey

Case Reports

- 107 Fungal Keratitis, or Misled by a Small Insect?
Betül Nurefşan Bayraktutar, Ayşe Yıldız Taş, Afsun Şahin; Boston, USA; İstanbul, Turkey
- 110 Unusual Association of Inverse Refinitis Pigmentosa, Scleromalacia, and Neovascular Glaucoma
Ayşe Gül Koçak Altıntaş, Çağrı İlhan, Mehmet Çıtırık; Ankara, Hatay, Turkey
- 115 Anterior Chamber Migration of Ozurdex Implants
Özcan Kayıkcıoğlu, Suzan Doğruya, Cansu Sarıgül, Hüseyin Mayalı, Emin Kurt; Manisa, Uşak, Turkey
- 123 Acute Macular Neuroretinopathy in Purtscher Retinopathy
Berrak Şekeryapan Gediz; Ankara, Turkey

EDITORIAL

Esteemed colleagues,

In the second issue of 2020, the Turkish Journal of Ophthalmology features one perspective, six original studies, one review, and four case reports.

The perspective article, prepared by our editorial board, is a summary of information about the COVID-19 pandemic, which is the top global issue at present, that may help our colleagues protect themselves and their patients. As some of our colleagues are also practicing 'pandemic hospital medicine' as well as ophthalmology during this time, we think this article will be useful in many aspects.

In this issue, Malkondu et al. presents an interesting study of mutations associated with granular corneal dystrophy. Different mutations in the transforming growth factor beta-induced (*TGFBI*) gene, located in the 5q31 locus, lead to granular corneal dystrophy types 1 and 2 (GCD1 and 2), Reis-Bückler corneal dystrophy, lattice corneal dystrophy (LCD), and Thiel-Behnke corneal dystrophy. Because GCD2 was first described in people in the Avellino region of Italy, it is referred to in the literature as Avellino dystrophy. *TGFBI* has a key role in the genetic basis of GCD1, and *TGFBI*-related dystrophies can show clinical variability even among members of the same family. Therefore, this genetic study by Malkondu et al., conducted in a specific region of Turkey, may serve as a valuable reference both for its similar and novel aspects compared to the literature.

Joint hypermobility (JH) is simply an increase in joint range of motion, but the diagnosis of joint hypermobility syndrome (JHS) is based not only in the presence of joint and musculoskeletal system symptoms, but also systemic findings. JH is a prominent feature of hereditary connective tissue diseases associated with genetic alterations in collagen fibers, such as Marfan syndrome, hypermobile Ehlers-Danlos syndrome (EDS), previously known as EDS type 3, osteogenesis imperfecta, and JHS. As the cornea consists mostly of type I and Descemet's membrane of type IV collagen fibers, it is quite reasonable to suspect that people with JH may exhibit changes in corneal biomechanics. Considering that the prevalence of JH is reported as 5–30% in epidemiological studies, Bayramoğlu et al. must be congratulated for their prospective clinical study that dispels this well-founded suspicion.

The fact that topical medication causes ocular surface damage and/or discomfort in nearly half of all glaucoma patients is a global issue that has been demonstrated in large series. In comparisons of drops containing benzalkonium chloride (BAC) as a microbiological stabilizer and drops without this preservative, those containing BAC are always found to cause more discomfort. For these comparisons to be unbiased and straightforward, the BAC-containing and BAC-free drops must contain the same active substance. Although both BAC-containing and BAC-free preparations are used in Turkey, there is no pair with the same active ingredient. Therefore, our colleagues in Turkey who do not have access to BAC-preserved and BAC-free commercial forms of the same drug will be very interested in the study by Kumar et al. in which they determined that BAC-free travoprost drops provided better patient comfort according to the Ocular Surface Disease Index and the Glaucoma Quality of Life-15 questionnaires.

Inferior oblique muscle overaction (IOOA) is a common eye movement disorder involving excessive elevation of the adducted eye. The diplopia and upward deviation in IOOA are disturbing to the patient both functionally and cosmetically. Surgical treatment of IOOA is based on reducing muscle function. Z-myotomy, one of the surgical options in patients with IOOA, is a procedure in which the extraocular muscle is weakened by two incisions made in the extraocular muscle margins. Other surgical options include inferior oblique muscle recession, anteriorization, tenotomy, and myectomy. Kızıltoprak et al. demonstrate the effectiveness of Z-myotomy in patients with minimal IOOA, which may be encouraging and of practical interest for general ophthalmologists, whose career and professional practice are not focused on strabismus.

Retinopathy of prematurity (ROP) is a vexing condition for obstetricians, pediatricians, and ophthalmologists because examination is difficult and requires special experience in diagnosis and follow-up due to the unique circumstances of the patient group, and from the medicolegal side, has led to unprecedentedly high compensation in malpractice lawsuits in Turkey. A reliable parameter that enables early detection of ROP will offer a valuable opportunity to address these concerns. Akyüz-Ünsal et al. showed that a cut-off value of 34.43 pg for mean corpuscular hemoglobin (MCH), one of the complete blood count (CBC) parameters, was a statistically significant

TURKISH JOURNAL OF OPHTHALMOLOGY



www.ofthalmoloji.org

TJO

EDITORIAL

predictor of ROP. As this is a very inexpensive and accessible parameter, this finding must be taken into consideration for Social Insurance Institutions, physicians, and patients.

Different results have been reported regarding seasonal variations in the incidence of rhegmatogenous retinal detachments. Seasonal variations should be evaluated based on their position on the calendar together with the altitude and climate changes in the geographic region. Erdöl et al. screened an 8-year period of medical records from the East Black Sea Region of Turkey to analyze the annual distribution of rhegmatogenous retinal detachment in 281 eyes of 276 patients and showed that there was no significant seasonal variation. While adding this finding to the contradictory literature data on the seasonal occurrence of rhegmatogenous retinal detachment, it should be noted that the climate in this region is frequently rainy and relatively cool even in the summer and is at a fairly high altitude.

Optical coherence tomography (OCT) has proven itself to be an objective, reliable, and reproducible technology in the early diagnosis and follow-up in glaucoma as well as retinal diseases. Optical nerve head analysis and retinal nerve fiber layer thickness measurements can be obtained easily and noninvasively. However, errors, anatomical variations, and artifacts can occur during scanning in one-third of patients. As these anatomical variations and artifacts can lead to errors in diagnosis and treatment, the article from Bayer and Akman reviewing ways to prevent these problems is a reference source of information that every ophthalmologist should know.

The pine processionary caterpillar is an insect covered with tiny, fine hairs. These hairs can become airborne and land on the ocular surface, where eye rubbing causes them to become embedded in the tissue. When inflammation surrounding the hairs obscures them, it is difficult to determine the cause of the resulting clinical pictures. Diagnosis is based on a detailed history obtained in light of this knowledge and the detection of hairs in the ocular structures. Bayraktutar et al. aimed to raise our awareness of this entity with their report of a case

of ophthalmia nodosa that was initially misdiagnosed as fungal keratitis and later definitively diagnosed with *in vivo* confocal microscopy.

Koçak-Altıntaş et al. share in this issue an unusual association of inverse retinitis pigmentosa and scleromalacia with neovascular glaucoma in a patient who was treated with a single anterior chamber bevacizumab injection, along with high-quality anterior and posterior segment images.

Kayıcıoğlu et al. reported anterior chamber migration of Ozurdex (Allergan Inc. Irvine, CA, USA) dexamethasone implant in 6 eyes with history of complicated cataract surgery, 3 (50%) of which had permanent loss of corneal transparency and required corneal transplantation. With this 6-case series, the authors point out that in addition to indication for implantation, the presence of the lens capsule barrier is also important in the selection of the eyes to receive dexamethasone implants.

In this issue, Berrak Şekeryapan Gediz shares a case report documenting for the first time the coexistence of Purtscher retinopathy and acute macular neuroretinopathy in a patient with visual complaints after chest trauma. The study demonstrates that although this condition is difficult to diagnose clinically, characteristic findings on OCT and OCT-angiography facilitate the diagnosis, and the author emphasized that acute macular neuroretinopathy should be kept in mind when a patient presents with posttraumatic vision loss.

From the reliable evidence obtained through original research, to the awareness-raising presentations of rare or previously unreported, diagnostically challenging cases, to the review that should reduce the margin of error in OCT in the diagnosis and monitoring of glaucoma, we believe this issue will be of great benefit to our readers.

**Respectfully on behalf of the Editorial Board,
Sait Eğrilmez, MD**



The COVID-19 Pandemic: Clinical Information for Ophthalmologists

© Banu Bozkurt*, © Sait Eğrilmez**, © Tomris Şengör***, © Özlem Yıldırım****, © Murat İrkeç*****

*Selçuk University Faculty of Medicine, Department of Ophthalmology, Konya, Turkey

**Ege University Faculty of Medicine, Department of Ophthalmology, İzmir, Turkey (E)

***İstanbul Bilim University Faculty of Medicine, Department of Ophthalmology, İstanbul, Turkey (E)

****Mersin University Faculty of Medicine, Department of Ophthalmology, Mersin, Turkey

*****Hacettepe University Faculty of Medicine, Department of Ophthalmology, Ankara, Turkey (E)

Introduction

The coronavirus epidemic that started in China has rapidly spread to all countries of the world and caused a significant number of deaths. The situation was first reported to the World Health Organization (WHO) China office on December 31, 2019 as an outbreak of pneumonia of unknown cause in the city of Wuhan (population ~11 million) in the Hubei province.^{1,2,3,4} The disease was believed to have originated in a seafood market, which was closed for disinfection on January 1, 2020. Of 44 cases reported on January 3, 2020, 11 patients had severe disease while 33 patients were stable.^{2,3} On January 7, 2020, it was determined that the epidemic was caused by a novel coronavirus (nCoV). Thailand reported its first case on January 13 and Japan on January 15, while on January 20 the first case was reported in Korea and 6 were reported dead in the city of Wuhan. Later, it appeared in countries such as the United States, Vietnam, Singapore, and Australia, and spread to the European nations, starting with France on January 25, 2020. The WHO reported that the first cases in Wuhan had been infected via animals, after which the virus was transmitted from person to person and detected in clusters among families.³ On January 30, 2020, the epidemic was recognized as a public health emergency of international concern, and on February 11, 2020, the WHO named the novel coronavirus disease COVID-19.

The International Committee on Taxonomy of Viruses named the new virus SARS-CoV-2 (severe acute respiratory syndrome coronavirus 2) and the WHO declared the coronavirus epidemic a pandemic on March 12.⁴ On April 2, the WHO website reported 896,450 infected individuals worldwide, 206 affected countries, and 45,526 deaths globally.⁵

In Turkey, a Coronavirus Scientific Committee including academicians working in university departments such as infectious diseases, intensive care, pulmonology, emergency medicine, and public health was formed under the Ministry of Health on January 10, shortly after WHO announced the epidemic.⁶ Thermal cameras were installed in Turkish airports and additional scanning was implemented, especially for passengers arriving from China. As the epidemic spread to other countries, screening was expanded to include passengers from countries with reported cases, and any individuals showing signs of coronavirus infection were quarantined. In February, flights to all countries with growing outbreaks were suspended. In the first week of March, hand disinfectant stations were placed in mass transit and public areas in some provinces. The first case of COVID-19 in Turkey was announced by the Ministry of Health on March 10, 2020. Schools were closed on March 13 and some other precautions were implemented, such as not allowing spectators at sporting events and requiring special permission for government personnel to leave the country. The first COVID-

Address for Correspondence: Banu Bozkurt, Selçuk University Faculty of Medicine, Department of Ophthalmology, Konya, Turkey

E-mail: drbanubozkurt@yahoo.com **ORCID-ID:** orcid.org/0000-0002-9847-3521

Received: 13.04.2020 **Accepted:** 13.04.2020

Cite this article as : Bozkurt B, Eğrilmez S, Şengör T, Yıldırım Ö, İrkeç M. The COVID-19 Pandemic: Clinical Information for Ophthalmologists. Turk J Ophthalmol. 2020;50:59-63

©Copyright 2020 by Turkish Ophthalmological Association

Turkish Journal of Ophthalmology, published by Galenos Publishing House.

related death in Turkey occurred on March 15, 2020. As of March 19, all sports, scientific, cultural, and artistic activities have been postponed. Lockdown measures were later introduced, first for individuals over the age of 65, then for those under the age of 20. On April 1, it was reported that 601 healthcare workers were infected and 1 physician had died.⁶ As of April 2, there were 18,135 infected individuals and 356 deaths in Turkey.

The Causative Pathogen

Coronaviruses are enveloped, single-chain RNA viruses, and 4 types of human coronaviruses (HCoV-229E, -NL63, -OC43, and -HKU1) have been reported to cause upper respiratory infections and colds. Coronaviruses of animal origin (SARS-CoV 2002, MERS-CoV 2012, 2019-nCoV/SARS-CoV-2) can lead to fatal respiratory failure in humans.^{7,8,9} Coronaviruses bind to respiratory epithelial cells and enteric cells, causing cytopathic changes.

In this pandemic, bronchoalveolar lavage samples from a COVID-19 patient first tested positive for pan-betacoronavirus with real-time PCR (RT-PCR).³ Whole-genome sequencing of the virus was done by Illumina and nanopore sequencing, and bioinformatic analysis revealed that the virus carries the typical features of the coronavirus family and phylogenetically belongs to the 2B lineage of betacoronaviruses. When the COVID-19 virus and other betacoronavirus genome sequences were compared, it was found that the novel coronavirus shows 96% similarity to the bat SARS-like coronavirus strain BatCovRaTG13 and that the spike (S) protein on the virus binds to angiotensin-converting enzyme 2 (ACE2) on the cell surface.^{3,4,9,10,11}

Clinical Symptoms

Although COVID-19 is largely asymptomatic or mild (80%), it can sometimes lead to severe pneumonia and death.^{12,13} It is generally more severe in individuals over 60 years of age and those with comorbid diseases such as hypertension, cardiovascular disease, chronic lung disease, and cancer. It is less common and milder in children. The incubation period is 1-14 days (mean 5-6 days) and the classic signs and symptoms reported include high fever, dry cough, shortness of breath, muscle pain, and fatigue, with bilateral ground-glass opacity on chest tomography.^{12,13} The presence of conjunctivitis has not been reported in these studies. An article published in the *New England Journal of Medicine* in late February evaluated the clinical symptoms and outcomes of 1,099 of the 7,736 patients who were hospitalized due to a diagnosis of COVID-19 in 552 hospitals in China through January 29, 2020.¹⁴ The median age of the patients was 47 years; 41.9% were female, and the incubation period was 4 days. Only 0.9% of patients were under the age of 15, while 23.7% had a comorbidity such as hypertension or chronic obstructive pulmonary disease. The most common symptom was fever (88.7%), followed by cough (67.8%). Nausea, vomiting, and diarrhea were rarely observed. Lymphocytopenia was present in 83.2% and ground-glass opacities were observed on lung tomography in 56.4% of

patients. Five percent of the patients were admitted to intensive care units, 2.3% required mechanical ventilation, and 1.4% died. Conjunctival congestion was detected in 9 (0.8%) of the patients.¹⁴

Diagnosis

COVID-19 is diagnosed based on detection of genetic material from the virus by molecular microbiological methods in a patient specimen. Nasopharyngeal or saliva samples obtained from suspected patients with high fever, travel history, and contact with infected patients, as well as the close contacts of these suspected patients, are tested using specific RT-PCR kits for 2019-nCoV to detect RdRp and the variable S gene.¹⁵ In addition, serum IgM and IgG are also analyzed to identify active or recovered cases.

Transmission

Transmission of COVID-19 is known to mostly occur to individuals in close contact with symptomatic patients via airborne microdroplets, and through direct contact with infected individuals or contaminated objects.^{16,17} Social isolation and personal protection are extremely important for preventing spread. Virus-laden microdroplets released into the environment by sneezing, coughing, and exhaling can come into contact with the mouth, nasal mucosa, and conjunctiva. For this reason, the WHO states that healthcare workers who are in contact with a suspected COVID-19 patient must protect their eyes, mouth, and nose with goggles, masks, filtering masks (N95, FFP2, FFP3), and face shield.¹⁶

SARS-CoV-2 and Ocular Involvement

Transmission of the novel coronavirus through ocular fluids is a cause of serious concern for ophthalmologists. On January 22, Guangfa Wang, a physician specializing in pneumonia, developed conjunctivitis while visiting Wuhan for inspection. He later tested positive for SARS-CoV-2 and suggested that ocular infection was an alternative route of transmission of the virus.¹⁸ Li Wenliang, an ophthalmologist working in Wuhan, contracted the disease in early January after contact with a glaucoma patient and later lost his life.¹⁹ A report published in *The Lancet* in February 2020 and an editorial published in the *British Journal of Ophthalmology* in March stated that, in light of previous publications regarding coronavirus and SARS, the ocular surface is a potential target tissue for SARS-CoV-2 invasion.^{20,21} Certain coronaviruses are known to cause conjunctivitis in humans.^{22,23} Of the human coronaviruses, NL 63 (HCoV-NL63) was first isolated in an infant with bronchiolitis and conjunctivitis,²² and a later publication reported that conjunctivitis was present in 17% (n=3) of 18 children with respiratory infection whose nasal swabs had tested positive for HCoV-NL63.²³

Loon et al.²⁴ published a study in Singapore in which they collected tear samples from 36 patients followed for 12 days for suspected SARS and analyzed them using PCR. Eight of these patients were later serologically diagnosed with SARS, while

tear samples of 3 patients (37.5%) tested positive by PCR. Tear test results were negative in the remaining suspected cases. It was reported that in all patients with positive tear PCR results, the samples had been collected at an early stage. The authors stated that collecting a tear sample is extremely simple and reproducible and that it can therefore be used for diagnostic purposes in the early stage. They noted that ophthalmologists and other healthcare professionals work within close proximity to patients' eyes and that this may be a source of infection, citing Goldmann applanation tonometry, contact lens fitting, and spectacle frames as potential transmitters of infection. They also stated that for this reason, healthcare workers' compliance with personal protective equipment guidelines (M3G: mask, gown, gloves, and goggles/face shield) is imperative during the examination and treatment of SARS patients.²⁴ The debate still continues regarding how the SARS-CoV is found in tears.⁹ Mechanisms discussed include transmission through droplets, upstream passage from an upper respiratory tract infection through the nasolacrimal duct, and from hematogenous infection of the lacrimal gland.

In a study published by Chan et al.²⁵ in the same year (2004), nasopharyngeal, stool, tear, and conjunctival swab samples were collected from 20 SARS patients, 17 of whom were confirmed cases. The nasopharyngeal swab and stool samples of 5 (29.4%) of the 17 patients tested positive for SARS-CoV when tested by PCR, while SARS-CoV could not be detected with RT-PCR or viral culturing in any of the tear/conjunctival swabs. Several possible explanations for the negative test results were suggested. The results may have been false-negatives, and collecting more samples could improve sensitivity, or the virus and its genetic material may be detectable in tears only in a short window during the disease, or the virus is not present in tears. The authors concluded that checking for the virus in tears or conjunctival swabs had no place in disease screening.²⁴

Being a relatively new entity, there are extremely few studies on COVID-19. In a study conducted in China, Xia et al.²⁶ collected tears, conjunctival swab, and saliva samples twice from 30 COVID-19 patients. Only the 2 samples from a patient with conjunctivitis tested positive in RT-PCR, while the other 58 tear samples tested negative. The patient with conjunctivitis was reported to have conjunctival congestion and serous discharge; however, the virus could not be isolated. Of the 60 saliva samples, 55 yielded positive results. The authors stated that even though the chance of virus being present in tear and conjunctiva samples is low, this does not mean that the conjunctiva cannot act as a portal of entry for the virus. Because ophthalmologists are within close range of patients during examination, the patient's saliva may splash on the face and cause infection, making the use of safety goggles an absolute necessity.

Finally, according to an article by Jun et al.²⁷ published in the journal *Ophthalmology* last week, viral culture and RT-PCR analysis of 64 tear samples collected simultaneously with nasopharyngeal swabs from 17 COVID-19 patients between 3 and 20 days after initial symptom onset failed to demonstrate the presence of 2019-CoV. Ocular symptoms were not observed in

any of the patients, but 1 patient developed conjunctival redness and chemosis while in hospital. Although these results may seem comforting, they have led to arguments that the negative results could be attributed to the absence of active conjunctivitis at time of sample collection, the small number of conjunctiva and tear samples, and the fact that the samples were collected 2 to 3 weeks after symptom onset, when there is lower virus load.²⁸

According to another argument, as SARS-CoV-2 enters cells by binding with S proteins to ACE2 in the respiratory and pulmonary epithelia, and because ACE2 is not expressed in the conjunctival or corneal epithelium²⁹ but is expressed only in the retinal and retinal pigment epithelium, this virus may enter the tears through droplets and then be transferred to the respiratory tract through the nasolacrimal canal, and the use of safety goggles by healthcare professionals is therefore recommended.³⁰

Considerations for Ophthalmologists During the COVID-19 Pandemic

Seitzman and Doan²⁸ stated that the healthcare industry accounts for 11% of professional groups in the US and that occupational exposure to the virus occurs mostly by transmission through infected airborne droplets. They noted that the risk of exposure to this infection is much higher during slit-lamp examination and other ophthalmologic imaging measurements where there is closer face-to-face contact, because the virus load is especially high in the nasal cavity. As SARS-CoV-2 can survive in air for at least 3 hours,³¹ they recommend not talking during slit-lamp examination and keeping the examination as brief as possible.

In the American Academy of Ophthalmology (AAO) guidelines³² and a review by Lai et al.¹⁹ sharing their experiences regarding infection control in ophthalmology practice during the COVID-19 pandemic, it is recommended that patient examination only be conducted in emergency circumstances and that patients always be screened for SARS-CoV-2 prior to ophthalmic examination (FTOCC: fever or symptoms of respiratory tract infection; recent travel history; occupation [healthcare professional], contact with an individual who has COVID-19, and presence of certain symptoms in the family [cluster]). It is also advised to postpone appointments at least 14 days for individuals suspected of having COVID-19 and to regard patients with conjunctivitis as contagious carriers.

The following guidelines were specified for performing ophthalmic examination in emergencies:^{19,28,32}

- Patient numbers should be reduced; patients should be informed by message or phone call not to come to the office except for emergencies.
- Prescriptions and reports should be approved without an office visit.
- For patients who absolutely must come in, examination times should be defined within a schedule.
- Care should be taken to maintain appropriate social distance in examination rooms.
- Examination of patients with suspected COVID-19 should be conducted in a separate, dedicated room.

- Examination devices and any other surfaces in the room touched by hand should be cleaned with 0.1% sodium hypochlorite or 70% ethanol for at least 1 minute before and after a patient examination. Commercially available bleach contains 5% sodium hypochlorite.
- Patients should wear a face mask.
- Hands should be washed frequently with soap and water.
- Ophthalmologists should always wear an N95 mask and safety goggles or face shield during examination and gloves should be changed between patients.
- Healthcare workers should be checked for fever and any symptoms should be reported immediately.
- Visual acuity should be assessed from a distance.
- Shields acting as a barrier between patient and physician should be placed on biomicroscopes and disinfected between exams.
- Clinical examination should be diagnostic and brief.
- Air-puff tonometers should not be used because they are a potential source of microaerosols. Intraocular pressure should be measured using tonometers with disposable tips. If Goldmann tonometry is used, tips should be disinfected before and after each patient.³³
- All non-urgent elective surgeries, procedures (e.g., contact lens fitting), and testing (e.g., electrodiagnostic testing) should be postponed to a later date.
- Imaging should be done only if essential for diagnosis and will influence treatment.
- When necessary, emergency surgery should be performed under local anesthesia if possible, and a COVID-19 test should be performed if the patient has fever or other suspicious symptoms.
- It should be remembered during this period that conjunctivitis can also be caused by viruses other than 2019-nCoV.

Is Eye Examination Necessary When Using Chloroquine/Hydroxychloroquine?

Chloroquine and hydroxychloroquine are drugs shown to be effective against the SARS virus, and approximately 10 clinical trials are underway in the current pandemic.^{34,35} In China, patients are treated with 500 mg of chloroquine twice daily or 400 mg of hydroxychloroquine 4 times a day for 10 days. Chloroquine and hydroxychloroquine are well-known drugs among ophthalmologists as they cause retinal toxicity with long-term use for the treatment of rheumatoid diseases. The AAO guidelines state that the risk of developing retinopathy within 10 years is extremely low if used at doses less than 5 mg/kg/day.³⁶ In a study including 22 patients in France, COVID-19 positive patients were given 600 mg of hydroxychloroquine per day for 10 days and it was observed that virus load decreased by 50% when used alone and by up to 100% when used in combination with azithromycin.³⁷ Although the dose cited by the Chinese group is much higher than the dose used in rheumatoid patients, they reported that short-term use (less than 2 weeks) will not cause any toxicity and that conducting detailed eye exams before and after this treatment during the pandemic is unnecessary.³⁴

The Turkish Ministry of Health, in a guidance report entitled "Evaluation of Healthcare Workers with Patient Contact" published on March 25, 2020, identified ophthalmologic examination as a procedure requiring intensive contact, and recommended prophylaxis with hydroxychloroquine for a total of 3 days (400 mg twice on day 1, 200 mg twice daily on days 2 and 3) and 5 days of home isolation followed by a PCR test in the event of high-risk contact with COVID-19 patients without the use of personal protective equipment.³⁸ The Turkish Society of Clinical Microbiology and Infectious Diseases reported, based on available data, that these agents should only be used by some symptomatic COVID-19 patients, that they should be initiated early, and should not be used for prophylaxis.³⁹ Treatment algorithms from the Ministry of Health recommend hydroxychloroquine for adults with uncomplicated probable/confirmed COVID-19, with oseltamivir if influenza is suspected; hydroxychloroquine and azithromycin for adults with indication for hospitalization; and hydroxychloroquine, azithromycin, and favipiravir for adults with COVID pneumonia.⁴⁰

Treatment with lopinavir/ritonavir is recommended for pregnant women. For children, the first-line treatment options are oseltamivir, hydroxychloroquine, and azithromycin.⁴¹ In case of progression, lopinavir/ritonavir therapy can be initiated.

In summary, close-proximity examination procedures and those requiring physical contact pose a high risk for the transmission of SARS-CoV-2 to ophthalmologists. Therefore, examination procedures such as ophthalmoscopy, biomicroscopy, and manifest refraction should not be performed without personal protective equipment. Disinfection of devices and instruments should be made a routine part of examination for all procedures that require contact with the ocular surface. All surfaces touched both inside and outside the office by patients during their visits, including the examination room and outside surfaces such as the handle of the entrance door, doorbell, and elevator buttons, require regular disinfection. Therefore, the number of patients should be reduced except for urgent cases that cannot be postponed. It is extremely important to educate patients in order to prevent infection via the ocular surface. Patients should be advised to stop rubbing their eyes habitually and to avoid all hand contact with the eyes before washing appropriately. Hygiene rules should be adhered to strictly, especially when using contact lenses, and the use of eyeglasses should be recommended instead if necessary.

Authorship Contributions

Concept: B.B., M.İ., Design: B.B., M.İ., Literature Search: B.B., S.E., T.Ş., Ö.Y., M.İ., Writing: B.B., S.E., T.Ş., Ö.Y., M.İ.

Conflict of Interest: No conflict of interest was declared by the authors.

Financial Disclosure: The authors declared that this study received no financial support.

References

1. Zhu N, Zhang D, Wang W, Li X, Yang B, Song J, Zhao X, Huang B, Shi W, Lu R, Niu P, Zhan F. A novel coronavirus from patients with pneumonia in China, 2019. *N Engl J Med.* 2020; 382:727-733.

2. WHO Novel Coronavirus (2019-nCoV) situation report-1. 21 January 2020. https://www.who.int/docs/default-source/coronaviruse/situation-reports/20200121-sitrep-1-2019-ncov.pdf?sfvrsn=20a99c10_4
3. Report of the WHO-China Joint Mission on Coronavirus Disease 2019 (COVID-19) <https://www.who.int/docs/default-source/coronaviruse/who-china-joint-mission-on-covid-19-final-report.pdf>
4. World Health Organization. Origin of SARS-CoV-2 (26 March 2020) <https://www.who.int/health-topics/coronavirus/who-recommendations-to-reduce-risk-of-transmission-of-emerging-pathogens-from-animals-to-humans-in-live-animal-markets>
5. Coronavirus disease (COVID-2019) situation reports. https://www.who.int/docs/default-source/coronaviruse/situation-reports/20200402-sitrep-73-covid-19.pdf?sfvrsn=5ae25bc7_2
6. Türkiye'de 2020 koronavirüs pandemisi. https://tr.wikipedia.org/wiki/T%C3%BCrkiye'de_2020_koronavir%C3%BCs_pandemisi#cite_note-1Nisan-59
7. Habibzadeh P, Stoneman EK. The Novel Coronavirus: A Bird's Eye View. *Int J Occup Environ Med.* 2020;11:65-71.
8. Su S, Wong G, Shi W, et al. Epidemiology, genetic recombination, and pathogenesis of coronaviruses. *Trends Microbiol.* 2016;24:490-502.
9. Seah I, Agrawal R. Can the Coronavirus Disease 2019 (COVID-19) Affect the Eyes? A Review of Coronaviruses and Ocular Implications in Humans and Animals. *Ocul Immunol Inflamm.* 2020;16:1-5.
10. Chan JF, Kok KH, Zhu Z, Chu H, To KK, Yuan S, Yuen KY. Genomic characterization of the 2019 novel human-pathogenic coronavirus isolated from a patient with atypical pneumonia after visiting Wuhan. *Emerg Microbes Infect.* 2020;9:221-236.
11. Lu R, Zhao X, Li J, Niu P, et al. Genomic characterisation and epidemiology of 2019 novel coronavirus: implications for virus origins and receptor binding. *Lancet.* 2020;22:395:565-574.
12. Huang C, Wang Y, Li X, et al. Clinical features of patients infected with 2019 novel coronavirus in Wuhan, China. *Lancet.* 2020;395:497-506.
13. Chen NS, Zhou M, Dong X, Qu J, Gong F, Han Y, Qiu Y, Wang J, Liu Y, Wei Y, Xia J, Yu T, Zhang X, Zhang L. Epidemiological and clinical characteristics of 99 cases of 2019 novel coronavirus pneumonia in Wuhan, China: a descriptive study. *Lancet.* 2020;15:395:507-513.
14. Guan WJ, Ni ZY, Hu Y, Liang WH, Ou CQ, He JX, Liu L, Shan H, Lei CL, Hui DSC, Du B, Li LJ, Zeng G, Yuen KY, Chen RC, Tang CL, Wang T, Chen PY, Xiang J, Li SY, Wang JL, Liang ZJ, Peng YX, Wei L, Liu Y, Hu YH, Peng P, Wang JM, Liu JY, Chen Z, Li G, Zheng ZJ, Qiu SQ, Luo J, Ye CJ, Zhu SY, Zhong NS. China Medical Treatment Expert Group for Covid-19. Clinical Characteristics of Coronavirus Disease 2019 in China. *N Engl J Med.* 2020 Feb 28.
15. Laboratory testing of 2019 novel coronavirus (2019-nCoV) in suspected human cases: interim guidance, 17 January 2020. <https://apps.who.int/iris/bitstream/handle/10665/330676/9789240000971-eng.pdf?sequence=1&isAllowed=y>
16. World Health Organization. Infection prevention and control during health care when novel coronavirus (nCoV) infection is suspected. Interim guidance, 2020 [https://www.who.int/publications-detail/infection-prevention-and-control-during-health-care-when-novel-coronavirus-\(ncov\)-infection-is-suspected-20200125](https://www.who.int/publications-detail/infection-prevention-and-control-during-health-care-when-novel-coronavirus-(ncov)-infection-is-suspected-20200125)
17. She J, Jiang J, Ye L, Hu L, Bai C, Song Y. 2019 novel coronavirus of pneumonia in Wuhan, China: emerging attack and management strategies. *Clin Transl Med.* 2020;20:9:19.
18. Yan A. Chinese expert who came down with Wuhan coronavirus after saying it was controllable thinks he was infected through his eyes China: South China morning post. <https://www.scmp.com/news/china/article/3047394/chinese-expert-who-came-down-wuhan-coronavirus-after-saying-it-was-2020>.
19. Lai THT, Tang EWH, Chau SKY, Fung KSC, Li KKW. Stepping up infection control measures in ophthalmology during the novel coronavirus outbreak: an experience from Hong Kong. *Graefes Arch Clin Exp Ophthalmol.* 2020 Mar 3. doi:10.1007/s00417-020-04641-8.
20. Lu CW, Liu XF & Jia ZF. 2019-nCoV transmission through the ocular surface must not be ignored. *Lancet.* 2020;395:e39.
21. Li JO, Lam DSC, Chen Y, Ting DSW. Novel Coronavirus disease 2019 (COVID-19): The importance of recognising possible early ocular manifestation and using protective eyewear. *Br J Ophthalmol.* 2020;104:297-298.
22. van der Hoek L, Pyrc K, Jebbink ME, Vermeulen-Oost W, Berkhout RJ, Wolthers KC, Wertheim-van Dillen PM, Kaandorp J, Spaargaren J, Berkhout B. Identification of a new human coronavirus. *Nat Med.* 2004;10:368-373.
23. Vabret A, Mourez T, Dina J, van der Hoek L, Gouarin S, Petitjean J, Brouard J, Freymuth F. Human coronavirus NL63, France. *Emerg Infect Dis.* 2005;11:1225-1229.
24. Loon S-C, Teoh SCB, Oon LLE, Se-Thoe SY, Ling AE, Leo YS, Leong HN. The severe acute respiratory syndrome coronavirus in tears. *Br J Ophthalmol.* 2004;88:861-863.
25. Chan WM, Yuen KS, Fan DS, Lam DS, Chan PK, Sung JJ. Tears and conjunctival scrapings for coronavirus in patients with SARS. *Br J Ophthalmol.* 2004;88:968-969.
26. Xia J, Tong J, Liu M, Shen Y, Guo D. Evaluation of coronavirus in tears and conjunctival secretions of patients with SARS-CoV-2 infection. *J Med Virol.* 2020 Feb 26. doi: 10.1002/jmv.25725.
27. Jun ISY, Anderson DE, Kang AEZ, et al. Assessing Viral Shedding and Infectivity of Tears in Coronavirus Disease 2019 (COVID-19) Patients. *Ophthalmology* 2020 in Press. <https://doi.org/10.1016/j.ophtha.2020.03.026>
28. Seitzman GD, Doan T. No time for tears. *Ophthalmology* 2020, doi: <https://doi.org/10.1016/j.ophtha.2020.03.030>
29. Choudhary R, Kapoor MS, Singh A & Bodakhe SH (2017): Therapeutic targets of renin-angiotensin system in ocular disorders. *J Curr Ophthalmol.* 2017;29:7-16.
30. Qing H, Li Z, Yang Z, Shi M, Huang Z, Song J, Song Z. The possibility of COVID-19 transmission from eye to nose. *Acta Ophthalmol.* 2020 Mar 18. doi: 10.1111/aos.14412.
31. van Doremalen N, Bushmaker T, Morris DH, et al. Aerosol and Surface Stability of SARS-CoV-2 as Compared with SARS-CoV-1. *New England Journal of Medicine.* 2020.
32. American Academy of Ophthalmology. Alert: Important coronavirus updates for ophthalmologists. <https://www.aaao.org/headline/alert-important-coronavirus-context>
33. Junk AK, Chen PP, Lin SC, Nouri-Mahdavi K, Radhakrishnan S, Singh K, Chen TC. "Disinfection of Tonometers: A Report By the American Academy of Ophthalmology." *Ophthalmology.* 2017;124:1867-1875.
34. Marmor MF. COVID-19 and Chloroquine/Hydroxychloroquine: Is There Ophthalmological Concern? *AJOPHTH*11279_proof, 24 March 2020
35. Devaux CA, Rolain J-M, Colson P, Raoult D. New insights on the antiviral effects of chloroquine against coronavirus: what to expect for COVID-19? *Int J Antimicrob Agents* 2020;11:105938.
36. Marmor M, Kellner U, Lai TY, Melles RB, Mieler WF. Recommendations on screening for chloroquine and hydroxychloroquine retinopathy (2016 revision). *Ophthalmology.* 2016;123:1386-1394.
37. Gautret P, Lagier J-C, Parola P, Hoang VT, Meddeb L, Mailhe M, Doudier B, Courjon J, Giordanengo V, Vieira VE, Dupont HT, Honoré S, Colson P, Chabrière E, La Scola B, Rolain JM, Brouqui P, Raoult D. Hydroxychloroquine and azithromycin as a treatment of COVID-19: results of an open-label non-randomized clinical trial. *Int J Antimicrob Agents.* 2020;20:105949.
38. COVID-19. Teması olan Sağlık Çalışanlarının Değerlendirilmesi. <https://ohsad.org/wp-content/uploads/2020/03/COVID19-TemasiOlanSaglikCalisanlarininDegerlendirilmesi-25032020.pdf.pdf>
39. Türk Klinik Mikrobiyoloji ve İnfeksiyon Hastalıkları Derneği. Klorokin ve Hidroksiklorokin COVID-19 Hastalarında ve Hastalığın Profilaksisinde Kullanımı Konusunda KLİMİK Derneği Görüşü. 21 Mart 2020 [Erişim Tarihi: 22 Mart 2020]. <https://www.klimik.org.tr/koronavirus/klorokin-ve-hidroksiklorokin-covid-19-hastalarinda-ve-hastaligin-profilaksisinde-kullanimi-konusunda-klimik-dernegi-gorusu/>
40. COVID-19 Erişkin Hasta Tedavisi. https://covid19bilgi.saglik.gov.tr/depo/tedavi/COVID19_Eriskin_Hasta_Tedavisi_02042020.pdf
41. COVID-19 Çocuk Hasta Yönetimi ve Tedavisi. https://covid19bilgi.saglik.gov.tr/depo/tedavi/COVID19_Cocuk_Hasta_Yonetimi_ve_Tedavisi.pdf



Investigation of TGFBI (transforming growth factor beta-induced) Gene Mutations in Families with Granular Corneal Dystrophy Type 1 in the Konya Region

© Fatma Malkondu*, © Hilal Arıkoğlu*, © Dudu Erkoç Kaya*, © Banu Bozkurt**, © Fehmi Özkan***

*Selçuk University Faculty of Medicine, Department of Medical Biology, Konya, Turkey

**Selçuk University Faculty of Medicine, Department of Ophthalmology, Konya, Turkey

***Konya Numune Hospital, Clinic of Ophthalmology, Konya, Turkey

Abstract

Objectives: Granular corneal dystrophies (GCD) are characterized by small, discrete, sharp-edged, grayish-white opacities in the corneal stroma. Among the genes responsible for the development of GCD, the most strongly related gene is transforming growth factor beta-induced (*TGFBI*), located in the 5q31.1 locus. Studies show that R124H in exon 4 and R555W in exon 12 are hot-spot mutations in the *TGFBI* gene that lead to GCD development. In this study, we aimed to investigate these two hot-spot mutations in exons 4 and 12 of the *TGFBI* gene and other possible mutations in the same regions, which code important functional regions of the protein, in Turkish families with GCD and to determine the relationship between the mutations and disease and related phenotypes.

Materials and Methods: The study included 16 individuals diagnosed with GCD type 1 (GCD1), 11 of these patients' healthy relatives, and 28 unrelated healthy individuals. DNA was obtained from peripheral blood samples taken from each individual and polymerase chain reaction was used to amplify target gene regions. Genotyping studies were done by sequence analysis.

Results: The R124S mutation in exon 4 of *TGFBI* was not detected in the patients or healthy individuals in our study. However, all individuals diagnosed as having GCD1 were found to be heterozygous carriers of the R555W mutation in exon 12 of *TGFBI*. This mutation was not detected in healthy family members or control individuals unrelated to these families. In addition, we detected the silent mutation F540F in exon 12 and c.32924 G>A substitution in an intronic region of the gene in a few patients and healthy individuals.

Conclusion: Our study strongly supports the association of GCD1 with R555W mutation in exon 12 region of the *TGFBI* gene, as reported in the literature.

Keywords: Granular corneal dystrophy type 1, *TGFBI* gene, R555W mutation

Introduction

Corneal dystrophy is a group of progressive, often bilateral, usually inherited diseases characterized by non-inflammatory opacification.¹ The diagnosis and classification of corneal

dystrophies is based on corneal findings observed on slit-lamp biomicroscopic examination. Classification is based on clinical, pathological, and genetic features (IC3D) (Table 1).² According to this classification, 5q31-linked corneal dystrophies are often caused by mutations occurring in the transforming

Address for Correspondence: Hilal Arıkoğlu, Selçuk University Faculty of Medicine, Department of Medical Biology, Konya, Turkey
Phone: +90 532 706 07 14 E-mail: berktug200@hotmail.com **ORCID-ID:** orcid.org/0000-0002-6600-6603

Received: 07.06.2019 **Accepted:** 25.12.2019

Cite this article as: Malkondu F, Arıkoğlu H, Erkoç Kaya D, Bozkurt B, Özkan F. Investigation of TGFBI (transforming growth factor beta-induced) Gene Mutations in Families with Granular Corneal Dystrophy Type 1 in the Konya Region. Turk J Ophthalmol. 2020;50:64-70

©Copyright 2020 by Turkish Ophthalmological Association
Turkish Journal of Ophthalmology, published by Galenos Publishing House.

growth factor β -induced (*TGFBI*) gene.¹ Different mutations in *TGFBI*, which is located in the *5q31* gene locus, lead to granular corneal dystrophy types 1 and 2 (GCD1 and 2), Reis-Bückler corneal dystrophy, lattice corneal dystrophy (LCD), and Thiel-Behnke corneal dystrophy.³ GCD1, a member of the corneal stromal dystrophy group, is a slow-progressing, mostly asymptomatic autosomal dominant dystrophy that usually appears in childhood. The corneal opacities are small, discrete, sharp-edged, gray-white, and located in the central stroma, while the peripheral cornea is clear. Although there is no visual impairment in the early stage, the deposits on the stroma layer merge and reduce vision as the disease progresses.⁴

The *TGFBI* protein encoded by the *TGFBI* gene is produced mainly by the epithelium and partly by stromal fibroblasts called keratocytes, and is transported to the stroma.^{5,6} The stroma, which comprises about 90% of the cornea, has a rich matrix and special importance both structurally and functionally. The lamellar structure, arranged in a hexagonal pattern of type I and type V heterotrimeric collagen fibrils in the stroma matrix, is essential for the cornea to remain transparent.⁷ Along with

collagen types VI, XII, and XIV, the proteoglycans decorin, lumican, keratocan, mimecan, biglycan, and fibromodulin provide structural support for the assembly and positioning of collagen fibrils.⁸ The *TGFBI* protein, a matricellular protein, establishes and maintains matrix organization by binding to integrin via FAS1 domains containing the arginine-glycine-aspartic acid (RGD) sequence, the integrin-binding motif in matrix elements. The *TGFBI* protein includes a signal peptide sequence (Met1-Ala23), cysteine-rich EMI domain (Gly45-Ala99), 4 FAS1 domains (Ala100-Pro635) containing 140 amino acids each, and the RGD motif at the C-terminal.^{9,10}

To date, more than 50 mutations identified in the *TGFBI* gene have been associated with corneal dystrophies and these mutations have mostly been identified in the codon Arg124 in the first FAS1 domain or in the codon Arg555 in the fourth FAS1 domain.¹¹ GCD1 has most frequently been associated with a missense mutation in the CG dinucleotide in codon 555 of *TGFBI* that causes the substitution of arginine (Arg/R) to tryptophan (Trp/W).¹² In this study, individuals diagnosed with GCD1 and their families were evaluated using DNA sequence analysis for the presence of the two hot-spot mutations mentioned in the literature and other mutations in the exon 4 and exon 12 regions, which encode the functionally important first and fourth FAS1 domains of the *TGFBI* protein, respectively.

Materials and Methods

Patient and Control Groups

Approval for the study was obtained from the Selçuk University Faculty of Medicine Ethics Committee (2017/193). All subjects were informed and their consent was obtained prior to their participation in the study. Three individuals who presented to and were diagnosed with GCD1 in the ophthalmology department of Selçuk University Faculty of Medicine and their families were included in the study. Four-generation family trees of these 3 GCD1 patients were created (Figures 1, 2, 3). The history of each patient with regard to age, signs and symptoms, disease progression, genetic diseases, and medications used was recorded. Relatives of the patients

Table 1. Classification of corneal dystrophies²
1. Epithelial and subepithelial dystrophies
a. Epithelial basal membrane dystrophy (EBMD) C1
b. Epithelial recurrent erosion dystrophy (ERED) C4
c. Subepithelial mucinous corneal dystrophy (SMCD) C4
d. Mutation in keratin genes: Meesmann corneal dystrophy (MECD) C1
e. Lisch epithelial corneal dystrophy (LECD) C2
f. Gelatinous drop-like corneal dystrophy (GDLD) C1
2. Bowman layer dystrophies
a. Reis-Bücklers corneal dystrophy (RBCD) C1
b. Thiel-Behnke corneal dystrophy (TBCD) C1
c. Grayson-Wilbrandt corneal dystrophy (GWCD) C4
3. Stromal dystrophies
a. <i>TGFBI</i> corneal dystrophies
* Lattice corneal dystrophy, granular corneal dystrophy
b. Macular corneal dystrophy (MCD) C1
c. Schnyder corneal dystrophy (SCD) C1
d. Congenital stromal corneal dystrophy (CSCD) C1
e. Fleck corneal dystrophy (FCD) C1
f. Posterior amorphous corneal dystrophy (PACD) C3
g. Central cloudy dystrophy of François (CCDF) C4
h. Pre-Descemet corneal dystrophy (PDCD) C4
4. Descemet membrane and endothelial dystrophies
a. Fuchs endothelial corneal dystrophy (FECD) C1, C2, or C3
b. Posterior polymorphous corneal dystrophy (PPCD) C1 or C2
c. Congenital hereditary endothelial dystrophy 1 (CHED1) C2
d. Congenital hereditary endothelial dystrophy 2 (CHED2) C1
e. X-linked endothelial corneal dystrophy (XECD) C2
<i>TGFBI</i> : Transforming growth factor β -induced

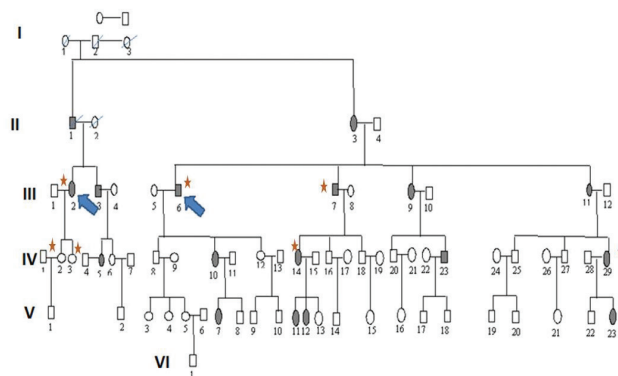


Figure 1. Family tree of family 1. Shaded symbols indicate individuals diagnosed with granular corneal dystrophy type 1 (GCD1), the arrow indicates the proband, and members included in the study are indicated with stars

underwent complete ophthalmological examination with assessment of uncorrected and corrected visual acuity. In slit-lamp biomicroscopic examination, the density and location of corneal deposits were examined and anterior segment photographs were taken (Figure 4). The properties and depths of the deposits were evaluated on anterior segment optical coherence tomography (OCT) and a detailed *in vivo* examination of the cornea at the cellular level was performed with confocal microscopy. Sixteen of the evaluated family members were diagnosed with GCD1, while no disease was detected in 11. In addition, 28 individuals who were unrelated to these families or with one another and had normal ophthalmic examination findings were included in

the study as the control group. Peripheral blood samples of 6 cc were collected from each participant into EDTA tubes for DNA extraction.

Determination of Target Gene Regions and Primer Design

The nucleotide sequences of the *TGFBI* gene were obtained from the National Center for Biotechnology Information (NCBI) GenBank™ with access number NM_000358. We planned to use primers designed to include the entirety of the exon 4 and exon 12 regions of the *TGFBI* gene, shown in the literature to be particularly associated with the disease, and therefore we used appropriate primers reported in the literature (Table 2).

Polymerase Chain Reaction (PCR) Procedure

Gradient PCR was used to determine the appropriate melting temperature for the 2 pairs of primers to be used in the study. Samples were amplified using the temperatures determined for each primer pair in gradient PCR. PCR was conducted in 30-µL reaction volumes containing 1X PCR buffer, 0.4 mM primer, 0.6 mM deoxyribonucleotide triphosphate, 0.1 unit Taq polymerase, and 100 ng DNA. PCR conditions were as follows: initial denaturation at 94 °C for 5 min, followed by 35 cycles of denaturation at 94 °C for 30 s, primer annealing for 45 s at the temperature determined by gradient PCR for each primer, and elongation at 72 °C for 45 s, with a final elongation at 72 °C for 2 min. PCR results were evaluated in 1% agarose gel electrophoresis and photographed.

DNA Sequence Analysis

Sequence analysis was performed on the target DNA regions amplified with PCR. The sequences were visualized as chromatograms in the FinchTV software and matched with sequences in the) GenBank™ using the NCBI BLAST program from (<https://www.ncbi.nlm.nih.gov/gene>). The BLAST results and chromatograms were carefully compared to evaluate changes in the sequences. Two-way sequence analysis was performed to prevent potential errors in DNA sequence analysis. Thus, mutations were identified in both directions for a highly reliable evaluation.

Results

According to sequence analysis results for the exon 12 region of the *TGFBI* gene, all patients diagnosed with GCD1 were heterozygous carriers of the hot-spot Arg555Trp (c.1663C>T) mutation (Figures 5a). This mutation was not detected in healthy

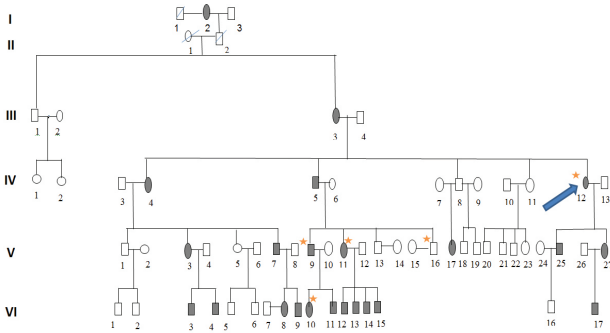


Figure 2. Family tree of family 2. Shaded symbols indicate individuals diagnosed with granular corneal dystrophy type 1 (GCD1), the arrow indicates the proband, and members included in the study are indicated with stars

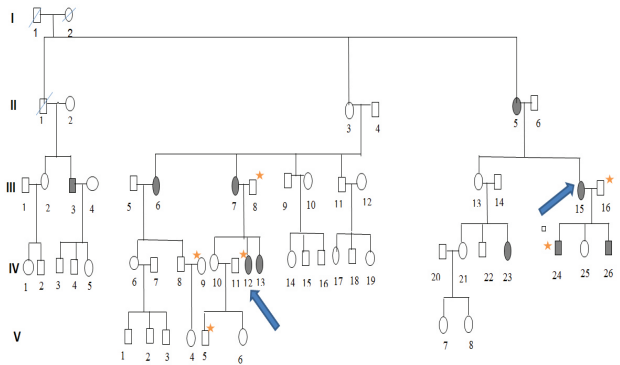


Figure 3. Family tree of family 3. Shaded symbols indicate individuals diagnosed with granular corneal dystrophy type 1 (GCD1), the arrow indicates the proband, and members included in the study are indicated with stars

Table 2. Hot-spot mutations in the exon 4 and exon 12 regions of the *TGFBI* gene and primer sequences used to amplify these regions

Target gene region	Target mutation	RS no	Primer sequence (5'→3') (F: Forward / R: Reverse)	Product size (base pairs)	Melting temperature (°C)	Source
Exon 4	Arg124Ser	rs121909210	F: CCCCAGAGGCCATCCCTCCT R: AACATGTTCTCAGCCCTCGT	481	58.8	Yaylacioglu Tuncay et al., 2016 ²²
Exon 12	Arg555Trp	rs121909208	F: CATTCCAGTGGCCTGGACTCTACTATC R: CCCTGGTTGGCCTCATCCTT	431	62.8	Li et al., 2012

family members or the control subjects (Figure 5b). In addition, the single nucleotide polymorphism (SNP) Phe540Phe, which is a silent mutation previously reported in the GenBank™, was detected in the exon 12 region in sequence analyses of 4 GCD1 patients and 1 unaffected participant (IV-14 and IV-12

from family 1; V-12 and V-16 from family 2; and in 1 unrelated control subject) (Figure 6a and b). A SNP (rs2072239) located in the intronic region of the target gene region was detected in 3 affected family members (IV-14 from family 1, V-12 and VI-12 from family 2), and 2 unaffected family members (V-11 from family 2 and IV-25 from family 3).

The Arg124Ser mutation was not detected in the exon 4 region of *TGFBI* gene in any of the affected or unaffected participants. No other mutation or polymorphism was detected in the exon 4 region (Figure 5c).

Discussion

The *TGFBI* gene has a key role in the genetic basis of GCD1 and encodes the TGFBI protein, which is synthesized primarily by epithelial cells and partly by keratocytes in the cornea, and released into the stromal matrix. This protein plays an important role in establishing and maintaining matrix organization, and heterogeneity in the *TGFBI* gene, encoding this protein, leads to different clinical presentations. In particular, mutations at R124 and R555 in the exon 4 and exon 12 regions, which encode the first and fourth FAS1 domains of the protein respectively, have been shown to cause different types of dystrophies. Of the mutations that occur at position 124 of exon 4, the R124H mutation results in GCD2 (granular-lattice, Avellino), the R124C mutation results in LCD type 1, and the R124L mutation results in Reis-Bückler corneal dystrophy. Of the mutations at position 555 in exon 12, the R555W mutation causes GCD1 and the R555Q mutation causes Thiel-Behnke

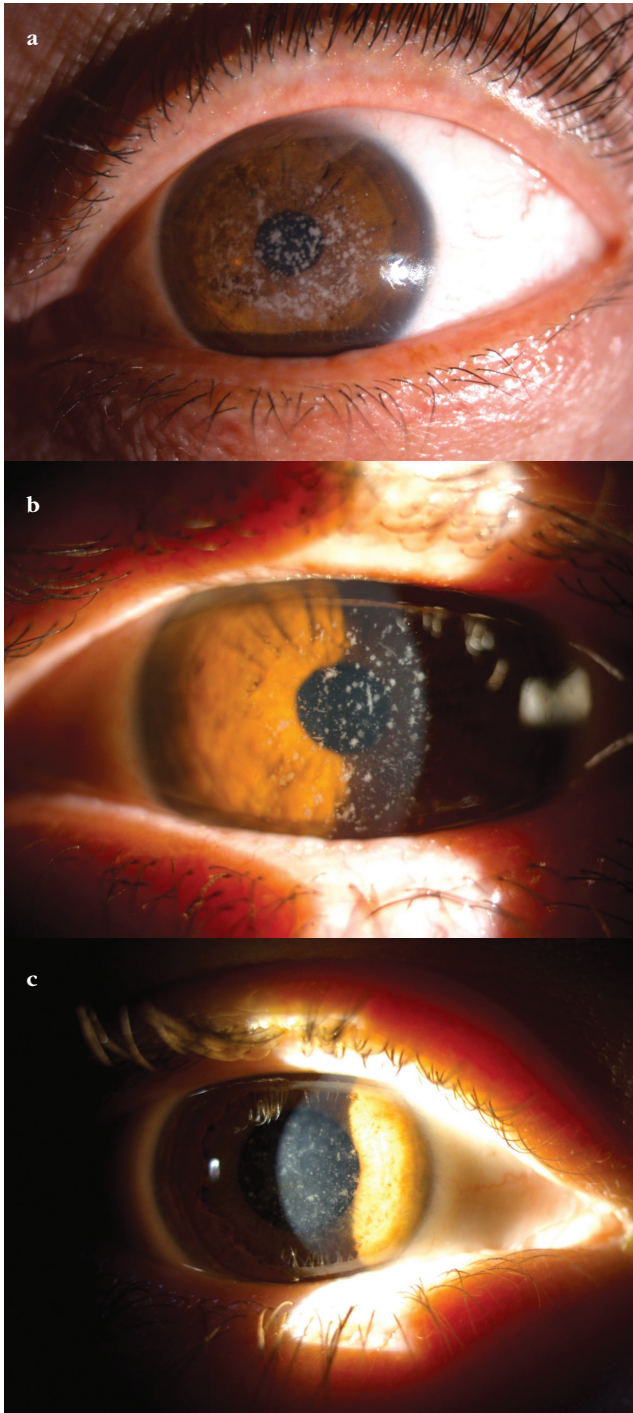


Figure 4. Anterior segment photographs of a) a 72-year-old male patient (III-6) from family 1 who had photophobia and vision loss, b) a 73-year-old female patient (IV-12) from family 2, and c) a 20-year-old female patient (IV-12) from family 3. Small, discrete, sharp-edged, breadcrumb-like grayish-white opacities are observed

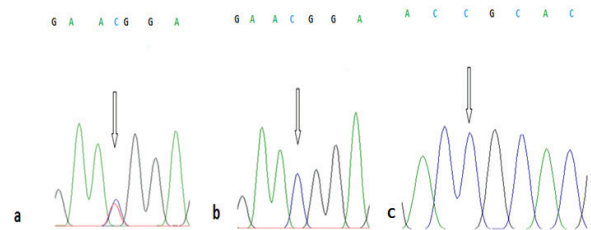


Figure 5. Sequence analysis results for the 1663C→T (Arg555Trp) change in the exon 12 region. a) Electropherogram of C/T heterozygous genotype, b) Electropherogram of C/C homozygous genotype. No individuals with the T/T homozygous genotype were detected in this study. c) Sequence analysis results for 370C→T (Arg124Ser) in the exon 4 region. All individuals included in the study were C/C homozygotes

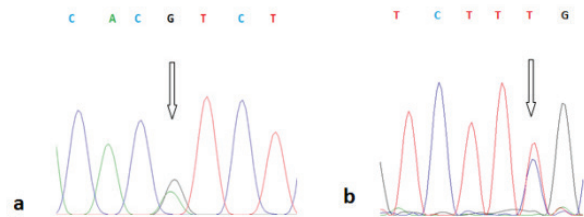


Figure 6. a) Electropherogram of the c.32924G→A (rs2072239) heterozygous genotype detected in the intron 12 region, b) Electropherogram of the 1620T→C (Phe540Phe) heterozygous genotype in the Exon 12 region

corneal dystrophy.^{3,11} Different mutations in the *TGFBI* gene, even if they occur at the same position, have been shown to cause different corneal dystrophies by altering folding, proteolysis, accumulation, and half-life (turnover) of the protein.^{13,14,15,16}

TGFBI and *Drosophila fascilin I* are highly homologous members of a superfamily of proteins containing FAS1 domains.¹⁴ In a study using a homology model, it was reported that mutations in codons Arg124 and Arg555 can alter stability by affecting protein-protein interactions. The Arg124 residue is located between the $\alpha 1$ and $\alpha 2$ helices of the first FAS1 domain, while the Arg555 residue is located in the binding region of the $\alpha 3$ and $\alpha 4$ helices of the fourth FAS1 domain, and both are predicted regions of proteolytic degradation.¹⁰ It was demonstrated by NMR (liquid-state nuclear magnetic resonance) spectroscopy that proteolysis occurred between the Arg557 and 558 residues of the normal *TGFBI* protein, but with the Arg555Trp mutation this domain became resistant to proteolysis.¹⁷

Mutations occurring at different sites of the *TGFBI* gene result in the accumulation of *TGFBI* protein as insoluble residues of varying forms in different layers of the cornea, thereby causing clinical variations. More than 50 mutations detected in the *TGFBI* gene have been associated with various corneal dystrophies characterized by the extracellular accumulation of insoluble mutant protein (amyloid, hyaline) in the cornea, such as granular, lattice, Avellino, Bowman layer types 1 and 2, and basal membrane corneal dystrophy.¹² FAS1 domains are regions with a compact globular structure containing an α -helix and α -layer.¹⁸ Two hot-spot mutations at positions R124 and R555 in the first and fourth FAS1 domains of *TGFBI*, respectively, are the most frequent mutations in different ethnic populations.¹⁹ The mutation most commonly associated with GCD1 is the Arg555Trp mutation, which occurs in the fourth FAS1 domain. According to the IC3D classification, this mutation is accepted as the mutation associated with GCD1. Although rare, the Arg124Ser mutation in the first FAS1 domain was also shown to be associated with GCD1.²⁰

In one of two related studies conducted in Turkey, Kiratlı et al.²¹ screened the exon 4 and 12 regions using the single-strand conformation polymorphism (SSCP) method and identified the Arg555Trp mutation in a large Turkish family with 52 members, 26 of whom had GCD1. Yaylacioglu Tuncay et al.²² obtained the same result in 12 GCD1 patients analyzed for both hot-spot mutations. Although the exact prevalence of corneal dystrophies in Turkey is unknown, there are a large number of affected families, especially in the Central Anatolian region.

In this study, the Arg555Trp mutation was detected in 16 individuals with GCD1 who belonged to 3 large families from the province of Konya and its surroundings. It has been shown that while the Arg555 residue in a normal *TGFBI* protein is exposed and subject to lysis, the Trp555 mutant residue is buried in the hydrophobic cavity of the fourth FAS1 domain of the protein.¹⁷ It was also demonstrated in a molecular dynamics simulation that this mutation causes the C-terminus of the $\alpha 3$ helix of the lytic region of this mutation to be less flexible,

thereby conferring proteolytic resistance.¹⁷ These findings explain the accumulation of deposits of *TGFBI* in the matrix in the pathogenesis of GCD1. The degradation of extracellular matrix proteins is just as essential as their production for cellular processes such as tissue development, remodeling, and repair, and the disruption of this balance plays a role in the pathogenesis of many diseases, including corneal dystrophies.

Our findings in this study support the view expressed in the literature that the R555W mutation in the *TGFBI* gene is involved in the genetic basis of GCD1. In this study using sequence analysis to evaluate the entirety of the exon 4 and exon 12 regions, which encode the functionally critical FAS1 domains, we detected two variations in the exon 12 region other than the known hot-spot mutation at position R555. One of these was a variation at position 540 that was a silent mutation causing no amino acid change. No relationship was observed between GCD1 and the Phe540Phe mutation that we detected in 3 GCD1 patients and 2 unaffected individuals. There are studies in the literature suggesting that a missense mutation (Phe540Ser) and a deletion (Phe540del) at the same position are associated with LCD1/3A.^{23,24} It is suggested that the mutation we detected in this position, which is considered a possible hot-spot, is not associated with the disease because it did not cause changes in protein structure and was also detected in unaffected individuals. In this study, no relationship was established between the GCD1 phenotype and mutation rs2072239, an intronic SNP that we identified in 3 GCD1 patients and 2 unaffected individuals.

Performing genetic analyses in the families of affected individuals is important for diagnosis in the early stages or before the appearance of clinical symptoms and also for clinical follow-up and treatment planning. Genetic analyses are also used to differentiate the different corneal stromal dystrophies that have similar clinical features. In GCD2, which is caused by the R124H mutation and is most often clinically confused with GCD1, the granular deposits are fewer in number and lattice-like linear and stellate deposits are observed in later stages.^{2,25} In light microscopy studies evaluating histopathological structures, Masson trichrome-positive deposits are observed in GCD1, while GCD2 exhibits hyaline and amyloid deposits that stain with Masson trichrome and Congo red, found from the basal epithelium to the deep stroma.^{2,25} On the other hand, genetic analyses are important for definitive diagnosis of individuals affected by Reis-Bückler and Thiel-Behnke corneal dystrophies, which are difficult to diagnose based on clinical and histopathological features.

Another point to consider is that in *TGFBI*-related dystrophies, clinical differences can be observed even among members of the same family. This supports the idea that other matrix elements may also contribute to the effect of *TGFBI* protein in the formation of corneal deposits. Other factors independent of *TGFBI* may be involved, or there may be factors that regulate *TGFBI* or epigenetic factors. It has been shown in vitro and in vivo that Sp1 and Sp3 binding sites in the promoter region of the *TGFBI* gene are occupied by these factors in

cells expressing TGFBI. Regarding epigenetic mechanisms, it was shown that H3K4Me1,3 is enriched and H3K27Me3 is suppressed in the promoters of *TGFBI* and matrix-related genes.²⁶ However, more epigenetic studies are needed.

GCD1 is more common than other corneal dystrophies due to its autosomal dominant inheritance, and although the increase in deposits with age impairs vision and eventually necessitates corneal transplantation, the deposits recur in the graft and current treatment approaches do not provide permanent recovery; therefore, genetic disorder-regulating gene therapy trials are needed for this disease. Clarifying the structure, function, and regulatory processes of the *TGFBI* gene and protein and understanding the genetic architecture of different corneal dystrophies and at what stages the molecular mechanisms are disrupted will determine future treatment strategies.

Ethics

Ethics Committee Approval: Approval for the study was obtained from the Selçuk University Faculty of Medicine Ethics Committee (2017/193).

Informed Consent: All subjects were informed and their consent was obtained prior to their participation in the study.

Peer-review: Externally and internally peer-reviewed.

Authorship Contributions

Surgical and Medical Practices: B.B., Concept: H.A., B.B., Design: H.A., D.E.K., B.B., Data Collection or Processing: B.B., F.Ö., Analysis or Interpretation: F.M., H.A., D.E.K., Literature Search: F.M., H.A., D.E.K., Writing: F.M., H.A.

Conflict of Interest: No conflict of interest was declared by the authors.

Financial Disclosure: The study was conducted with the support of the Scientific Research Project Coordinator of Selçuk University (Project Number: 17202039).

Acknowledgements

We would like to thank surgeon İsmail Dođru, MD, associate professor of ophthalmology at Akşehir State Hospital, for his assistance in the process of enrolling patients in this study.

References

- Kanski JJ, Bowling B. Cornea. In: Ken N, Andrew P, eds. Klinik Oftalmoloji Sistematik Yaklaşım (9. basım). Ankara, Güneş Tıp Kitabevleri; 2013:212-224.
- Weiss JS, Moller HU, Aldave AJ, Seitz B, Bredrup C, Kivela T, Munier FL, Rapuano CJ, Nischal KK, Kim EK, Sutphin J, Busin M, Labbe A, Kenyon KR, Kinoshita S, Lisch W. IC3D classification of corneal dystrophies—edition 2. *Cornea*. 2015;34,2:117-159.
- Evans CJ, Davidson AE, Carnt N, Rojas Lopez KE, Veli N, Thuang CM, Tuft SJ, Hardcastle AJ. Genotype-phenotype correlation for TGFBI corneal dystrophies identifies p.(G623D) as a novel cause of epithelial basement membrane dystrophy. *Investigative Ophthalmology & Visual Science*. 2016;13:5407-5414.
- Aydın P, Akova YA. Anatomi. In: Pınar A, Yonca A.A eds. Temel Göz Hastalıkları (1. basım). Ankara, Güneş Kitabevi; 2001:160-166.
- Escribano J, Hernando N, Ghosh S, Crabb J, Coca-Prados M. cDNA from human ocular ciliary epithelium homologous to beta ig-h3 is preferentially expressed as an extracellular protein in the corneal epithelium. *Journal of Cellular Physiology*. 1994;3:511-521.
- Korvatska E, Henry H, Mashima Y, Yamada M, Bachmann C, Munier FL, Schorderet DE. Amyloid and non-amyloid forms of 5q31-linked corneal dystrophy resulting from kerato-epithelin mutations at Arg-124 are associated with abnormal turnover of the protein. *The Journal of Biological Chemistry*. 2000;15:11465-11469.
- Meek KM, Knupp C. Corneal structure and transparency. *Progress in Retinal and Eye Research*. 2015;49:1-16.
- Poulsen ET, Runager K, Nielsen NS, Lukassen MV, Thomsen K, Snider P, Simmons O, Vorum H, Conway SJ, Enghild JJ. Proteomic profiling of TGFBI-null mouse corneas reveals only minor changes in matrix composition supportive of TGFBI knockdown as therapy against TGFBI-linked corneal dystrophies. *The FEBS Journal*. 2018;285:101-114.
- Gu Z, Zhao P, He G, Wan C, Ma G, Yu L, Zhang J, Feng G, He L, Gao L. An Arg124His mutation in TGFBI associated to Avellino corneal dystrophy in a Chinese pedigree. *Molecular Vision*. 2011;17:3200-3207.
- Han KE, Choi SI, Kim TI, Maeng YS, Stulting RD, Ji YW, Kim EK. Pathogenesis and treatments of TGFBI corneal dystrophies. *Progress in Retinal and Eye Research*. 2016;50:67-88.
- Kim BY, Olzmann JA, Choi SI, Ahn SY, Kim TI, Cho HS, Suh H, Kim EK. Corneal dystrophy-associated R124H mutation disrupts TGFBI interaction with Periostin and causes mislocalization to the lysosome. *The Journal of Biological Chemistry*. 2009;284:19580-19591.
- Munier FL, Korvatska E, Djemai A, Le Paslier D, Zografos L, Pescia G, Schorderet DE. Kerato-epithelin mutations in four 5q31-linked corneal dystrophies. *Nature Genetics*. 1997;15:247-251.
- Fandrich M, Fletcher MA, Dobson CM. Amyloid fibrils from muscle myoglobin. *Nature*. 2001;410:165-166.
- Clout NJ, Hohenester E. A model of FAS1 domain 4 of the corneal protein beta(ig)-h3 gives a clearer view on corneal dystrophies. *Molecular Vision*. 2003;9:440-448.
- Munishkina LA, Fink AL, Uversky VN. Conformational prerequisites for formation of amyloid fibrils from histones. *Journal of Molecular Biology*. 2004;342:1305-1324.
- Runager K, Basaiaawmoit RV, Deva T, Andreasen M, Valnickova Z, Sorensen CS, Karring H, Thogersen IB, Christiansen G, Underhaug J, Kristensen T, Nielsen NC, Klintworth GK, Otzen DE, Enghild JJ. Human phenotypically distinct TGFBI corneal dystrophies are linked to the stability of the fourth FAS1 domain of TGFBIp. *Journal of Biological Chemistry*. 2011;286:4951-4958.
- Underhaug J, Koldso H, Runager K, Nielsen JT, Sorensen CS, Kristensen T, Otzen DE, Karring H, Malmendal A, Schiott B, Enghild JJ, Nielsen NC. Mutation in transforming growth factor beta induced protein associated with granular corneal dystrophy type 1 reduces the proteolytic susceptibility through local structural stabilization. *Biochimica et Biophysica Acta*. 2013;1834:2812-2822.
- Clout NJ, Tisi D, Hohenester E. Novel fold revealed by the structure of a FAS1 domain pair from the insect cell adhesion molecule fasciclin I. *Structure (London, England:1993)*. 2003;11:197-203.
- Yang J, Han X, Huang D, Yu L, Zhu Y, Tong Y, Zhu B, Li C, Weng M, Ma X. Analysis of TGFBI gene mutations in Chinese patients with corneal dystrophies and review of the literature. *Molecular Vision*. 2010;16:1186-1193.
- Lakshminarayanan R, Chaurasia SS, Anandalakshmi V, Chai SM, Murugan E, Vithana EN, Beuerman RW, Mehta JS. Clinical and genetic aspects of the TGFBI-associated corneal dystrophies. *The Ocular Surface*. 2014;12:234-251.
- Kiratli H, Irkeç M, Ozgul K, Oğus A. The phenotype of arg555trp mutation in a large Turkish family with corneal granular dystrophy. *European Journal of Ophthalmology*. 2001;11:333-337.
- Yaylacioglu Tuncay F, Kayman Kurekci G, Guntekin Ergun S, Pasaoglu OT, Akata RE, Dincer PR. Genetic analysis of CHST6 and TGFBI in Turkish patients with corneal dystrophies: Five novel variations in CHST6. *Molecular Vision*. 2016;22:1267-1279.
- Stix B, Leber M, Bingemer P, Gross C, Ruschoff J, Fandrich M, Schorderet DE, Vorwerk CK, Zacharias M, Roessner A, Rocken C. Hereditary lattice corneal

- dystrophy is associated with corneal amyloid deposits enclosing C-terminal fragments of keratoepithelin. *Investigative Ophthalmology & Visual Science*. 2005;46:1133-1139.
24. Munier FL, Frueh BE, Othenin-Girard P, Uffer S, Cousin P, Wang MX, Heon E, Black GC, Blasi MA, Balestrazzi E, Lorenz B, Escoto R, Barraquer R, Hoeltzenbein M, Gloor B, Fossarello M, Singh AD, Arsenijevic Y, Zografos L, Schorderet DE. *BIGH3* mutation spectrum in corneal dystrophies. *Investigative Ophthalmology & Visual Science*. 2002;43:949-954.
25. Kennedy SM, McNamara M, Hillery M, Hurley C, Collum LM, Giles S. Combined granular lattice dystrophy (Avellino corneal dystrophy) *Br J Ophthalmol*. 1996;80:489-490.
26. Maeng YS, Lee GH, Choi SI, Kim KS, Kim EK. Histone methylation levels correlate with *TGFBIp* and extracellular matrix gene expression in normal and granular corneal dystrophy type 2 corneal fibroblasts. *BMC Medical Genomics*. 2015;8:74.



Anterior Segment Analysis and Evaluation of Corneal Biomechanical Properties in Children with Joint Hypermobility

© Sadık Etka Bayramoğlu*, © Nihat Sayın*, © Dilbade Yıldız Ekinci**, © Nuray Aktay Ayaz***, © Mustafa Çakan****

*University of Health Sciences Kanuni Sultan Süleyman Training and Research Hospital, Clinic of Ophthalmology, İstanbul, Turkey

**University of Health Sciences Gazi Yaşargil Training and Research Hospital, Clinic of Ophthalmology, Diyarbakır, Turkey

***University of Health Sciences Kanuni Sultan Süleyman Training and Research Hospital, Clinic of Pediatric Rheumatology, İstanbul, Turkey

****University of Health Sciences Şanlıurfa Training and Research Hospital, Clinic of Pediatric Rheumatology, Şanlıurfa, Turkey

Abstract

Objectives: To compare anterior segment parameters and biomechanical analysis of the cornea in children with joint hypermobility (JH) and healthy children.

Materials and Methods: Cross-sectional case-control study. Fifty eyes of 25 children with JH were compared with 74 eyes of 37 healthy age- and sex-matched controls in terms of refractive, anterior segment topographic, and corneal biomechanical measurements. Axial length (AL) was measured with a Nidek AL-Scan biometry device; corneal-compensated intraocular pressure (IOPcc), Goldmann-correlated IOP (IOPg), corneal hysteresis (CH), and corneal resistance factor (CRF) were measured with a Reichert ocular response analyzer (ORA). Central corneal thickness (CCT), anterior chamber depth (ACD), K1/K2 values, iris diameter, and anterior chamber volume (ACV) were measured with a Sirius topography device.

Results: Mean age in the JH group was 10.56±4.03 years, while that of the control group was 11.27±2.59 years (p=0.23). Spherical equivalent was -0.22±1.02 diopter (D) in the JH group and -0.12±1.12 D in the control group (p=0.60); CCT was 23.01±0.82 µm in the JH group and 23.17±0.82 µm in the control group (p=0.33). There were no significant differences between the two groups in terms of age, sex, IOP, IOPcc, IOPg, CH, CRF, AL, K1, K2, iris diameter, ACD, and ACV.

Conclusion: JH, which causes increased flexibility of the joints, was concluded not to cause a significant change in the corneal biomechanical markers of CRF and CH or in anterior segment topographic parameters.

Keywords: Cornea, joint hypermobility, ocular response analyzer

Introduction

Hypermobility joints are joints having more flexibility than normal, considering age, gender, and ethnic background. In current rheumatology practice, diagnosis of joint hypermobility (JH) is made by Beighton scoring system, with a score of 4 or

more accepted as above normal mobility. This score determines whether there is increased elasticity in 5 body regions: the spine/hip, elbow, fifth metacarpal joint, thumb/wrist, and knee.¹ Hypermobility joints are prominent features of hereditary connective tissue diseases associated with genetic variations in collagen fibers, such as Marfan Syndrome, hypermobile

Address for Correspondence: Sadık Etka Bayramoğlu, University of Health Sciences Kanuni Sultan Süleyman Training and Research Hospital, Clinic of Ophthalmology, İstanbul, Turkey Phone: +90 505 336 32 41 E-mail: sadiketka@windowslive.com **ORCID-ID:** orcid.org/0000-0002-9502-4368

Received: 05.03.2019 **Accepted:** 25.12.2019

Cite this article as: Bayramoğlu SE, Sayın N, Ekinci DY, Aktay Ayaz N, Çakan M. Anterior Segment Analysis and Evaluation of Corneal Biomechanical Properties in Children with Joint Hypermobility. Turk J Ophthalmol. 2020;50:71-74

Ehlers-Danlos syndrome (EDS), formerly known as EDS type 3, osteogenesis imperfecta (OI), and JH syndrome (JHS).² While JH is a simple entity of increased joint motion angles, JHS diagnosis is made by systemic findings in addition to joint and musculoskeletal system symptoms.¹

JH is more commonly identified in children, and the incidence decreases with age.³ In epidemiological studies the prevalence of JH was reported as 5 to 30%.^{4,5,6,7,8} The biomechanical characteristics of the cornea are formed by the stromal layer comprising type I collagen fibers. Descemet’s membrane consists of softer type IV collagen. Therefore, the cornea is one of the target tissues in connective tissue diseases.^{9,10,11}

The influence of JH on corneal elasticity and biomechanics has not been clarified. As far as we know, there is no current study investigating the anterior segment parameters of individuals with JH. The aim of our study was to compare the corneal biomechanical and anterior segment parameters of children with JH and healthy children.

Materials and Methods

In this cross-sectional study, 50 eyes of 25 JH patients admitted to the ophthalmology and pediatric rheumatology clinics of University of Health Sciences Kanuni Sultan Süleyman Training and Research Hospital and 74 eyes of 37 healthy age- and gender-matched controls were compared in terms of refractive, anterior segment topographic, and corneal biomechanical parameters. The study was performed in accordance with the Declaration of Helsinki and with the approval of the ethics committee of University of Health Sciences Kanuni Sultan Süleyman Training and Research Hospital. Written informed consent was obtained from the legal guardians of all children.

All participants underwent ophthalmological examination including refraction, biomicroscopy, and fundus examination. Patients with additional ocular diseases other than refractive error and those with previous intraocular surgery were not included in the study.

Diagnosis of JH was made according to Beighton score of 4 or more (Table 1). A detailed rheumatologic examination of the control group was made and their Beighton score was calculated. All control subjects had scores lower than 4.

Table 1. Nine-point Beighton hypermobility score

The ability to	Right	Left
Passively dorsoflex the fifth metacarpophalangeal joint $\geq 90^\circ$	1	1
Oppose the thumb to volar aspect of the ipsilateral forearm	1	1
Hyperextend the elbow to $\geq 10^\circ$	1	1
Hyperextend the knee to $\geq 10^\circ$	1	1
Place hands flat on the floor without bending the knees	1	
Total	9	

Corneal hysteresis (CH), corneal resistance factor (CRF), intraocular pressure (IOP), corneal-compensated IOP (IOPcc), and Goldmann-correlated IOP (IOPg) values were measured using an ocular response analyzer (ORA, Reichert Ophthalmic Instruments, Buffalo, NY, USA). All measurements were taken by an experienced technician. For each eye, 3 measurements with a waveform score above 5 were performed. The mean of these 3 measurements was used in statistical analyses.

Central corneal thickness (CCT), anterior chamber depth (ACD), keratometry values (K1/K2), iris diameter, and anterior chamber volume (ACV) were measured with a Sirius Topography (Sirius®, Costruzione Strumenti Oftalmici, Florence, Italy) device. An experienced technician took 3 measurements for each eye and the measurement with best alignment and fixation was used for statistical analysis.

Axial length (AL) was measured with a Nidek AL-Scan (Nidek, Aichi, Japan) biometry device.

Spherical equivalent (SE) was measured with a Topcon KR-800 Auto-refractometer (Topcon, Tokyo, Japan). IOP was measured with a Nidek NT-510 (Nidek, Aichi, Japan) non-contact tonometer.

Tear film breakup time (TBUT) was recorded in seconds as the time to disintegration of the fluorescein-stained tear film. The mean of 3 separate TBUT measurements was used for statistical analysis. To assess tear production, topical 0.05% proparacaine hydrochloride (Alcaine, Alcon, Puurs, Belgium) was instilled and standard Schirmer test paper was placed under the lateral third of the lower lid. Baseline secretion was measured in mm as the length of paper wetted after 5 min.

Lower eyelid laxity was defined as being able to pull the lower lid more than 10 mm from the globe and delayed return to neutral position. If the inner canthus was above the outer canthus, this finding was assessed as antimongoloid slant.

Statistical analyses were performed using SPSS (SPSS Inc, PASW Statistics for Windows, version 24, Chicago, USA). The normality of distribution of continuous variables was tested by Shapiro-Wilk test. Mann-Whitney U test (for non-normal data) was used for comparison of two independent groups and chi-square test was used to assess relationships between categorical variables. Generalized estimation equation (GEE) analyses were performed to compare groups according to numerical variables

Table 2. Comparison of intraocular pressure (mmHg) and corneal biomechanical parameters measured with non-contact tonometer and ocular response analyzer

	Joint hypermobility	Control	p value
IOP	18.06±3.05	17.93±3.45	0.836
IOPcc	16.29±2.90	16.87±4.42	0.516
IOPg	16.91±4.16	17.94±4.20	0.230
CH	11.23±1.86	11.52±2.06	0.472
CRF	11.54±1.88	12.10±2.07	0.167

IOP: Intraocular pressure, IOPcc: Corneal-compensated IOP, IOPg: Goldmann-correlated IOP, CH: Corneal hysteresis, CRF: Corneal resistance factor

while considering the effect of within-subject variations for each eye. P value less than 0.05 was accepted as statistically significant.

Results

The mean age was 10.6±4.0 years in the JH group and 11.3±2.6 years in the control group (p=0.39). In the JH group, 19 (76.0%) participants were female while in the control group 28 (75.6%) were female (p=0.97). In terms of height and weight, there was no statistically significant difference between the groups (p=0.51, p=0.32). The median values of Beighton score were 5 (range: 4-7) and 2 (range: 0-3) in the JH and control groups, respectively. The difference was significant (p=0.001)

Spherical equivalent was -0.22±1.02 diopters (D) in the JH group and -0.12±1.12 D in the control group (p=0.60), CCT was 549.48±45.88 µm in the JH group and 560.19±35.51 µm in the control group (p=0.118), and axial length was 23.01±0.82 mm in the JH group and 23.17±0.82 mm in the control group (p=0.326). For corneal biomechanical parameters, the JH and control groups had CH values of 11.23±1.89 and 11.52±2.06 (p=0.472) and CRF values of 11.54±1.88 and 12.1±2.07 (p=0.167), respectively. There were no significant differences between the groups in terms of IOP, IOPcc, or IOPg (Table 2). Topographic parameters of the anterior segment such as K1, K2, iris diameter, ACD, and ACV were similar between the JH and control group (Table 3).

The mean TBUT was 9.74±1.48 seconds in the JH group and 9.83±1.46 seconds in the control group (p=0.71). The mean Schirmer test result of the study and control groups were 13.26±2.32 mm and 14.04±2.16 mm, respectively (p=0.06).

Lower eyelid laxity was identified in 4 (16.0%) children in the JH group and 2 (5.4%) children in the control group (p=0.07). Antimongoloid slant was identified in 3 (12.0%) children in the JH group and in 2 (5.4%) children in the control group (p=0.20).

Table 3. Refractive, topographic, and biometric parameters measured with KR-800 Auto-refractometer, Sirius Topography, and Nidek AL-Scan Biometry devices

	Joint hypermobility	Control	p value
Spherical equivalent, D	-0.22±1.02	-0.12±1.12	0.640
K1, D	42.66±1.52	43.04±1.35	0.185
K2, D	43.63±1.50	44.00±1.36	0.198
CCT, µm	549.48±45.89	560.19±35.51	0.118
Iris diameter, mm	12.23±0.45	12.31±0.47	0.359
ACD, mm	3.69±0.29	3.75±0.30	0.426
ACV, mm ³	169.58±21.74	159.45±33.23	0.071
Axial length, mm	23.01±0.82	23.17±0.82	0.326

ACD: Anterior chamber diameter, ACV: Anterior chamber volume, CCT: Central corneal thickness, D: Diopter, K: Keratometry value, Data are presented as mean ± standard deviation

Discussion

JH may be seen as a part of syndromes like JHS, hypermobile EDS, OI, and Marfan syndrome. JH is not considered a disease but rather a variation of normal. To the best of our knowledge, there is no study evaluating the anterior segment structures of the eyes of children with JH by advanced ocular imaging systems in the PubMed database up to present. In contrast, there are reports concerning pathological ocular findings such as lid laxity, conjunctivochalasis, keratoglobus, keratoconus, lens luxation, pathologic myopia, angioid streaks, scleral thinning, and retinal detachment in these rare syndromes.^{12,13,14,15,16} Also, there are few studies in the literature that perform anterior segment analysis with topography and confocal microscopy imaging methods in patients with JHS, hypermobile EDS, and other EDS types.^{13,17,18} Although JH is a common finding of these rare syndromes, it is not appropriate to compare ocular findings with these syndromes because they are different clinical conditions. Based on our literature search about JH, we found one epidemiological study. In that study ocular findings were identified and questioned by the rheumatologists but imaging with advanced ocular devices was not performed.¹⁹

In an epidemiological study from Turkey, 861 high school children were evaluated by rheumatologists, and 11.7% of them were found to have JH.¹⁹ They reported no significant difference for frequency of lid laxity, antimongoloid slant, and myopia between the children with JH and healthy group.¹⁹ In our study, it was observed that mean SE, frequency of eyelid laxity, and antimongoloid slant were not different between the two groups. We would like to draw attention to the fact that the frequency of myopia was reported according to questioning of the students by a rheumatologist in the study by Seçkin et al.¹⁹ In other epidemiological studies indicating the incidence of JH in the literature, ocular findings were not included.^{3,5,6,7,8}

The main objective of our study was to investigate whether there was a change in the biomechanical and topographic parameters of the cornea in individuals with JH compared to normal individuals. Although there has been only one study investigating the relationship between keratoconus and JH in the literature, keratoconus diagnosis was made according to keratometry and biomicroscopic findings such as central corneal thinning, anterior Fleischer ring, or Vogt lines in that study.²⁰ It was reported that the incidence of JH was not increased in patients with keratoconus.²⁰ More recent studies showed that biomechanical parameters such as CCT, CH, and CRF and topographic parameters of the cornea were affected in mild keratoconus.²¹ Our study, performed with advanced anterior segment imaging methods, supports the findings of Street et al.²⁰ that there were no significant differences between the two groups in terms of biomechanical and topographic parameters and children with JH do not have increased risk of keratoconus.

Although there are studies reporting that the prevalence of JH is high (up to 30%) among healthy children, to our knowledge, there is no other study in the literature examining the anterior segment findings of JH in this age group. We have

demonstrated that there was no significant difference between children with JH and healthy controls in terms of anterior segment topography, corneal biomechanical properties, and refractive values using GEE modeling. Our findings suggest that JH is not an ophthalmologically important entity, because anterior segment parameters did not differ from the normal population. Comparative studies with more participants and wider age range would be valuable regarding this topic, which has not been sufficiently researched so far.

Ethics

Ethics Committee Approval: The study was performed in accordance with the Declaration of Helsinki and with the approval of the ethics committee of University of Health Sciences Kanuni Sultan Süleyman Training and Research Hospital.

Informed Consent: Written informed consent was obtained from the legal guardians of all children.

Peer-review: Externally and internally peer reviewed.

Authorship Contributions

Surgical and Medical Practices: S.E.B., D.Y.E., N.A.A., M.Ç., Concept: S.B.B., N.S., Design: S.B.B., N.S., Data Collection or Processing: S.B.B., N.S., D.Y.E., N.A.A., M.Ç., Analysis or Interpretation: S.B.B., Literature Search: S.B.B., N.S., D.Y.E., N.A.A., M.Ç., Writing: S.E.B.

Conflict of Interest: No conflict of interest was declared by the authors.

Financial Disclosure: The authors declared that this study received no financial support.

References

1. Fikree A, Aziz Q, Grahame R. Joint hypermobility syndrome. *Rheum Dis Clin North Am.* 2013; 39:419-430.
2. Malfait F, Hakim A, De Paepe A, Grahame R. The genetic basis of the joint hypermobility syndromes. *Rheumatology.* 2006; 45:502-507.
3. Beighton P, Solomon L, Soskolne CL. Articular mobility in an African population. *Ann Rheum Dis.* 1973; 32:413-418.
4. Murray K, Woo P. Benign joint hypermobility in childhood. *Rheumatology.* 2001; 40:489-491.
5. Harreby M, Nygaard B, Jessen T, Larsen E, Storr-Paulsen A, Lindahl A, Fisker I, Laegaard E. Risk factors for low back pain in a cohort of 1389 Danish school children: an epidemiologic study. *Eur Spine J.* 1999;8:444-450.
6. El-Garf A, Mahmoud G, Mahgoub E. Hypermobility among Egyptian children: prevalence and features. *J Rheumatol.* 1998;25:1003-1005.
7. Rikken-Bultman DG, Wellink L, van Dongen PW. Hypermobility in two Dutch school populations. *Eur J Obstet Gynecol Reprod Biol.* 1997;73:189-192.
8. Subramanyam V, Janaki K. Joint hypermobility in south Indian children. *Indian Pediatr.* 1996;33:771-771.
9. Fratzl P, Daxer A. Structural transformation of collagen fibrils in corneal stroma during drying. An x-ray scattering study. *Biophys J.* 1993;64:1210-1214.
10. Kotecha A. What biomechanical properties of the cornea are relevant for the clinician? *Surv Ophthalmol.* 2007;52 Suppl 2:S109-114.
11. Patel SJ, Lundy DC. Ocular manifestations of autoimmune disease. *Am Fam Physician.* 2002; 66:991-998.
12. Cameron JA. Corneal abnormalities in Ehlers-Danlos syndrome type VI. *Cornea.* 1993;12:54-59.
13. Gharbiya M, Moramarco A, Castori M, Parisi F, Celletti C, Marengo M, Mariani I, Grammatico P, Camerota F. Ocular features in joint hypermobility syndrome/Ehlers-Danlos syndrome hypermobility type: a clinical and in vivo Confocal Microscopy Study. *Am J Ophthalmol.* 2012;154:593-600.e591.
14. Green W, Friedman-Kien A, Banfield W. Angioid streaks in Ehlers-Danlos syndrome. *Arc Ophthalmol.* 1966;76:197-204.
15. Segev F, Héon E, Cole WG, Wenstrup RJ, Young F, Slomovic AR, Rootman DS, Whitaker-Menezes D, Chervoneva I, Birk DE. Structural abnormalities of the cornea and lid resulting from collagen V mutations. *Invest Ophthalmol Vis Sci.* 2006;47:565-573.
16. Whitaker JK, Alexander P, Chau DY, Tint NL. Severe conjunctivochalasis in association with classic type Ehlers-Danlos syndrome. *BMC Ophthalmol.* 2012;12:47.
17. Mishra MB, Ryan P, Atkinson P, Taylor H, Bell J, Calver D, Fogelman I, Child A, Jackson G, Chambers JB, Grahame R. Extra-articular features of benign joint hypermobility syndrome. *Br J Rheumatol.* 1996;35:861-866.
18. Bravo JF, Wolff C. Clinical study of hereditary disorders of connective tissues in a Chilean population: joint hypermobility syndrome and vascular Ehlers-Danlos syndrome. *Arthritis Rheum.* 2006;54:515-523.
19. Seçkin Ü, Tur BS, Yılmaz Ö, Yağcı İ, Bodur H, Arasil T. The prevalence of joint hypermobility among high school students. *Rheumatol Int.* 2005;25:260-263.
20. Street DA, Vinokur ET, Waring GO, Pollak SJ, Clements SD, Perkins JV. Lack of association between keratoconus, mitral valve prolapse, and joint hypermobility. *Ophthalmology.* 1991;98:170-176.
21. Fontes BM, Ambrósio R, Jardim D, Velarde GC, Nosé W. Corneal biomechanical metrics and anterior segment parameters in mild keratoconus. *Ophthalmology.* 2010;117:673-679.



Correlation of Ocular Surface Disease and Quality of Life in Indian Glaucoma Patients: BAC-preserved versus BAC-free Travoprost

© Suresh Kumar, © Tanu Singh, © Parul Ichhpujani, © Sanchi Vohra, © Sahil Thakur

Government Medical College and Hospital, Department of Ophthalmology, Sector 32B, Chandigarh, India

Abstract

Objectives: The use of benzalkonium chloride (BAC)-preserved medications is associated with ocular surface disease (OSD) that can negatively affect quality of life (QoL) in glaucoma patients. This study aimed to compare QoL and correlate it with OSD in glaucoma patients receiving BAC-preserved and BAC-free travoprost.

Materials and Methods: A total of 110 subjects were divided into 3 groups: 40 primary open-angle glaucoma (POAG) patients using BAC-preserved travoprost, 40 POAG patients using BAC-free travoprost, and 30 age-matched controls. All patients were assessed using a single interviewer-administered format of the Ocular Surface Disease index (OSDI) and Glaucoma Quality of Life-15 (GQL-15) questionnaires.

Results: Mean GQL-15 score in the BAC group was significantly higher than in the BAC-free group (24.71 ± 7.42 vs. 17.58 ± 3.06 ; $p < 0.05$). The mean difference in GQL-15 scores between controls and the BAC-free group (1.24) was insignificant ($p > 0.05$). There was a strong positive correlation between OSDI scores and GQL-15 scores in all the groups (r values: BAC: 0.63, BAC-free: 0.23, controls: 0.29), with higher OSDI scores (severe OSD) associated with higher GQL-15 scores (worse QoL). Cronbach's alpha was 0.84 for GQL-15 and 0.75 for OSDI.

Conclusion: BAC-preserved travoprost leads to higher OSDI scores, which correlate strongly with poor QoL scores as compared to BAC-free travoprost. The use of BAC-free formulations should be encouraged to reduce the onset or worsening of OSD and impaired QoL in glaucoma patients.

Keywords: Primary open-angle glaucoma, OSDI, BAC, travoprost, GQL-15

Introduction

Quality of life (QoL) refers to the perceived quality of an individual's daily life, that is, an assessment of their well-being.¹ It is an assessment of how the individual's well-being may be affected over time by a disease. Assessment of QoL is important in the management of glaucoma patients, as it reflects the patient's own perception regarding the burden of a chronic disease. Therefore, in recent times, apart from traditional

measures such as visual acuity, intraocular pressure (IOP) and perimetry, assessment of QoL is being increasingly recognized as a critical measure for evaluating the effectiveness of treatment of glaucoma.

Ocular surface disease (OSD) is a common co-morbidity in glaucoma, affecting around 59% of glaucoma patients.² In addition, approximately 36% of these glaucoma patients have significant OSD requiring some form of treatment.² Studies have shown that all classes of topical IOP-lowering medications

Address for Correspondence: Parul Ichhpujani, Government Medical College and Hospital, Department of Ophthalmology, Sector 32B, Chandigarh, India
Phone: +9501071591 E-mail: itsdrparul@gmail.com **ORCID-ID:** orcid.org/0000-0001-6256-4002

Received: 14.07.2019 **Accepted:** 25.12.2019

Cite this article as: Kumar S, Singh T, Ichhpujani P, Vohra S, Thakur S. Correlation of Ocular Surface Disease and Quality of Life in Indian Glaucoma Patients: BAC-preserved versus BAC-free Travoprost. Turk J Ophthalmol. 2020;50:75-81

can cause ocular surface discomfort and significant ocular surface changes with long-term use.^{2,3,4} The higher incidence of OSD in glaucoma patients is largely attributed to the use of benzalkonium chloride (BAC)-preserved topical antiglaucoma medication.^{4,5,6} OSD often negatively affects the patient's ability to work and function, and therefore contributes to worsening of QoL in glaucoma patients. Since OSD can dramatically impact patients' QoL, it influences therapeutic compliance and adherence to treatment.

The Ocular Surface Disease index (OSDI), developed by the Outcome Research Group (Irvine, CA),⁷ is a 12-item questionnaire providing a rapid assessment of the symptoms of ocular irritation related to OSD and their impact on vision-related functioning. It has been found to be a reproducible, reliable and valid tool for the assessment of OSD in glaucoma patients.^{8,9,10}

Several disease-specific instruments have been used to assess QoL in glaucoma patients.^{11,12,13} The Glaucoma Quality of Life-15 (GQL-15) questionnaire is a disease-specific, 15-item questionnaire which has been shown to be reliable and have good internal consistency.¹¹ Four important domains tested in this instrument are central/near vision, peripheral vision, night vision and outdoor mobility.

Glaucoma patients treated with BAC-preserved medications often have concomitant OSD leading to worsening of their QoL. Exposure to high daily dose of BAC-containing formulations was associated with even poorer quality of life.¹⁴ After a thorough literature search, we found a paucity of data regarding OSD and its impact on the QoL of glaucoma patients. In recent years, BAC-free antiglaucoma formulations have become commercially available.^{15,16} Some studies have reported that switching from BAC-containing to BAC-free antiglaucoma medication resulted in improvement in QoL scores using the Glaucoma Symptom scale (GSS).^{17,18} The use of BAC-free formulations reduce the onset or worsening of OSD and QoL in glaucoma patients. However, no study has compared and correlated QoL scores with OSD in BAC-preserved and BAC-free medications. The present study was designed to assess QoL using the GQL-15 questionnaire and determine its correlation with OSD according to the OSDI in glaucoma patients receiving BAC-preserved and BAC-free travoprost.

Materials and Methods

The present research study was registered with the clinical trial registry of India, CTRI (CTRI/2017/12/011044CTRI) and was approved by the institutional ethics committee. It conformed to the tenets of the Declaration of Helsinki and followed HIPAA (Health Insurance Portability and Accountability Act). It was a hospital-based prospective observational study carried out in 110 subjects who visited the Glaucoma Services. Study subjects were divided into 3 groups: the first group comprised 40 primary open-angle glaucoma (POAG) patients using BAC-preserved travoprost and the second group included 40 POAG patients receiving BAC-free travoprost. A third group of 30 age-matched

subjects not receiving any topical medical treatment were recruited as controls. To ensure uniformity, we considered only a single prostaglandin analogue and included BAC-free drugs with only polyquad (polyquaternium-1) as a preservative. The following inclusion and exclusion criteria were considered for subject selection.

Inclusion Criteria: The study included POAG patients over 40 years of age of either gender, with mild to moderate glaucoma (according to Hodapp Parrish Anderson classification), who had well-controlled IOP on prostaglandin monotherapy (BAC-preserved or BAC-free) for a minimum period of 3 months. The duration of therapy was set as a maximum period of 6 months. Appropriate history was taken to rule out use of any other topical hypotensive agent prior to the institution of prostaglandin therapy.

Exclusion Criteria: Patients with pre-existing OSD (anterior or posterior blepharitis, keratitis, ocular dryness, follicular or papillary conjunctivitis) prior to initiation of antiglaucoma medical therapy, corneal abnormalities which might preclude the calculation of IOP by applanation tonometry, prior refractive eye surgery, prior filtration surgery, allergic reaction to prostaglandin analogues, pregnant or lactating females, patients using contact lenses within 3 weeks of enrollment, and patients with other visually significant diseases like cataract, diabetic retinopathy, hypertensive retinopathy, age-related macular degeneration, which might act as confounding factors causing lower QoL were excluded from the study. Patients with cognitive, hearing, or mobility impairment which precluded appropriate response to the questionnaires were also excluded from the study. Patients with glaucoma grade beyond moderate glaucoma were excluded from the study to ensure that the severity of glaucoma did not act as a confounding factor in the evaluation of the subjects' QoL.

Baseline Examination: All patients enrolled in the study underwent extensive ophthalmologic examination which included measurement of visual acuity by Snellen chart both with and without correction at a distance of 6 meters and detailed slit-lamp examination. Ocular examination was done to assess the lids (especially margins), palpebral and bulbar conjunctiva, cornea, pupillary reactions, and anterior segment, as well as posterior segment examination with +90D lens after pharmacological dilation. The IOP was measured at the time of enrollment with the help of a calibrated Goldmann applanation tonometer (GAT). Gonioscopy was performed on each patient with the help of a gonioscope (Goldmann one-mirror lens as well as Zeiss four-mirror lens). Pre-enrollment assessments specific for ruling out OSD such as Schirmer's test, tear film break-up time (TBUT), and fluorescein staining were done. Corneal fluorescein staining was graded as mild (less than 10% coverage of corneal surface), moderate (10-50% of corneal surface), and severe (more than 50% of corneal surface) and subjects with moderate or severe staining were excluded from the study. Central corneal thickness was measured using optical coherence biometer (Haag Streit, Lenstar). Visual field analysis was done with Humphrey visual field analyzer using HFA-24-2 Swedish Interactive Thresholding Algorithm (SITA) Fast 24-2 testing algorithm.

Primary open-angle glaucoma was defined as the presence of glaucomatous optic nerve head changes, open anterior chamber angles on gonioscopy, reproducible and reliable visual field on Humphrey Field Analyzer, with or without elevated IOP, in one or both eyes.

Detailed history of presence or absence of BAC, the duration since initiation of therapy, and treatment compliance was taken. The subjects found to fulfill all the inclusion criteria were asked to provide written informed consent. Subjective tolerance of the drug and QoL assessment was done using the interviewer-administered format of the OSDI and GQL-15 questionnaires, respectively. A single investigator administered both questionnaires to all the subjects at 2 different follow up visits (first after completion of 3 months of topical therapy and second at completion of 6 months). For respondents who were not literate in English, the OSDI and GQL-15 questionnaires were translated into Hindi and Punjabi, which are the most important vernacular languages in northern India.

Ocular Surface Disease Index (OSDI) Questionnaire

The OSDI questionnaire was used to evaluate subjective tolerability of the drug affecting the ocular surface in all subjects. Each of the 12 items of OSDI questionnaire was graded on a scale of 0 to 4: 0=none of the time; 1=some of the time; 2=half the time; 3=most of the time; and 4=all the time. The total OSDI score is calculated using the following formula: $OSDI = (\text{Sum of OSDI item scores} \times 100) / (\text{Total number of questions answered} \times 4)$

OSDI score ranged from 0 to 100. The patients were categorized based on the scores as follows: normal ocular surface (0-12 points), mild OSD (13-22), moderate OSD (23-32), and severe OSD (33-100).

Glaucoma-Associated Quality of Life (GQL-15) Questionnaire

The GQL-15 questionnaire was utilized to assess QoL in all patients. GQL-15 questionnaire is composed of 15 items which address 4 factors of visual disability: central and near vision (2 questions), peripheral vision (6 questions), dark adaptation and glare (6 questions), and outdoor mobility (1 question). A scale of 0 to 5 is used to code the item-level responses for each factor, where 5 represents severe difficulty due to visual reasons, 1 indicates no difficulty with performing the activity, and 0 indicates abstinence from activity due to non-visual reasons. Item scores were added to obtain a total score. Higher GQL-15 scores indicate poorer QoL. Subscale scoring for the abovementioned 4 domains of the GQL-15 was not done in our study.

Statistical Analysis

Descriptive analysis was carried out by mean and standard deviation for quantitative variables and with frequency and proportion for categorical variables. The association between categorical explanatory variables and quantitative outcome was assessed by comparing the mean values. The mean differences along with their 95% confidence interval (CI) were presented. Independent-samples t-test/ANOVA/paired-samples t-test was

used to assess statistical significance. The association between explanatory variables and categorical outcomes was assessed by cross-tabulation and comparison of percentages. Odds ratio along with 95% CI is presented. Chi-square test was used to test statistical significance. P value <0.05 was considered statistically significant. Pearson's correlation was used to measure the linear correlation between OSDI and GQL-15 scores. Pearson's correlation coefficient was mentioned as R-values; which ranged from +1 to -1, where +1 is total positive linear correlation, 0 is no correlation and -1 is total negative correlation. Cronbach's alpha was used to assess the internal consistency of the two questionnaires. IBM SPSS version 22 was used for statistical analysis.

Results

Mean age was 60.88 ± 8.48 years in the BAC group, 61.25 ± 13.32 years in the BAC-free group, and 60.42 ± 7.16 years in the control group. The difference in mean age between the groups was statistically insignificant ($p=0.45$). The proportion of males was 60%, 62.5%, and 60% respectively in the BAC, BAC-free, and control groups. The differences in the gender composition of participants among the groups was statistically not significant ($p=0.51$). The time taken for administration of the OSDI questionnaire was about 5-6 minutes, while the GQL-15 questionnaire required 7-8 minutes. The mean IOP (in mmHg) at the time of enrollment was 12.3 ± 3.8 in the BAC group, 11.9 ± 2.9 in the BAC-free group, and 10.9 ± 3.1 in the control group and the difference between the three groups was statistically insignificant ($p=0.50$). The mean central corneal thickness (in microns) in the three groups was 545 ± 30 , 541 ± 25 , and 550 ± 12 , respectively. The difference amongst the three groups was statistically insignificant ($p=0.15$). Compliance to treatment was determined based on history and was found appropriate as per the discretion of the examiner. While assessing the correlation of GQL-15 scores with visual function, GQL-15 scores correlated best with mean deviation in both eyes (MD OU) ($r=0.61$, $p=0.001$) and mean logMAR visual acuity in the worse eye ($r=-0.41$, $p=0.001$). Only a modest or weak correlation existed between pattern standard deviation and GQL-15 ($r=0.11$, $p=0.14$). Cronbach's alpha was 0.84 for GQL-15 and 0.75 for OSDI.

Comparison of mean GQL-15 scores across the study groups: Mean GQL-15 score was 24.25 ± 7.42 in the BAC group, 17.58 ± 3.06 in the BAC-free group, and 16.33 ± 1.92 in the control group. The mean difference between the BAC and BAC-free groups (6.68) was statistically significant ($p=0.047$). The mean difference between the BAC group and controls (7.92) was also statistically significant ($p=0.042$). The mean difference between the BAC-free group and controls (1.24) was not statistically significant ($p=0.057$) (Table 1).

Comparison of mean OSDI scores across the study groups: Mean OSDI scores in the BAC, BAC-free, and control groups were 29.09, 12.45, and 10.93, respectively. The mean difference between the BAC-free and BAC groups (16.63) was statistically

significant ($p < 0.01$). The mean difference between the BAC-free group and controls (1.53) was statistically insignificant ($p = 1.0$). The mean difference between the BAC group and controls (18.96) was statistically significant ($p < 0.01$) (Table 2).

There were only 23.33% subjects among controls and 32.5% in the BAC-free group with OSD, whereas the proportion of patients in the BAC group with OSD was 82.5%. The association between the groups and OSD was statistically significant ($p < 0.01$).

Correlation between OSDI and GQL-15 scores in the study groups: There was a strong positive correlation between OSDI and GQL-15 score in the BAC group ($r = 0.78$, $p < 0.01$) (Figure 1). There was also a strong positive correlation between OSDI and GQL-15 score in the BAC-free group ($r = 0.64$, $p < 0.01$) (Figure 2). There was a highly significant, strong positive correlation between OSDI score and GQL-15 score among controls ($r = 0.58$, $p < 0.001$). Table 3 shows the correlation between OSDI and GQL-15 scores in the 3 groups.

Discussion

The purpose of glaucoma treatment is to maintain the patient's visual function and its related QoL. Glaucoma patients' QoL can be considerably affected by the side effects of long-term use of antiglaucoma drugs.^{14,16} The present study confirmed that more severe OSD (higher OSDI scores) had a strong correlation with worse QoL (higher GQL-15 scores) in patients on BAC-preserved prostaglandins and less severe OSD (lower OSDI

scores) had strong correlation with better QoL (lower GQL-15 scores) in patients on BAC-free prostaglandins.

As a preservative, BAC has detergent-like activity which has a propensity to compromise the tear film and induce or worsen pre-existing OSD.¹⁹ The prevalence of ocular symptoms such as discomfort upon instillation, burning/stinging, foreign body

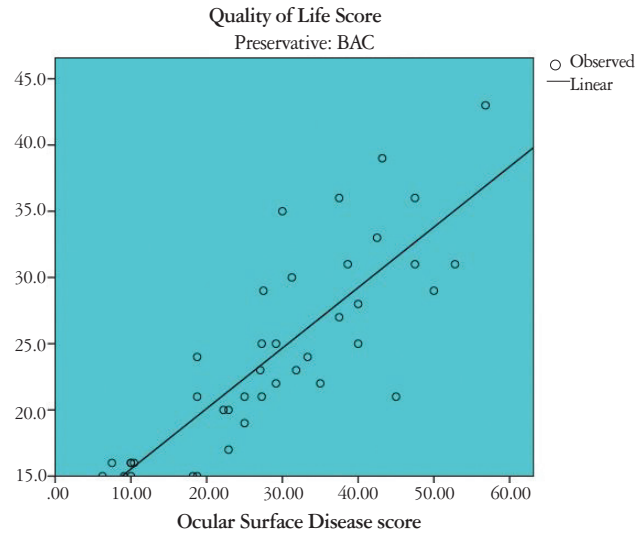


Figure 1. Scatter diagram showing correlation between Ocular Surface Disease index (OSDI) score and Glaucoma Quality of Life-15 (GQL-15) score in the BAC group

Table 1. Comparison of mean GQL-15 scores

Preservative	Quality of life score mean \pm SD	Mean difference	95% confidence interval for mean		p value
			Lower bound	Upper bound	
Controls (N=30)	16.33 \pm 1.92	Baseline			
BAC-free (N=40)	17.58 \pm 3.06	1.24	1.67	4.15	0.90
BAC (N=40)	24.25 \pm 7.42	7.92	5.01	10.82	<0.01
BAC-free (N=40)	17.58 \pm 3.06	Baseline			
BAC (N=40)	24.25 \pm 7.42	6.68	3.98	9.37	<0.01

GQL-15: Glaucoma Quality of Life-15 questionnaire, SD: Standard deviation, BAC: Benzalkonium chloride

Table 2. Comparison of mean OSDI scores

Preservative	Ocular surface disease score mean \pm SD	Mean difference	95% confidence interval for mean		p value
			Lower bound	Upper bound	
Controls (N=30)	10.93 \pm 7.36	Baseline			
BAC-free (N=40)	12.45 \pm 5.08	1.53	-4.04	7.10	1.00
BAC (N=40)	29.09 \pm 13.45	18.96	12.59	23.73	<0.01
BAC-free (N=40)	12.45 \pm 5.08	Baseline			
BAC (N=40)	29.09 \pm 13.45	16.63	11.47	21.79	<0.01

GQL-15: Glaucoma Quality of Life-15 questionnaire, SD: Standard deviation, BAC: Benzalkonium chloride

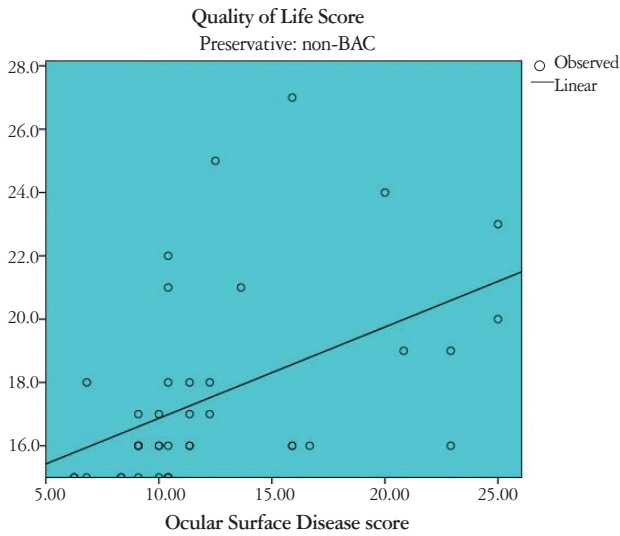


Figure 2. Scatter diagram showing correlation between Ocular Surface Disease index (OSDI) score and Glaucoma Quality of Life-15 (GQL-15) score in the BAC-free group

Table 3. Correlation between OSDI and GQL-15 scores in the study groups		
Study group	Estimate	p value
Correlation coefficient		
Control	0.58	<0.001
BAC-free	0.64	0.01
BAC	0.78	<0.001
GQL-15: Glaucoma Quality of Life-15 questionnaire, BAC: Benzalkonium chloride		

sensation, dry eye sensation, and tearing have been found to be more prevalent with BAC-preserved than with unpreserved antiglaucoma drugs ($p < 0.001$).²⁰ Switching from BAC-preserved to BAC-free medication led to a decrease in OSD in previous studies.^{21,22} In our study, the incidence of OSD (OSDI scores more than 12) was significantly higher in the BAC group than in the BAC-free group (82.5% versus 32.5%), similar to other studies. BAC is known to cause corneal toxicity and has a deleterious effect on TBUT.

In our study, there was a statistically strong correlation between OSDI scores and QoL scores among all the study groups. Mean QoL scores (16.1 ± 2.3) on the GQL-15 questionnaire were found to be lower in patients having no OSD (OSDI score < 12), whereas mean QoL scores (21.2 ± 10.4) were found to be higher in patients having OSD (OSDI scores more than 12). The increase in mean QoL scores in patients with higher OSDI scores signifies lower QoL in these patients.

In our study, BAC-preserved antiglaucoma medication was associated with higher OSDI scores (18.72 ± 7.04), which strongly correlated with poorer QoL (24.25 ± 7.42) in these patients. In contrast, the use of BAC-free antiglaucoma medication was

associated with lower OSDI scores (11.2 ± 5.15), which correlated strongly with better QoL (17.58 ± 3.06) in these patients. The study by Skalicky et al.¹⁴ showed a positive correlation between OSDI scores and QoL in glaucoma patients, similar to our study. Similarly, Rossi et al.¹⁸ concluded in their study that the presence of dry eye disease as assessed by the OSDI negatively influences the patient's QoL. Glaucoma is known to adversely affect QoL and the presence of concomitant OSD further worsens QoL in these patients.

The mean QoL score in the BAC group (24.25 ± 7.42) was significantly higher than in the BAC-free group (17.58 ± 3.06 , $p < 0.05$), indicating poorer QoL in these patients. The worsened QoL can be attributed to the presence of more severe OSD in the BAC-preserved (18.72 ± 7.04) versus the BAC-free group (11.2 ± 5.15 ; $p < 0.001$). Previous studies have documented higher incidence of OSD with use of BAC-containing antiglaucoma medications,^{20,21} while BAC-free medications which incorporate safer preservatives such as polyquaternium-1 (Polyquad[®]) were shown to reduce the incidence and severity of OSD.^{15,16} In a prospective study, Lester et al.²³ used the GSS and found that changing BAC-preserved antiglaucoma drugs with BAC-free treatment improved QoL in glaucoma patients. In another prospective study by Abegao et al.¹⁷ using the same questionnaire (GSS), it was found that switching to BAC-free antiglaucoma drugs significantly improved self-reported QoL in glaucoma patients ($p < 0.001$). Both of these studies used the GSS, which does not take into account the symptoms related to glare and peripheral vision.²⁴ Therefore, it may underestimate difficulty experienced by patients in their day-to-day activities, especially driving at night. Our study found the BAC-free formulation to be superior to the BAC-preserved formulation in improving OSD-related QoL in glaucoma patients. We found that domains involving night vision on GQL-15 strongly correlated with QoL in these patients. GQL-15 has been shown to strongly correlate with both visual disability and psychophysical measures of visual functions. This is the first study to use the GQL-15 questionnaire for comparing QoL in BAC-preserved and BAC-free antiglaucoma medication.

In our study, the BAC-preserved group showed significantly higher QoL scores ($p < 0.05$) than controls, indicating worse QoL in these patients. Similarly, Skalicky et al.¹⁴ in their study found that increasing glaucoma severity and higher exposure to BAC was associated with poorer QoL compared to controls ($p < 0.001$). Another study using the Dry Eye Questionnaire 5 (DEQ5) and the Impact of Dry Eye on Everyday Life (IDEEL) questionnaire concluded that a greater number of glaucoma medications was associated with increased frequency of severe dry eye symptoms and decreased emotional QoL.²⁵ In our study, we found that use of BAC-preserved antiglaucoma medication increased OSDI scores and led to lower QoL in glaucoma patients. However, the patients in our study were on monotherapy as opposed to multiple drugs in the previous study. These symptoms can have a substantial impact on a patient's QoL. Our study proves that the use of BAC-preserved antiglaucoma drugs is associated with more severe OSD, which leads to worsened QoL in these patients.

There is paucity of literature which compares QoL in patients receiving BAC-free antiglaucoma drugs with controls. Rolle et al.²⁶ recently reported that patients using unpreserved tafluprost and unpreserved timolol had significantly worse OSDI and QoL scores than controls ($p=0.000$), thereby implying the possible role of the active ingredient in reducing QoL in these patients. However, in our study QoL was found to be statistically similar in the BAC-free and control groups. Therefore, from our study it is evident that QoL was not significantly affected by BAC-free topical medications. OSD-related poor QoL in glaucoma patients can be largely attributed to BAC, and the use of BAC-free prostaglandins has the potential to improve QoL in these patients.

Study Limitations

One limitation in the design of the present study was that it was a non-randomized study, which may have resulted in selection bias. We included patients exclusively with mild to moderate glaucoma and hence comparison of QoL could not be made between different grades of glaucoma severity. Our data relies on patient-reported surveys which can be influenced by recall bias. The strong points of our study are that we used valid, reliable, and disease-specific instruments like GQL-15 and OSDI questionnaires for all patients and the questionnaires were administered by a single interviewer, thus eliminating personal bias. Our study had a good sample size that included an adequate number of patients in all the study groups.

Conclusion

There is a strong correlation between OSD and QoL in medically treated glaucoma patients. The increasing severity of OSD correlated with worsening of QoL. BAC-preserved prostaglandins were associated with significantly higher OSD and worse QoL in glaucoma patients compared to BAC-free travoprost. Patients using BAC-free travoprost had statistically similar OSD and glaucoma-related QoL to controls. Therefore, shifting to BAC-free antiglaucoma medication is recommended for improving OSD-related QoL in these patients.

Ethics

Ethics Committee Approval: The present research study was registered with the clinical trial registry of India, CTRI (CTRI/2017/12/011044CTRI) and was approved by the institutional ethics committee.

Informed Consent: The subjects found to fulfill all the inclusion criteria were asked to provide written informed consent.

Peer-review: Externally peer-reviewed.

Authorship Contributions

Analysis or Interpretation: S.K., T.S., P.I., S.V., S.T., Literature Search: S.K., T.S., P.I., S.V., S.T., Writing: S.K., T.S., P.I., S.V., S.T.

Conflict of Interest: No conflict of interest was declared by the authors.

Financial Disclosure: The authors declared that this study received no financial support.

References

1. Salehi A, Harris N, Sebar B, Coyne E. Self-Perception of Quality of Life and Its Association with Lifestyle Behaviours of Young Iranian Women. *Iranian Journal of Public Health*. 2015;44:332-340.
2. Leung EW, Medeiros FA, Weinreb RN. Prevalence of ocular surface disease in glaucoma patients. *J Glaucoma*. 2008;17:350-355.
3. Kanamoto T, Kiuchi Y, Tanito M, Mizoue S, Naito T, Teranishi S, Hirooka K, Rimayanti U; Ocular Surface Disease and Glaucoma Study Group. *J Ocul Pharmacol Ther*. 2015;31:156-164.
4. Cucherat M, Stalmans I, Rouland JF. Relative efficacy and safety of preservative-free latanoprost (T2345) for the treatment of open-angle glaucoma and ocular hypertension: an adjusted Indirect comparison meta-analysis of randomized clinical trials. *J Glaucoma*. 2014;23:69-75.
5. Barisic F, Krolo I, Popovic- Suic S, Sesar I, Simic- Prskalo M, et al. Prevalence of Ocular Surface Disease in Patients with Glaucoma using Topical Antiglucoma Medications. *J Clin Exp Ophthalmol*. 2014;5:334.
6. Rasmussen CA, Kaufman PL, Kiland JA. Benzalkonium Chloride and Glaucoma. *Journal of Ocular Pharmacology and Therapeutics*. 2014;30:163-169.
7. Walt J, Rowe M, Stern K. Evaluating the functional impact of dry eye: the Ocular Surface Disease Index (Abstract). *Drug Inf J*. 1997;31:1436.
8. Schiffman RM, Christianson MD, Jacobsen G, Hirsch JD, Reis BL. Reliability and validity of the Ocular Surface Disease Index. *Arch Ophthalmol*. 2000;118:615-621.
9. Cvenkel B, Stunf S, Srebotnik Kirbis I, Strojjan Flezar M. Symptoms and signs of ocular surface disease related to topical medication in patients with glaucoma. *Clinical Ophthalmology*. 2015;9:625-631.
10. Saade CE, Lari HB, Berezina TL, Fechtner RD, Khouri AS. Topical glaucoma therapy and ocular surface disease: a prospective, controlled cohort study. *Can J Ophthalmol*. 2015;50:132-6.
11. Nelson P, Aspinall P, Papanoulitis O, Worton B, O'Brien C. Quality of life in glaucoma and its relationship with visual function. *J Glaucoma*. 2003;12:139-150.
12. Lee BL, Gutierrez P, Gordon M, et al. The Glaucoma Symptom Scale. A brief index of glaucoma-specific symptoms. *Arch Ophthalmol*. 1998;116:861-866.
13. Mitchell J, Bradley C. Design of an individualized measure of the impact of macular disease on quality of life (the MacDQoL). *Qual Life Res*. 2004;13:1163-1175.
14. Simon E, Skalicky, Ivan Goldberg, and Peter Mc Cluskey. Ocular surface disease and quality of life in patients with glaucoma. *Am J Ophthalmol*. 2012;153:1-9.
15. Ammar DA, Noecker RJ, Kahook MY. Effects of benzalkonium chloride-preserved, polyquad-preserved, and sofZia-preserved topical glaucoma medications on human ocular epithelial cells. *Adv Ther*. 2010;27:837-845.
16. J Charles Henry, James H Peace, Jeanette A Stewart, et al. Ocular Surface disease in patients with Glaucoma or Ocular Hypertension, treated with either BAK-preserved latanoprost or BAK-free travoprost. *Clinical Ophthalmology*. 2010;4:1253-1261.
17. Abegão Pinto L, Vandewalle E, Gerlier L, Stalmans I. The CosoptUD Switch Study Group. Improvement in Glaucoma Patient Quality of Life by Therapy Switch to Preservative-Free Timolol/Dorzolamide Fixed Combination. *Ophthalmologica*. 2014;231:166-171.
18. Rossi GC, Tinelli C, Pasinetti GM, Milano G, Bianchi PE. Dry eye syndrome-related quality of life in glaucoma patients. *Eur J Ophthalmol*. 2009;19:572-579.
19. Kaštelan S, Tomic M, Metez Soldo K, Salopek-Rabatic J. How Ocular Surface Disease Impacts the Glaucoma Treatment Outcome. *BioMed Research International*, 2013, 696328. <http://doi.org/10.1155/2013/696328>.

20. Pisella PJ, Pouliquen P, Baudouin C. Prevalence of ocular symptoms and signs with preserved and preservative free glaucoma medication. *British J Ophthalmol* 2002;86:418-423.
21. Saade CE, Lari HB, Berezina TL, Fechtner RD, Khouri AS. Topical glaucoma therapy and ocular surface disease: a prospective, controlled cohort study. *Can J Ophthalmol*. 2015;50:132-136.
22. Pérez-Bartolomé F, Martínez-de-la-Casa , Arriola-Villalobos P, Fernández-Pérez C, Polo V, García-Feijó J. Ocular surface disease in patients under topical treatment for glaucoma. *Eur J Ophthalmol*. 2017;10:0.
23. Iester M, Telani S, Frezzotti P, Motolese I, Figus M, Fogagnolo P, Perdicchi A; Beta-Blocker Study Group. *J Ocul Pharmacol Ther*. 2014;30:476-481.
24. Lee BL, Gutierrez P, Gordon M, Wilson MR, Cioffi GA, Ritch R, Sherwood M, Mangione CM. The Glaucoma Symptom Scale. A Brief Index of Glaucoma-Specific Symptoms. *Arch Ophthalmol*. 1998;116:861-866.
25. Camp A, Wellik S R, Tzu, J H, Feuer W, Arheart K L, Sastry A, Galor A. (). Dry eye specific quality of life in veterans using glaucoma drops. *Contact Lens & Anterior Eye : The Journal of the British Contact Lens Association*. 2015;38:220-225.
26. Rolle T, Spinetta R, Nuzzi R. Long term safety and tolerability of Tafluprost 0.0015% vs Timolol 0.1% preservative-free in ocular hypertensive and in primary open-angle glaucoma patients: a cross sectional study. *BMC Ophthalmology*. 2017;17:136.



The Effect of Inferior Oblique Muscle Z-Myotomy in Patients with Primary Inferior Oblique Overaction

Hasan Kızıltoprak*, Hakan Halit Yaşar**, Kemal Tekin***

*Bingöl Women's Health and Children's Hospital, Department of Ophthalmology, Bingöl, Turkey

**Ulucanlar Eye Training and Research Hospital, Clinic of Ophthalmology, Ankara, Turkey

***Erciş State Hospital, Clinic of Ophthalmology, Van, Turkey

Abstract

Objectives: To investigate the surgical results of the inferior oblique muscle Z-myotomy in patients with inferior oblique muscle overaction (IOOA).

Materials and Methods: The medical records of patients who had undergone inferior oblique muscle Z-myotomy for primary IOOA in a single center between 2017 and 2018 were retrospectively analyzed. All patients had mild IOOA (+1 and between +1 and +2). Preoperative and postoperative IOOA degrees and ocular motility examinations were evaluated. Inferior oblique muscle Z-myotomy is performed at 6 mm along the physiological muscle line after identifying the lower oblique muscle through an inferotemporal fornix incision.

Results: Forty-seven eyes of 44 patients were included in the study. The patients were divided into those with +1 IOOA (n=37, 78.7%) and those with +1-2 IOOA (n=10, 21.3%). The mean age of the +1 group was 14.18±11.8 years and the mean age of the +1-2 group was 13.40±7.45 years. The mean follow-up time was 10.56±8.7 (6-17) months. Bilateral Z-myotomy was performed in 3 (6.8%) and unilateral in 41 (93.2%) of the patients. IOOA correction was observed in 43 (91.4%) of the 47 eyes after Z-myotomy, while 4 (8.6%) eyes still had preoperative levels of IOOA. There was no statistically significant difference in surgical success rate between the groups (p=0.849). When preoperative and postoperative IOOA values were compared, there was a statistically significant decrease in IOOA values in the postoperative period (p=0.001). No intraoperative or postoperative complications were observed.

Conclusion: Inferior oblique Z-myotomy is a simple, fast, sutureless surgical procedure in which the original muscle insertion is preserved. Z-myotomy of the inferior oblique muscle can be used as a successful attenuation method in patients with minimal IOOA.

Keywords: Inferior oblique muscle overaction, surgical results, Z-myotomy

Introduction

Inferior oblique muscle overaction (IOOA) is a common eye movement disorder characterized by excessive elevation of the adducted eye.¹ IOOA is etiologically and clinically evaluated under two headings, primary and secondary.² Primary IOOA is a condition of unknown etiology and is not associated with paralysis of any muscle. Secondary IOOA occurs as a result of

paralysis of the superior oblique or contralateral superior rectus muscle of the same eye.³

In IOOA, the diplopia that occurs due to hyperdeviation and the unaesthetic upward deviation of the eye on adduction make the patient uncomfortable and are an indication for surgery.^{3,4} Regardless of etiological differences, surgical treatment of both primary and secondary IOOA is based on the principle of reducing muscle function. Depending on the surgeon's experience and

Address for Correspondence: Hasan Kızıltoprak, Bingöl Women's Health and Children's Hospital, Department of Ophthalmology, Bingöl, Turkey

Phone:+90 538 675 65 28 E-mail: hsnkzltprk21@gmail.com **ORCID-ID:** orcid.org/0000-0001-7100-9107

Received: 14.02.2019 **Accepted:** 25.12.2019

Cite this article as: Kızıltoprak H, Yaşar HH, Tekin K. The Effect of Inferior Oblique Muscle Z-Myotomy in Patients with Primary Inferior Oblique Overaction. Turk J Ophthalmol. 2020;50:82-86

preference, the procedures most commonly used in the operation are inferior oblique muscle recession, anteriorization, tenotomy, and myectomy.^{5,6,7,8} In patients with low-grade (between +1 and +1-2) IOOA, one alternative is Z-myotomy, an extraocular muscle weakening procedure performed by making two incisions in the longitudinally opposing margins of an extraocular muscle.⁹ The few published articles on the results of Z-myotomy have reported positive outcomes.^{9,10}

The objective of this study was to evaluate the effectiveness of Z-myotomy surgery performed at our clinic to correct isolated primary IOOA.

Materials and Methods

The study protocol was approved by the Ankara Numune Training and Research Hospital Ethics Committee and the study was carried out in accordance with the Declaration of Helsinki. The medical records of patients who underwent Z-myotomy for primary IOOA at Ulucanlar Ophthalmology Training and Research Hospital between January 2017 and June 2018 were evaluated retrospectively. As per routine protocol, the possible risks of surgery were explained to patients and informed consent forms were obtained preoperatively.

After history was taken, all patients underwent ophthalmologic examination including detailed strabismus examination. All patients were evaluated pre- and postoperatively for presence of A-V pattern and horizontal and vertical deviations with and without glasses. As described previously by Del Monte and Parks¹¹, IOOA was graded as +1, +2, +3, and +4 for angles of excess elevation of the adducted eye of 5°, 10°, 15°, and 20°, respectively, when the fixating eye was at 30 degrees of abduction and 20 degrees of elevation. This classification is shown in Figure 1.¹² Surgical indication was determined for patients with minimal IOOA but significant V pattern (>15 PD), bilateral cases with asymmetric deviation of one eye between +1 and +1-2, and patients who requested IOOA below +2 to be treated during horizontal surgery. Z-myotomy surgery was planned for patients who had IOOA meeting these criteria (between +1 and +1-2). None of the patients included in the study had history of any previous eye surgery. Figure 2 shows the preoperative appearance of a patient with bilateral IOOA and V pattern.

In the Z-myotomy technique, the inferior oblique muscle was accessed via inferotemporal fornix incision, isolated with a hook, and stretched between two hooks (Figures 3a-c). Two clamps were placed at opposite ends of the muscle so as to cover approximately 75% of the muscle belly. Thus, the middle 50% of the muscle belly was isolated between the two clamps (Figure 3d). The first clamp was placed 7-8 mm from the muscle insertion and the second clamp 10 mm from the first clamp (Figure 3d). Using Wescott scissors, the muscle was cut from the margin to the middle of its horizontal section at two points 4-6 mm apart in the direction of blood flow from the clamps (closer to the insertion) in order to optimize hemostasis (Figure 3e-i). The cut edges of the muscle were then cauterized using

low-temperature heat cautery. The conjunctiva was closed with individual 8.0 sutures (Figure 3j). An epinephrine and lidocaine mixture was administered by sub-Tenon's injection, and topical antibiotic and anti-inflammatory agents were instilled. All operations were performed by a single surgeon (H.H.Y.).

Patients were followed-up at 1 day, 1 week, 1 month, and 6 months after surgery, and every 6 months thereafter. Criteria for success were complete elimination of IOOA and resolution of the hyperdeviation upon inferior oblique movement. Persistence of hyperdeviation in primary gaze and IOOA on adduction was considered failure.

Statistical Analysis

In statistical analysis, arithmetic mean \pm standard deviation values were calculated for each variable. Surgical success was compared between the groups (+1/+1-2) using chi-square test. A p value less than 0.05 was considered statistically significant.

Results

Forty-seven eyes of 44 patients were evaluated in the study. Of the patients included in the study, 26 (59%) were male and 18 (41%) were female. The patients were divided into two groups, the +1 group and the +1-2 group. IOOA grade was +1 in 37 patients (78.7%) and between +1 and +2 in 10 patients (21.3%). Mean age was 14.18 ± 11.8 (4-55) years in the +1 group and 13.40 ± 7.45 (5-33) years in the +1-2 group. The mean follow-up time of the patients was 10.56 ± 8.7 (6-17) months. Three patients (6.8%) underwent bilateral Z-myotomy and 41 (93.2%) underwent unilateral Z-myotomy.

IOOA improved after surgery in 43 (91.4%) of the 47 eyes that underwent Z-myotomy, while IOOA remained at the preoperative level in 4 (8.6%) eyes. Of the 4 patients with failed surgery, 3 were in the +1 group and 1 was in the +1-2 group. Postoperative success rate did not differ significantly between the groups ($p=0.849$). Mean preoperative and postoperative IOOA grades were $+1.15 \pm 0.13$ and 0.12 ± 0.20 , respectively ($p=0.001$). No intra- or postoperative complications were observed. Figure 4 shows postoperative correction of IOOA in the patient whose preoperative image is shown in Figure 2.

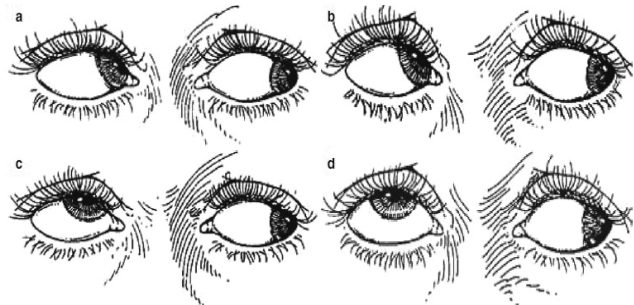


Figure 1. Assessment of inferior oblique overaction severity. When the fixated eye is in abduction, 5° of excessive elevation of the eye in adduction was evaluated as +1 (a), 10° as +2 (b), 15° as +3 (c), and 20° as +4 (d)

Discussion

Treating small-angle but symptomatic hypertropias is challenging. Because surgical methods performed in these patients (inferior oblique muscle recession, anteriorization, tenotomy, and myectomy) can result in excessive or insufficient correction, satisfactory outcomes may not always be achieved. There have been few publications to date on the effect of Z-myotomy of the inferior oblique muscle performed for mildly symptomatic IOOA. The results of our study demonstrated that Z-myotomy performed as surgical treatment for mild IOOA is quite successful.

The main goal of procedures used in the treatment of IOOA, such as recession, anteriorization, tenotomy, myectomy, and muscle extirpation-denervation, is to weaken the inferior oblique muscle.^{13,14} Superiority studies comparing these methods have shown that all are similarly effective and no method is significantly superior to the others.¹⁵

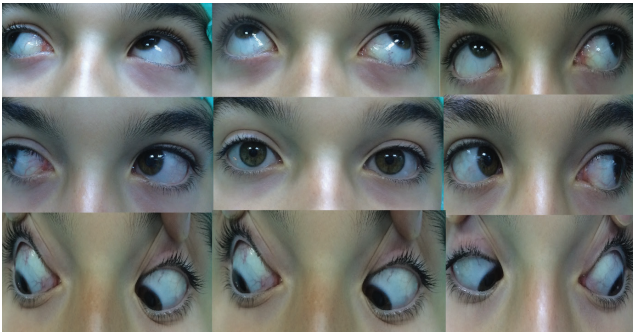

Figure 2. Preoperative appearance of a patient with bilateral IOOA and V pattern

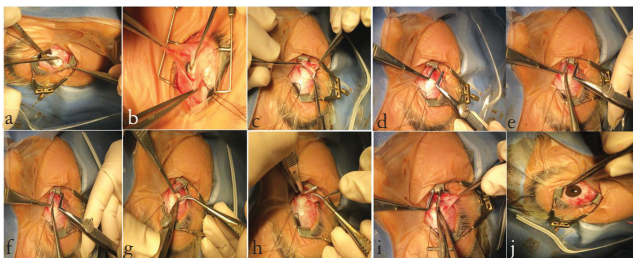


Figure 3. In Z-myotomy, the inferior oblique muscle is accessed via inferotemporal fornx incision, isolated with a hook, and stretched between two hooks (a, b, c). Two clamps are placed at opposite ends of the muscle to cover approximately 75% of the muscle belly and isolate the middle 50% of the muscle belly between the two clamps (d). The first clamp is placed 7-8 mm from the muscle insertion and the second clamp 10 mm from the first clamp (d). Using Wescott scissors, the muscle is cut from the margin to the middle of its horizontal section at two points 4-6 mm apart in the direction of blood flow from the clamps (closer to the insertion) to optimize hemostasis (e-i). The cut muscle margins are cauterized using low-temperature heat cautery. The conjunctiva is closed with individual 8.0 sutures (j)

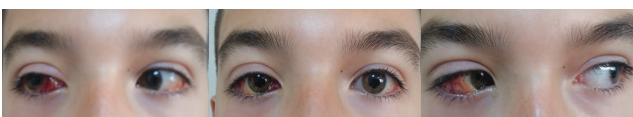

Figure 4. IOOA correction is observed in postoperative examination of the patient shown in Figure 2

IOOA: Inferior oblique muscle overaction

After tenotomy or myectomy, the inferior oblique muscle may exhibit random adhesion to the sclera in the retroequatorial region, which can cause excessive or insufficient correction.^{8,16,17} In revision operations performed to treat this excessive or insufficient correction, the inferior oblique muscle cannot be isolated again as a whole single muscle due to the fibers adhering at different places to the sclera, and a substantial proportion of revision operations fail for this reason.^{8,13,17} Based on our observations, excessive or insufficient correction is relatively less frequent with recession and anteriorization because the inferior oblique muscle is sutured adjacent to the insertion of the inferior rectus muscle. Furthermore, the fact that the muscle is whole and in a known position facilitates reisolation of the muscle and recorection in patients undergoing revision due to excessive or insufficient correction. Therefore, recession or anteriorization are preferred over tenotomy or myectomy.^{13,18} However, in revision operations performed after these methods, it is observed that the inferior oblique muscle is surrounded by a denser fibrotic tissue compared to previously recessed horizontal muscles.¹⁷ This may cause difficulty separating the muscle from the sclera in some cases. Because these methods can also result in excessive or insufficient correction and due to the aforementioned difficulty in revision operations, the Z-myotomy method (in which the inferior oblique muscle is not detached from its insertion) may be an alternative to tenotomy and myectomy for mild cases of IOOA.

The practice of performing Z-myotomy on the inferior oblique muscle was introduced in 1973 by De Decker and Kueper¹⁹ with a technique similar to that used today. Mellott et al.²⁰ later performed this procedure on 10 patients with mild IOOA and achieved successful outcomes. Similar results were also reported in subsequent studies.

Inferior oblique Z-myotomy has become particularly popular in the treatment of mild IOOA in recent years. This technique has many advantages over other methods.^{9,10} Inferior oblique Z-myotomy is a short surgical procedure that is relatively easy to perform. As it does not require any suturing to the sclera, the risk of scleral perforation or vortex vein damage is low. In addition, the original insertion of the muscle is not altered in this surgery.^{9,10,21,22} It was recently emphasized that inferior oblique Z-myotomy is a technically easy, complication-free, and effective surgical procedure for patients with primary and secondary IOOA.^{9,10} We achieved a 91.4% success rate in patients with mild but symptomatic primary IOOA who underwent Z-myotomy and were followed in our center. In 8.6% of our patients, the same degree of IOOA persisted after surgery. Excessive correction or other complications did not occur in any of our patients. No recurrence was observed during the follow-up period of approximately 6 months. These results demonstrate the success of this procedure when used to treat small-angle deviations.

Z-myotomy or marginal myotomy can also be performed on the horizontal rectus muscles. While this method is occasionally

preferred for small-angle horizontal deviations as well, its main indication is for achieving extra attenuation in maximally recessed horizontal rectus muscles. The muscle is weakened by reducing the number of contractile elements in the muscles without changing their arc of contact with the globe. Other indications for the practice of this method on the rectus muscles include eyes with an extremely thin sclera, implants, explants, and cerclage bands placed after retinal detachment surgery.^{23,24}

It has been reported that inferior oblique Z-myotomy can also be safely used in the treatment of patients with accompanying horizontal deviations.^{9,15} In such cases, it was stated that Z-myotomy can be performed to correct small-angle IOOA accompanying horizontal deviations and that there is no need to change the planned horizontal deviation surgery.^{9,25} Because our study was conducted on patients with isolated IOOA, the effect of Z-myotomy on horizontal deviation could not be evaluated.

Moreover, in asymmetric bilateral cases, successful outcomes were also reported with inferior oblique Z-myotomy performed on the side of lower severity.^{9,13} In our series, all 3 patients with bilateral IOOA showed asymmetry. We performed bilateral Z-myotomy for this reason and observed successful correction of the IOOA on both sides. Therefore, we can conclude that bilateral inferior oblique Z-myotomy is also successful in mild cases with different degrees of IOOA.

The main limitations of this study are the retrospective design and the fact that we did not make a comparison with other surgical procedures. In addition, our study group was small and for this reason we cannot generalize the results. However, inclusion of only patients with isolated IOOA enabled a better assessment of the outcomes of this procedure and is the strength of our study.

Conclusion

In conclusion, inferior oblique Z-myotomy is an easy-to-perform, complication-free, successful surgical technique for the treatment of patients with low-grade (between +1 and +1-2) IOOA. For small-angle but symptomatic cases, this method may be preferable to recession and myectomy, which can lead to excessive correction. The effect of changing the distance of incisions made in the inferior oblique muscle, the distance between incision and insertion, or the depth of the incision in lower or higher degree deviations during this surgical procedure may inspire future studies.

Ethics

Ethics Committee Approval: The study protocol was approved by the Ankara Numune Training and Research Hospital Ethics Committee and the study was carried out in accordance with the Declaration of Helsinki.

Informed Consent: As per routine protocol, the possible risks of surgery were explained to patients and informed consent forms were obtained preoperatively.

Peer-review: Externally peer reviewed.

Author Contributions

Concept: H.K., Design: H.K., K.T., Data Collection or Processing: H.K., H.H.Y., Analysis or Interpretation: H.K., H.H.Y., K.T., Literature Search: H.K., K.T., Manuscript writing: H.K.

Conflict of Interest: The authors declare no conflicts of interest.

Financial Disclosure: The authors report receiving no financial support.

References

1. Yılmaz SG, Üretmen Ö, Köse S. Primer alt oblik kas hiperfonksiyonunun tedavisinde dezensasyon, geriletme ve miyektomi yöntemlerinin karşılaştırılması. *T Klin Oftalmol.* 2009;18:113-118.
2. Kargı SH, Özal H, Koç F, Fırat E. Primer ve sekonder alt oblik hiperfonksiyonunda alt oblik kas miyektomisi sonuçlarımız. *T Klin Oftalmoloji.* 2001;10:121-127.
3. Aydemir O, Turgut B. Primer alt oblik kas hiperfonksiyonunun tedavisinde miyektomi yönteminin sonuçları. *MN Oftalmol.* 2010;17:98-101.
4. Brodsky MC, Donahue SP. Primary oblique muscle overaction: the brain throws a wild pitch. *Arch Ophthalmol.* 2001;119:1307-1314.
5. Sanjari MS, Shahraki K, Nekoozadeh S, Tabatabaee SM, Shahraki K, Aghdam KA. Surgical treatments in inferior oblique muscle overaction. *J Ophthalmic Vis Res.* 2014;9:291-295.
6. Can İ, Önder F, Koçak P, Kural C. İnförör oblik kas myektomisi: Etkinliğinin ve komplikasyonlarının değerlendirilmesi. *MN Oftalmoloji.* 1995;2:160-164.
7. Kulaçoğlu Destan N, Baykal O, Koçer İ, Dursun O. Primer İnförör Oblik Hiperfonksiyonlu Olgulardaki İnförör Oblik Miyektomisi Sonuçlarımız. *T Klin J Ophthalmol.* 2000;9:38-43.
8. Altıntaş AK, Nurözler A, Demirci S, Kasım R, Duman S. Primer ve sekonder inferior oblik kas hiperfonksiyonunda unilaterale ve bilaterale tenotomi. *T Oft Gaz* 1994;24:480-483.
9. Cruz FC, Robbins SL, Kinori M, Acera EC, Granet DB. Z-myotomy of the inferior oblique for small incommittant hypertropias. *J AAPOS.* 2015;19:130-134.
10. Lee SY, Cho HK, Kim HK, Lee YC. The effect of inferior oblique muscle Z myotomy in patients with inferior oblique overaction. *J Pediatr Ophthalmol Strabismus.* 2010;47:366-372.
11. Del Monte MA, Parks MM. Denervation and extirpation of the inferior oblique. An improved weakening procedure for marked overaction. *Ophthalmology.* 1983;90:1178-1185.
12. K.W. Wright, Y.N.J. Strube, inferior oblique muscle weakening procedures, *Color Atlas Of Strabismus Surgery: Strategies and Techniques*, Springer, 4th edition, New York, 2015, 136.
13. Stager D Jr, Dao LM, Felius J. Uses of the Inferior Oblique Muscle in Strabismus Surgery. *Middle East Afr J Ophthalmol.* 2015; 22:292-297.
14. Kocabeyoğlu S, Sanaç AŞ, Şener EC. Siklovertikal Kaymalarda Cerrahi Sonuçlar. *Turk J Ophthalmol.* 2012;42:38-42.
15. Sieck EG, Jung JL, Singh JK. Comparison of surgical approaches to inferior oblique overaction. *J AAPOS.* 2018;22:46-47.
16. Arici MK, Topalkara A, Güler C. Alt oblik kasi hiperfonksiyonunda tenotomi sonuçlarımız. *T Klin Oftalmol.* 1999;8:22-25.
17. Koc F. Surgical exploration in persistent inferior oblique overactions. *Int Ophthalmol.* 2017;37:1319-1322.
18. Alajbegovic-Halimic J, Zvizdic D, Sahbegovic-Holcner A, Kulanic-Kuduzovic A. Recession Vs Myotomy-Comparative Analysis of Two Surgical Procedures of Weakening Inferior Oblique Muscle Overaction. *Med Arch.* 2015;69:165-168.
19. De Decker W, Kueper J. Inferior oblique weakening by marginal myotomy: thermo-electric weakening. *Ann Ophthalmol.* 1973;5:605-609.
20. Mellott ML, Scott WE, Ganser GL, Keech RV. Marginal myotomy of the minimally overacting inferior oblique muscle in asymmetric bilateral superior oblique palsies. *J AAPOS.* 2002;6:216-220.

21. Almeida HC, Alvares MA. Split lengthening of the inferior oblique muscles. *Graefes Arch Clin Exp Ophthalmol.* 1988;226:181-182.
22. Chang BL, Yang SW. Inferior oblique overaction. *Korean J Ophthalmol.* 1988;2:77-81.
23. Sanac AS, Sener EC. Şaşılık ve Tedavisi. Ankara: Pelin Ofset ve Tipo Matbaacılık. 2. baskı, 2001;247.
24. von Noorden GK, Campos EC. *Binocular Vision and Ocular Motility.* St Louis: Mosby 6th ed., 2002:579;597-598.
25. Minguini N, Dantas FJ, Monteiro de Carvalho KM, Moreira-Filho DC. A study to determine: should conventional amounts of eye muscle surgery for horizontal binocular deviations be changed when oblique muscle weakening procedures are simultaneously performed? *Binocul Vis Strabismus Q.* 2005;20:21-25.



Can Complete Blood Count Parameters Predict Retinopathy of Prematurity?

İ Ayşe İpek Akyüz Ünsal*, İ Özge Key*, İ Duygu Güler*, İ İmran Kurt Omurlu**, İ Ayşe Anık***, İ Buket Demirci****, İ Sema Dünder*

*Aydın Adnan Menderes University Faculty of Medicine, Department of Ophthalmology, Aydın, Turkey

**Aydın Adnan Menderes University Faculty of Medicine, Department of Biostatistics, Aydın, Turkey

***Aydın Adnan Menderes University Faculty of Medicine, Department of Pediatrics Neonatology Division, Aydın, Turkey

****Aydın Adnan Menderes University Faculty of Medicine, Department of Medical Pharmacology, Aydın, Turkey

Abstract

Objectives: To predict the risk of retinopathy of prematurity (ROP) development according to routine complete blood count (CBC) parameters.

Materials and Methods: The medical records and CBC results of 150 premature neonates were retrospectively evaluated. As ROP develops 1 month after birth, first month CBC profiles of neonates without ROP (non-ROP), with ROP (ROP group), and those with Type 1, Type 2, and Stage 1+2 ROP were compared. Besides known statistical methods like Student's t-test, logistic regression and classification & regression tree (C&RT) analysis were also done to identify a reliable quantitative predictive parameter.

Results: Mean gestational age and birth weight of the ROP group (n=99) and non-ROP (n=43) group were 29.39 ± 3.43 and 32.05 ± 2.20 weeks and 1382.44 ± 545.30 and 1691.51 ± 360.84 grams, respectively ($p < 0.001$, $p < 0.001$). Average hemoglobin (Hb) ($p < 0.001$), hematocrit (HCT) ($p < 0.001$), erythrocyte ($p = 0.005$), mean corpuscular hemoglobin (MCH) ($p = 0.020$), and MCH concentration ($p = 0.019$) values of the ROP group were lower than those of the non-ROP group. Leukocyte was higher in the ROP group ($p = 0.018$). Hb [odds ratio (OR)=0.668, 95% confidence interval (CI)=0.555-0.804, $p < 0.001$], red cell distribution width (RDW) (OR=1.282, 95% CI=1.012-1.624, $p = 0.040$), leukocyte (OR=1.157, 95% CI=1.053-1.271, $p = 0.002$), and platelet (OR=0.997, 95% CI: 0.994-0.999, $p = 0.036$) values differed significantly between the two groups. Platelet, MCV, and MCH parameters were found to be lower in the Type 1 ROP group compared to the Stage 1+2 ROP group ($p < 0.005$). MCH was the most prominent predictor (cut-off: 34.43 pg) according to the results of C&RT analysis.

Conclusion: As Hb plays an important role in oxygen transport, low levels of Hb and especially MCH may cause increased vascular endothelial growth factor secretion from the hypoxic retina, thereby causing ROP. Therefore, the results of this study are encouraging regarding the use of the abovementioned CBC parameters as a simple screening test to predict ROP.

Keywords: Retinopathy of prematurity, complete blood count, risk prediction

Introduction

Retinopathy of prematurity (ROP) is a retinal vascular disorder causing visual impairments like strabismus, amblyopia, cataract, glaucoma, and finally blindness.¹ In order to prevent

blindness related to ROP, simple, reliable, and predictive data are needed to distinguish infants at risk. This would reduce the number of cases with advanced ROP and enable timely treatment. In addition, unnecessary and risky ROP examinations

Address for Correspondence: Ayşe İpek Akyüz Ünsal, Aydın Adnan Menderes University Faculty of Medicine, Department of Ophthalmology, Aydın, Turkey
Phone: +90 532 520 11 24 E-mail: ipekunsal@yahoo.com **ORCID-ID:** orcid.org/0000-0001-5260-674X

Received: 28.01.2019 **Accepted:** 25.12.2019

Cite this article as: Akyüz Ünsal Aİ, Key Ö, Güler D, Kurt Omurlu İ, Anık A, Demirci B, Dünder S. Can Complete Blood Count Parameters Predict Retinopathy Of Prematurity? Turk J Ophthalmol. 2020;50:87-93

in busy clinics may be avoided and the waste of time and effort prevented. As the proportion of surviving premature infants increases and the number of infants having the opportunity to be examined for ROP in the rural areas of developing countries decreases, the need for data to predict ROP is inevitable.^{2,3}

Considering the pathophysiology of ROP, the hyperoxia and hypoxia phases influence not only angiogenic and inflammatory cytokine production in the retina but also the production of blood cells, their volume, and the production of cytokines in the bone marrow. Previous studies have investigated neutrophil-to-lymphocyte ratio (NLR), mean platelet volume (MPV), and thrombocyte, lymphocyte, nucleated and absolute nucleated red blood cell (RBC) counts.^{4,5,6,7,8}

In this study, we analyzed complete blood count (CBC) profiles to identify a simple and prominent predictor for ROP, instead of investigating the parameters individually. Unlike the previous literature, we evaluated the same parameters 4 weeks after birth. The main aim of this study was to find a potential hematologic predictor at the time that ROP findings appear in the retina.

Materials and Methods

This study was conducted in the ophthalmology and neonatology departments of a tertiary referral university hospital between May 2013 and 2016 and included 150 infants. Ethical approval was obtained from the local ethics committee (2016/885). The same ophthalmologist (A.İ.A.Ü.) examined the infants according to the standards of the International Committee for the Classification of ROP (ICROP).⁹ Initial screening was done at gestational age (GA) of 31 weeks for those born before 27 weeks and at 4 weeks after birth for those born after 27 weeks' gestation. Although ROP screening for preterm infants born at <32 weeks GA and <1500 g birth weight (BW) is the common approach, the Neonatal Study Group in Turkey suggests evaluation of infants born at >32 weeks GA and >1500 g BW if the infant has a history of cardiopulmonary support and is at risk for developing ROP according to a neonatologist.³ Based on this reference, infants born at <36 weeks GA and <2670 g BW were also included in this study. Examinations were performed 1 hour after the instillation of 1% phenylephrine and 0.5% tropicamide. Funduscopic examinations were done by using binocular indirect ophthalmoscope, +28 diopter lens, pediatric speculum, and scleral depressor. Follow-up examinations and treatments were conducted according to the ICROP and ETROP criteria.^{9,10}

The data of neonates born between 24 and 36 weeks GA with BW less than 2670 g (570-2670 g) were analyzed retrospectively. The infants were divided into 2 main groups: those with no signs of ROP were included in the "non-ROP" group, while infants with stage 1, 2, and 3 ROP were included in the "ROP group". None of the infants developed stage 4, 5, or aggressive posterior ROP (APROP). All cases of type 1 ROP were treated with argon laser photocoagulation according to the

ETROP criteria; none was treated with anti-vascular endothelial growth factor injection.

In this study, type 1 ROP infants (n=12) were also analyzed separately as a subgroup. The data of 12 infants with type 1 ROP were compared with those of non-ROP infants born at ≤32 weeks GA as a control-subgroup (n=24) and the stage 1+2 ROP subgroup. Furthermore, the same analyses were performed between the type 1 ROP and type 2 ROP groups (n=21).

Complete blood count results from 4 weeks after birth were obtained from the electronic database of our hospital. Hematocrit (Hct), hemoglobin (Hb), mean corpuscular volume (MCV), mean corpuscular hemoglobin (MCH), MCH concentration (MCHC), red cell distribution width (RDW), procalcitonin (PCT), mean platelet volume (MPV), platelet distribution width (PDW), red blood cell (RBC), white blood cell (WBC), neutrophil, lymphocyte, monocyte, eosinophil, basophil, and platelet counts, and neutrophil/lymphocyte ratio (NLR) were compared between the ROP and non-ROP groups. Blood groups were also analyzed for the prediction of ROP. Four infants who had culture-proven septicemia and 4 other infants who were transfused with blood products in the fourth week after birth were excluded from the study.

Statistical Analysis

The normality of numeric variables was assessed using Kolmogorov-Smirnov test. Comparisons of normally distributed numeric variables between the groups were made by independent-samples t test. Descriptive statistics of the normally distributed numeric variables were presented as mean ± standard deviation. Mann-Whitney U test was used to compare non-normally distributed numeric variables between the groups and their descriptive statistics were presented as median (25th-75th percentiles). Factors significantly associated with ROP were determined with binary logistic regression analysis. P values below 0.05 were considered statistically significant.

A recursive partitioning method called Classification and Regression Tree (C&RT) analysis was used both for regression and classification. Beginning with the entire data set, C&RT was constructed by splitting subsets of the data set using all predictor variables to create two child nodes repeatedly. The best predictor was chosen using a variety of impurity or diversity measures. The aim was to produce subsets of the data which are as homogeneous as possible with respect to the target variable.¹¹ In our study, we used C&RT method in order to choose the best predictor and its cut-off point for ROP development.

Results

One hundred and forty-two infants met the inclusion criteria of this study. The mean GA at birth of the whole study group was 30.20±3.34 weeks (range: 24-36 weeks) and the mean BW was 1476.04±515.53 g (range: 570-2670 g). The non-ROP group consisted of 43 infants and the ROP group had 99 infants. Mean GA at birth of the infants in ROP group was 29.39±3.43 weeks (range: 24-36 weeks) and the mean BW

was 1382.44 ± 545.30 g (range: 570-2670 g). These figures in the non-ROP group were 32.05 ± 2.20 weeks (28-36 weeks) and 1691.51 ± 360.84 g (780-2380 g), respectively ($p < 0.001$, $p < 0.001$). There was no correlation between blood group and ROP development ($p = 0.414$).

Hematologic parameters such as Hb, Hct, RBC, MCH, and MCHC values were lower and WBC count was higher in the ROP group. The results of the comparison of independent groups were summarized in Table 1. According to the results of logistic regression analyses of hematologic parameters obtained at postnatal 4 weeks, risk of ROP development was negatively correlated with Hb (odds ratio [OR]=0.668, 95% confidence interval [CI]: 0.555-0.804, $p < 0.001$) and platelet count (OR=0.997, 95% CI=0.994-0.999, $p = 0.036$) and positively correlated with RDW (OR=1.282, 95% CI=1.012-1.624, $p = 0.040$) and WBC count (OR=1.157, 95% CI=1.053-1.271, $p = 0.002$). When all parameters were analyzed with the C&RT method, the discrimination rate for ROP infants was 72.5%, that for non-ROP infants was 27.5%, and the accuracy of the model was 83.1%. The overall data of this analysis are shown in Figures 1 and 2. The most striking hematologic parameter was MCH and its cut-off value was 34.43 pg. MCH was a stronger predictor, even better than traditional risk factors such as GA at birth and BW. The accuracy of this prediction was 83.8%. BW

was the second decisive factor with a cut-off point of 1485 g. The third value for prediction of ROP was WBC count, which had 78.2% accuracy at a cut-off point of 6325 mL.

The descriptive analysis of subgroups including type 1 ROP, stage 1+2 ROP, type 2 ROP, and control-subgroup for GA and BW were as follows: 25.91 ± 2.81 weeks, 28.52 ± 2.28 weeks, 27.38 ± 1.96 weeks, and 30.45 ± 1.44 weeks and 973.75 ± 462.14 g, 1248.92 ± 429.60 g, 1077.24 ± 350.56 g, and 1541.45 ± 318.16 g, respectively. Comparison of type 1 ROP and type 2 ROP subgroups according to GA and BW was not statistically significant ($p = 0.246$, $p = 0.062$). Type 1 ROP and control-subgroup comparison revealed significantly lower Hb, Hct, RDW, and platelet values in the type 1 ROP subgroup ($p < 0.05$) (Table 1). RDW value differed significantly between the type 2 ROP group and the control-subgroup ($p = 0.025$). The comparison of type 1 ROP and stage 1+2 ROP subgroups showed that MCV, MCH, and platelet values were significantly lower in the type 1 ROP group, as shown in Table 2 ($p < 0.05$).

Discussion

In this study, the C&RT method was preferred to analyze the data in order to find the most predictive hematologic parameter and its cut-off point among premature infants at risk

Table 1. Mean hematologic parameters of the ROP and non-ROP groups at postnatal 4 weeks and p values for between-group comparisons

	Non-ROP (n=43)	ROP (n=99)	P value
Hb (g/dL)	12.2 (10.5-13.6)	10.1 (8.6-11.7)	<0.001
Hct (%)	34.6 (30.7-39.7)	30.2 (25.8-35.5)	<0.001
MCV (fL)	95.1 (82.3-100.3)	90.5 (86.1-96.6)	0.329
RBC (x10 ⁶ /mL)	3.83 (3.45-4.29)	3.41 (2.97-4.09)	0.005
MCH (pg)	33.2 (27.7-35.3)	30.5 (28.1-32.6)	0.020
MCHC (g/dL)	34.2 (32.8-35.1)	33.6 (32.5-34.5)	0.019
RDW (ratio)	15.4 (14.6-16.7)	16.1 (15.2-17.4)	0.029
WBC (x10 ³ /mL)	9.06 (6.62-12.82)	10.4 (8.23-16.79)	0.018
Neutrophils (x10 ³ /mL)	2.29 (1.46-4.32)	3.07 (1.80-7.12)	0.083
Lymphocytes (x10 ³ /mL)	5.09 (3.89-6.85)	5.13 (4.03-7.45)	0.487
Monocytes (x10 ³ /mL)	1.02 (0.77-1.27)	1.21 (0.75-1.79)	0.241
Eosinophils (x10 ³ /mL)	0.27 (0.14-0.43)	0.33 (0.19-0.59)	0.202
Basophils (x10 ³ /mL)	0.03 (0.02-0.05)	0.03 (0.02-0.06)	0.936
Platelets (x10 ³ /mL)	349 (238-458)	327 (226-422)	0.203
PCT	0.48 (0.35-3.31)	0.44 (0.29-2.72)	0.293
MPV (fL)	10.57±1.49	10.32±1.22	0.352
PDW	15.8 (13.4-16.6)	15.9 (14.6-16.5)	0.973
NLR	0.62 (0.27-0.92)	0.57 (0.30-1.20)	0.319

ROP: Retinopathy of prematurity, Hb: Hemoglobin, Hct: Hemocrit, MCV: Mean corpuscular volume, RBC: Red blood cells, MCH: Mean corpuscular hemoglobin, MCHC: Mean corpuscular hemoglobin concentration, RDW: Red cell distribution width, WBC: White blood cells, PCT: Plateletcrit, MPV: Mean platelet volume, PDW: Platelet distribution width, NLR: Neutrophil/leukocyte ratio

for ROP. After logistic regression analysis we identified the most important risk factor, but could not determine a cut-off point for risk prediction. In an attempt to find a cut-off point for risk prediction, we had to perform C&RT analysis. The main purpose of this study was to identify valuable predictive parameters with cut-off values to enable ROP risk assessment in daily practice. The analyses were done in two parts, the first consisting of only hematologic parameters with each other and the second including the most well-known risk factors like GA and BW. Both analyses converged on the same predictive parameter and cut-off point. If MCH was less than or equal to 34.43 pg at postnatal 4 weeks, the likelihood of developing ROP was 79%. MCH was found to be the most prominent predictive value among all parameters. As MCH represents the mean Hb value in red blood cells and Hb is indispensable for the distribution and presentation of oxygen into the tissues, this result is not surprising. At the end of the hyperoxic phase, infants with low MCH cannot respond to the increased need for oxygen in the developing retina and the second hypoxic phase begins with increased VEGF levels. The possible underlying mechanism of the MCH and ROP relationship could originate from the nitric oxide (NO) pathways. The relaxation of small resistance arteries is mostly achieved by NO, which must be maintained in a delicate balance in the vasculature.¹² Hb in RBCs is not only responsible for oxygen transport and delivery, but also scavenges NO and produces Hb-NO complex.¹² If excessive production occurs at the inflammation site, NO leads to vasodilatation, capillary leakage, and edema. NO reacts with superoxide and forms highly toxic peroxynitrite (ONOO).¹³ It has been proven that peroxynitrite upregulates angiogenic factors such as VEGF, basic fibroblast growth factor (bFGF), and HIF-1alpha in human corneal limbal epithelial and human umbilical vein endothelial cell culture.¹⁴ It is clear that NO at the site of inflammation must be balanced by physiologic mechanisms, and this also explains the importance of having sufficient Hb in RBCs to prevent ROP.

To our knowledge, no previous study has described an association between MCH and ROP, but there are some studies that demonstrated significance of red cell parameters

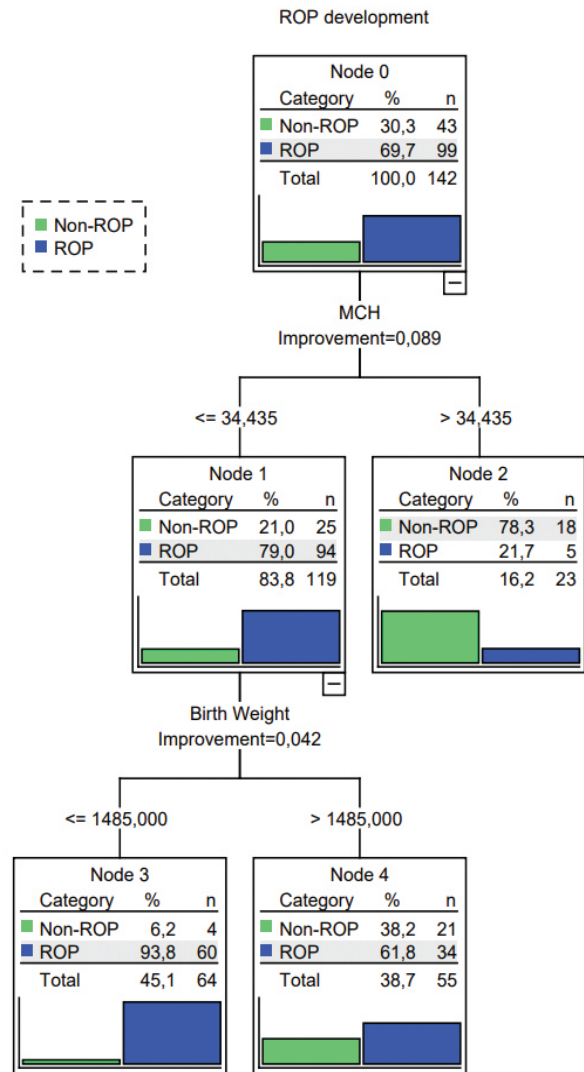


Figure 1. C&RT analyses of GA, birth weight, and counter blood cell parameters
GA: Gestational age at birth, ROP: Retinopathy of prematurity

	Control <32 wks GA (n=24)	Stage 1+2 ROP (n=67)	Type 1 ROP (n=12)	Type 2 ROP (n=21)	p value
GA (weeks)	30.45±1.44	28.52±2.28	25.91±2.81*	27.38±1.96*	* <0.001
BW (g)	1541.45±318.16	1248.92±429.60	973.75±462.14*	1077.24±350.56*	* <0.001
Hb (g/dL)	11.71±2.15	10.65±2.62	9.88±2.24*	10.63±2.51	*0.024
Hct (%)	34.25±5.88	31.91±8.09	29.88±6.01*	32.02±8.12	*0.045
RDW	15.32±1.55	16.61±2.15	17.11±2.42*	17.09±2.01**	*0.011,**0.025
MCV (fL)	92.15±11.93	91.37±7.99	82.77±10.55#	90.35±7.75	#0.003
MCH (pg)	31.50±4.49	30.54±2.95	27.48±4.90#	30.06±2.38	#0.014
PLT (x10 ³ /mL)	390.66±124.45	337.83±156.65	230.16±111.81*#	297.14±104.48	*0.001, #0.021

*,**compared to control, #compared to Type 2 ROP
GA: Gestational age at birth, BW: Birth weight, Hb: Hemoglobin, Hct: Hematocrit, RDW: Red cell distribution width, MCV: Mean corpuscular volume, MCH: Mean corpuscular hemoglobin, PLT: Platelet count

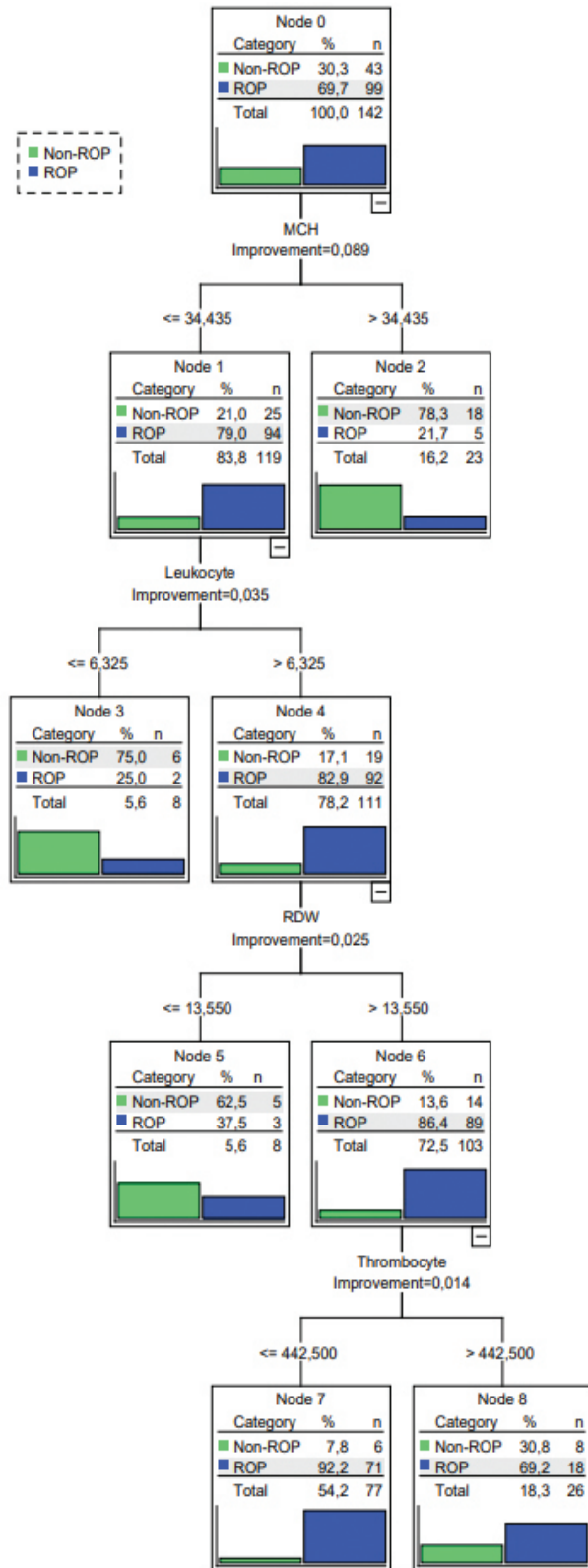


Figure 2. C&RT analyses for ROP only with counter blood cell parameters
ROP: Retinopathy of prematurity

in ROP, partially supporting our study. Anemia was found to be an independent risk factor of ROP in Chinese infants born from multiple gestations.¹⁵ The declining trend in MCV and significantly increased RDW in the present study also support that the RBC/reticulocyte balance is worth investigating further to explain ROP pathophysiology. Indeed, Lubetsky et al.⁷ and Niranjani et al.⁸ demonstrated that increased nucleated RBC count on the first day of life is associated with intrauterine hypoxia and can be used for the prediction of ROP. Contrary to our study, no correlation was found between Hb levels and ROP according to the multiple logistic regression analyses in a study by Banerjee et al.¹⁶ However, that study has a major methodological difference compared to ours, as they measured Hb levels of the premature infants on the first day of life.

According to logistic regression analyses, WBC count was significantly increased in our study. This increment was not due to any infection, as we excluded culture-proven septic premature infants at the beginning of our study by determining procalcitonin level (1.47 and 1.44 for non-ROP and ROP, respectively), which is used for prediction of infection. Although there was no sign of infection, lymphocyte, neutrophil, monocyte, and eosinophil counts tended to be higher in the ROP group and WBC count was significantly increased in our analyses, probably due to the ongoing inflammation of prematurity-related pathologies such as bronchopulmonary dysplasia, ROP, etc. Ashki et al.¹⁴ reported that macrophage, monocyte, and WBC infiltration causes NO release from tissues and NO consequently transforms into peroxynitrite. This highly toxic molecule increases angiogenic factors such as VEGF, b-FGF, and HIF1alpha. We assume that a similar underlying mechanism may also be valid for the ROP inflammation site as well. Similar to our study, Kurtul et al.⁴ studied the relationship between NLR and the development of ROP. They stated that inflammation in ROP can cause WBC and neutrophil counts to increase and they investigated NLR as a possible predictor for ROP in the first 24 hours of life. However, their results did not show NLR to be an independent predictor for ROP. In our study, a similar result was obtained for NLR at postnatal 4 weeks.

In this study, platelets were also evaluated for the prediction of ROP. Platelets store and carry bFGF, platelet-derived growth factor (PDGF), epidermal growth factor (EGF), matrix metalloproteinase (MMPs), and VEGF; alterations in volume and count could have a role in the pathophysiology of ROP. This is probably because they simultaneously contain both pro and anti-angiogenic factors.^{17,18} Clinical reports offer varying results regarding the clinical picture of ROP. Tao et al.⁵ stated that increased MPV was a marker of advanced stage ROP and attributed this to the larger platelets being more active than smaller ones in terms of carrying and storing VEGF. In our study, comparison of volume (MPV) and platelet counts between the ROP and non-ROP groups was statistically insignificant according to t tests. On the other hand, logistic regression analyses of the same parameters revealed that high platelet count was associated with low ROP risk (OR=0.997, 95% CI=0.994-

0.999, $p=0.036$) and C&RT analyses supported the same result with a cut-off point of 442,500/ μ L. Premature infants with a platelet count under 442,500/ μ L had a 92.2% risk for ROP development. Similar to our study, Jensen et al.⁶ reported that thrombocytopenia is a risk factor for advanced stage ROP. A study by Yau et al.¹⁵ revealed that low platelet count is also an important risk factor for ROP in babies of multiple gestation.

Although patient numbers in the subgroups were insufficient to apply C&RT statistics, lower levels of Hb, Hct, RDW, MCV, MCH, and platelets in the type 1 ROP group in comparison to stage 1+2 ROP and control-subgroups ($p<0.005$) suggest the importance of oxygen transport by RBCs. This finding is worth considering because if there is not enough Hb and MCH to transport oxygen, it would not be as important as previously believed whether the given oxygen concentration is high or low, although oxygen concentration is one of the major risk factors for ROP.

No statistically significant difference was found between the gender of babies and ROP development. Furthermore, to our knowledge, the relationship between blood groups and ROP development has not been previously reported. Our study data did not reveal any significant correlation between blood groups and ROP development.

Unfortunately, further investigation of functional capacity is needed for all of the aforementioned cell types, as neonatal and preterm physiology completely differs from that of adults. Hematological parameters show extreme fluctuations in a developing premature infant.¹⁹ Keeping this in mind, our study design focused on the specific time period of postnatal 4 weeks to avoid variations in CBC profiles. As the aim of our study was to evaluate CBC in accordance with the retinal findings of premature infants and to find a predictive value, we preferred to assess the potential pathophysiologic effects of blood cells on the retina and retinal vascularization in a certain time period. Despite the retrospective nature of our study, the validity and significance of our clinical research is worth considering, because low Hb levels cause hypoxia in all tissues and in the retina as well, leading neonatologists to transfuse blood, which is an accepted risk factor for ROP. Prospective studies may provide more information regarding prediction, prevention, and treatment strategies for ROP.

Conclusion

In conclusion, previous studies investigated hematologic parameters for prediction of ROP individually, but these parameters could be interrelated. In order to find the most important risk factor and a cut-off point to predict ROP, we evaluated all the hematologic parameters at the same time with a different statistical analysis method (C&RT). Even when taking the most well-known risk factors like GA and BW into account, C&RT analyses revealed that red cell parameters, especially MCH, was the most prominent risk factor with a cut-off point

at 34.43 pg and should be carefully monitored in clinics. CBC profile screening may be an easy to perform, economic, and widely available test to predict ROP.

Ethics

Ethics Committee Approval: Ethical approval was obtained from the local ethics committee (2016/885).

Informed Consent: Retrospective study.

Peer-review: Externally peer reviewed.

Authorship Contributions

Concept: A.İ.A.Ü., BD., Design: A.İ.A.Ü., B.D., Data Collection or Processing: A.İ.A.Ü., Ö.K., D.G., Analysis or Interpretation: A.İ.A.Ü., İ.K.Ö., B.D., S.O.D., Literature Search: A.İ.A.Ü., Ö.K., D.G., Writing: A.İ.A.Ü.

Conflict of Interest: No conflict of interest was declared by the authors.

Financial Disclosure: The authors declared that this study received no financial support.

References

- O'Connor AR, Stephenson T, Johnson A, Tobin MJ, Moseley MJ, Ratib S, Ng Y, Fielder AR. Long-Term Ophthalmic Outcome of Low Birth Weight Children With and Without Retinopathy of Prematurity. *Pediatrics*. 2002;109:12-18.
- Zin A, Gole GA. Retinopathy of prematurity-incidence today, *Clin Perinatol*. 2013;40:185-200.
- Bas AY, Koc E, Dilmien U, ROP Neonatal Study Group. Incidence and severity of retinopathy of prematurity in Turkey, *Br J Ophthalmol*. 2015;99:1311-1314.
- Kurtul BE, Kabatas EU, Zenciroglu A, Ozer PA, Ertugrul GT, Beken S, Okumus N. Serum neutrophil-to-lymphocyte ratio in retinopathy of prematurity, *JAAPOS*. 2015;19:327-331.
- Tao Y, Dong Y, Lu CW, Yang W, Li Q. Relationship between mean platelet volume and retinopathy of prematurity, *Graefes Arch Clin Exp Ophthalmol*. 2015;253:1791-1794.
- Jensen AK, Ying GS, Huang J, Karp K, Quinn GE, Binenbaum G. Thrombocytopenia and retinopathy of prematurity. *JAAPOS*. 2011;15:e3-e4.
- Lubetzky R, Stolovitch C, Dollberg S, Mimouni FB, Salomon M, Mandel D. Nucleated red blood cells in preterm infants with retinopathy of prematurity, *Pediatrics*. 2005;116:619-622.
- Niranjan HS, Bharath Kumar Reddy KR, Benakappa N, Murthy K, Shivananda S, Veeranna V. Role of hematological parameters in predicting retinopathy of prematurity (ROP) in preterm neonates, *Indian J Pediatr*. 2013;80:726-730.
- An International Committee for the Classification of Retinopathy of Prematurity: The International Classification of Retinopathy of Prematurity revisited, *Arch Ophthalmol*. 2005;123:991-999.
- Early Treatment for Retinopathy of Prematurity Cooperative Group, Results of the early treatment for retinopathy of prematurity randomized trial: revised indications for the treatment of retinopathy of prematurity, *Arch Ophthalmol*. 2003;121:1684-1696.
- Breiman L, Friedman JH, Olshen RA, Stone CJ. Classification and regression trees. Wadsworth & Brooks/Cole Advanced Books & Software, Monterey; 1984.
- Butcher JT, Johnson T, Beers J, Columbus L, Isakson BE. Hemoglobin alpha in the blood vessel wall, *Free Radic Biol Med*. 2014;73:136-142.
- Frost MT, Wang Q, Moncada S, Singer M. Hypoxia accelerates nitric oxide-dependent inhibition of mitochondrial complex I in activated macrophages, *Am J Physiol Regul Integr Comp Physiol*. 2005;288:R394-R400.

14. Ashki N, Chan AM, Wang W, Kiyohara M, Lin L, Braun J, Wadehra M, Gordon LK. Peroxynitrite upregulates angiogenic factors VEGF-A, bFGF, and HIF1alpha in human corneal limbal epithelial cells, Invest Ophthalmol Vis Sci. 2014;55:1637-1646.
15. Yau GSK, Lee JWY, Tam VTY, Yip S, Cheng E, Liu CC, Chu BC, Wong IY. Incidence and risk factors for retinopathy of prematurity in multiple gestations, a Chinese population study. *Medicine* 2015;94:e867.
16. Banerjee J, Asamoah FK, Singhvi D, Kwan AW, Morris JK, Aladangady N. Haemoglobin level at birth is associated with short term outcomes and mortality in preterm infants, *BMC Med.* 2015;27:16.
17. Jr Italiano JE, Richardson JL, Patel-Hett S, Battinelli E, Zaslavsky A, Short S, Ryeom S, Folkman J, Klement GL. Angiogenesis is regulated by a novel mechanism: pro- and antiangiogenic proteins are organized into separate platelet α granules and differentially released. *Blood.* 2008;111:1227-1233.
18. Folkman J. Angiogenesis: an organising principle for drug discovery? *Nat Rev Drug Discov.* 2007;64:273-286.
19. Henry, E., & Christensen, R. D. (2015). Reference intervals in neonatal hematology. *Clinics in perinatology.* 2015;42:483-497.



Characteristics and Seasonal Variations of Rhegmatogenous Retinal Detachment in the Eastern Black Sea Region of Turkey: 8-Year Results

● Hidayet Erdöl, ● Dilek Uzlu, ● Mehmet Kola

Karadeniz Technical University Faculty of Medicine, Department of Ophthalmology, Trabzon, Turkey

Abstract

Objectives: To assess seasonal variations in the incidence of rhegmatogenous retinal detachment (RRD) in the Eastern Black Sea region of Turkey.

Materials and Methods: Patients presenting due to primary RRD to a university hospital operating as a reference clinic in the region between 2011 and 2018 were evaluated retrospectively. Patients' ages, sex, affected eye, and presentation times were recorded. Years were divided into months, quarters, seasons, and half-year periods, and these periods were analyzed in terms of differences in patient numbers.

Results: Two hundred eighty-one eyes of 276 patients meeting the study criteria were included. The patients' mean age was 60.2 years, and the male:female ratio was 1.35:1. Right and left eye rates were similar. Detachments were most common (49.4%) in the upper temporal quadrant. Eighty-nine patients (31.6%) had undergone uncomplicated phacoemulsification surgery a mean 2.7 years previously. The mean annual case number was 35.13 ± 5.43 , and no statistically significant variation was determined in case numbers by year ($p=0.558$). Analysis of all years revealed a monthly mean case number of 23.42 ± 4.4 , with the highest number of cases, 29 (10.3%), being seen in September and the lowest number, 13 (4.7%), in December. No statistically significant monthly variation was determined ($p=0.613$). Similarly, no statistically significant variation was observed in case numbers analyzed by quarter, season, or half-year ($p>0.05$).

Conclusion: The incidence of cases of uncomplicated RRD does not exhibit seasonal variation in our region. We also think that since 31.6% had a history of cataract surgery, patients undergoing phacoemulsification surgery, even if uncomplicated, should be periodically assessed for detachment.

Keywords: Rhegmatogenous retinal detachment, seasonal, cataract, surgery

Introduction

Rhegmatogenous retinal detachment (RRD) is one of the important vision-threatening diseases and requires an emergency approach. The annual incidence in the USA is 12/100,000, while studies from Asian and European countries have reported figures of 7-14/100,000.^{1,2,3} A study from China reported that the highest incidence was in the 40-59 age group, with an

annual incidence of 14.4/100,000.⁴ An epidemiological study from New Zealand reported an incidence of RRD of 11.8 cases per 100,000, a mean age of 53.9 years, and a male:female ratio of 1.3:1.⁵

Studies investigating relations between RRD and seasonal changes have reported differing findings. One study from Lebanon reported a seasonal variation in the incidences of retinal detachment (RD), peaking in the spring and summer and at

Address for Correspondence: Hidayet Erdöl, Karadeniz Technical University Faculty of Medicine Department of Ophthalmology, Trabzon, Turkey
Phone: +90 erdolhidayet@yahoo.com E-mail: 532 766 61 52 **ORCID-ID:** orcid.org/0000-0003-3176-230X

Received: 09.09.2019 **Accepted:** 25.12.2019

Cite this article as: Erdöl H, Uzlu D, Kola M. Characteristics and Seasonal Variations of Rhegmatogenous Retinal Detachment in the Eastern Black Sea Region of Turkey: 8-Year Results. Turk J Ophthalmol. 2020;50:94-98

©Copyright 2020 by Turkish Ophthalmological Association
Turkish Journal of Ophthalmology, published by Galenos Publishing House.

their lowest in fall and winter.⁶ Laatikainen et al.⁷ evaluated 301 patients in a university hospital in Finland over a 4-year period and also detected a significant increase in RD incidence in summer compared to colder winter months. In contrast, a study from Kuwait reported more RRD in winter.⁸ Another study also showed no seasonal variation in RRD.⁹

The purpose of the present study was to investigate seasonal variations and epidemiological characteristics of patients presenting with retinal detachment to a university hospital serving as a reference hospital in the Eastern Black Sea region over an 8-year period.

Materials and Methods

Data for patients presenting with RRD to a tertiary hospital between January 2011 and December 2018 were evaluated retrospectively. The study complied with the principles of the Declaration of Helsinki and was approved by an ethics committee. Patients' date of presentation, age, sex, affected eye, history of intraocular surgeries, bilaterality, and location and numbers of detachments were evaluated. Based on the patients' date of presentation, numbers of patients were calculated in terms of months, quarters, seasons, and half-years. Seasons were defined as spring (March, April, May), summer (June, July, August), fall (September, October, November), and winter (December, January, February). Patients with previous uncomplicated cataract surgery were included in the study, and their surgery dates were recorded. Patients who developed detachment other than spontaneous RRD (traumatic or tractional), those with recurrent detachments, uveitis, glaucoma, aphakia, and history of ocular trauma or complicated cataract surgery, and those who underwent YAG laser capsulotomy as a result of posterior capsule opacification were excluded.

Statistical Analysis

Statistical analysis was performed on SPSS Statistics 21.0 for Windows (SPSS, Chicago, IL) software. Numbers of patients by month, quarter, season, and half-year over the 8-year study period were determined, and the one-sample chi-square test was used to analyze the significance of differences among these time periods. P values <0.05 were considered significant.

Results

Of 532 patients that presented with detachment, 281 eyes of the 276 patients who met the inclusion criteria were retrospectively analyzed. The patients' mean age was 60.22 ± 14.41 (23-88) years, 159 (57.6%) were men and 117 (42.5%) were women (ratio 1.35:1). One hundred forty-three (50.8%) right eyes and 138 (49.2%) left eyes were included, and the difference was not statistically significant ($p=0.796$). Bilateral detachment was present in 5 patients (1.8%), but there were no cases of simultaneous detachment. The interval between detachments in these 5 patients ranged between 5 and 53 months. Patients with detachment-related complaints or diagnoses for less than a month were included in the study. In addition, peripheral retinal degeneration was detected in

the other eye in 34 patients (12.3%) and prophylactic 532 nm laser photocoagulation was applied. No RRD developed during follow-up in the patients receiving prophylaxis during the study period. Refractive values of the eyes with retinal detachment could not be obtained. However, eyes with axial length greater than 25 mm were excluded from the study.

Eighty-nine (31.6%) eyes were pseudophakic and had undergone uncomplicated cataract surgery a mean 2.7 ± 2.8 years (2 months - 5.3 years) previously. Since there were no data regarding posterior vitreous detachment (PVD) before cataract surgery, the relationship between cataract surgery and PVD formation could not be evaluated in our study. Analysis of the retinal detachments revealed that 139 (49.4%) were in the superotemporal quadrant and 45 (16.0%) were in the inferotemporal quadrant. Retinal tears in multiple quadrants were observed in 69 eyes (24.5%).

The mean annual number of RRDs was 35.13 ± 5.43 (29-44), and no significant differences were determined in patient numbers according to year (chi-square=5.595, $p=0.558$). Distributions of patients by year are shown in Table 1.

Analysis of monthly distributions over the 8-year study period revealed a mean monthly case number of 23.42 ± 4.4 , with the highest number of presentations occurring in September ($n=29$, 10.3%) and the lowest number in December ($n=13$, 4.7%). No statistically significant difference was determined between the months (chi-square=9.093, $p=0.613$) (Table 2).

Quarterly analysis (months 1-3, 4-6, 7-9, and 10-12) revealed that the highest number of cases, 79 eyes, occurred in the third quarter (28.1%), although no significant differences were determined between the quarters (chi-square=5.05, $p=0.168$) (Table 3).

In terms of seasons, the highest number of cases was seen in summer ($n=77$, 27.4%) and the fewest in winter ($n=65$, 23.1%). No statistically significant difference was observed (chi-square=1.121, $p=0.772$) (Table 3).

Analysis by half-year revealed that 147 (52.3%) cases were seen in the first 6 months and 134 (47.7%) in the second. The difference was not statistically significant (chi-square=0.601, $p=0.438$).

Table 1. Annual distribution of patients presenting due to rhegmatogenous retinal detachment

Year	Eyes with detachment(s) (n=281)
2011	29
2012	39
2013	32
2014	32
2015	33
2016	44
2017	41
2018	31

Table 2. Mean and total monthly numbers and percentages of cases of rhegmatogenous retinal detachment over the 8-year study period

Month	Mean ± SD	Range	Total (n=281)	Percentage (%)
January	3.00±1.06	1-4	24	8.5
February	3.50±2.87	1-9	28	9.9
March	3.13±1.24	2-5	25	8.9
April	2.50±1.60	1-5	20	7.2
May	2.88±2.16	1-8	23	8.1
June	3.38±1.84	1-7	27	9.7
July	3.13±0.99	2-5	25	8.9
August	3.13±0.83	2-4	25	8.9
September	3.63±1.92	2-8	29	10.3
October	2.88±1.88	1-6	23	8.1
November	2.38±1.06	1-4	19	6.8
December	1.63±0.74	1-3	13	4.7

SD: Standard deviation

Table 3. Distributions of cases of rhegmatogenous retinal detachment by quarter and season

	Number (n=281)	Percentage		Number (n=281)	Percentage
1 st quarter	77	27.4%	Spring	68	24.1%
2 nd quarter	70	24.9%	Summer	77	27.4%
3 rd quarter	79	28.1%	Fall	71	25.2%
4 th quarter	55	19.5%	Winter	65	23.1%

Discussion

Retinal detachment is a severe, vision-threatening retinal disease requiring an emergency approach, and has an incidence of 7-14/100,000.^{2,3} Vision prognosis is linked to macular involvement.¹⁰ Even if anatomical success can be achieved following surgery in cases treated late, vision levels may still be low.

Several studies have described myopia as the most important risk factor for RRD.¹¹ Another important risk factor is peripheral retinal degeneration, described as closely associated with myopia, and lattice degeneration has been reported in approximately 1 patient in 5.^{12,13,14} One study showed that lattice degeneration was present in 30% of RRD cases with atrophic holes.¹⁵ An epidemiological study from Taiwan investigated 2,359 patients and revealed a high prevalence of RRD between the ages of 50 and 69 and high myopia in 10.51% of cases. In addition, the condition was more common in men in all age groups.¹⁶ Similarly, another study from Western Australia showed that the risk of RD was greater in men and at more advanced ages.¹⁷ The mean age of the patients in our study was 60.22, and the male:female ratio was 1.35. We attribute the relatively higher mean age in our study to the lower incidence of high myopia in our region. However, our male:female ratio was similar to that in several previous studies.

Due to the high likelihood of a similar pathology in the other eye in patients with RRD, a detailed examination of the contralateral eye is essential.¹⁸ One study reported the incidence of lattice degeneration as 18.7% in the other eye, and the rates have been reported between 7 and 19% in various other studies.^{2,12} The rate of RD development in the fellow eye due to peripheral degeneration was reported as 24.5% in another study, and rates of bilateral RRD of 2.8 to 4.6% have been reported.^{15,19} Hajari et al.²⁰ analyzed the risk of RRD in the fellow eye and reported figures of 1.3% per year, with a 5-year cumulative incidence of primary RRD in fellow eyes of 6.7±0.3%. Individuals with RRD in one eye have a 100-fold higher risk of RRD developing in the other eye, increasing still further with male sex and lens surgery, but declining with age. It was therefore concluded that patients require regular follow-up for at least 10 years.²⁰ In our fellow eye analysis, we determined peripheral degeneration capable of causing RRD in 12.3% of cases, and these underwent laser prophylaxis. Bilateral RRD developed in 1.8% of cases during our study.

Another important risk factor for the development of RRD is a history of intraocular surgery, and RRD has been reported in 10 to 40% of cases following cataract surgery.^{5,9,12,21} Cataract surgery was shown to increase the risk of detachment at least 4-fold compared to the normal population, and there is a greater risk of cataract-related detachment in subsequent years, particularly

among myopic subjects.²² However, since the follow-up periods in studies on this subject vary, there is also variation in the incidences reported. Post-cataract surgery RRD is reported to be more common in men compared to women.^{22,24} In one study from France, 2,680,167 cataract operations were performed in 2009 through 2012, and 62,065 detachment operations were carried out during the same period. The cumulative risk of RRD was 0.19% in non-operated patients and 0.99% in pseudophakic patients, with an odds ratio of 3.87.²⁵ It has also been suggested that the incidence of RRD will rise still further due to the recent increase in cataract operations.²⁶ In a prospective non-comparative series of 58 eyes without preoperative PVD at ultrasound examination, 58.7% developed PVD within the first year of phacoemulsification surgery, the majority occurring in the first postoperative month.²⁷ A study from Spain retrospectively investigated 439 highly myopic eyes with a mean follow-up time of 61.5 months and determined an incidence of RRD of 2.7%. Patients were also assigned into two age-based groups at time of surgery. The incidence of RRD in patients aged 50 or less was 3.65%, compared to 2.52% in the over-50 group. Age at cataract surgery was correlated with risk of retinal detachment in high myopes.²² In a study from New Zealand, RRD developed in 33% of patients undergoing cataract surgery, and 50% of detachments post-cataract surgery occurred within 2 years of the cataract surgery and approximately 75% of these were within 12 months.⁵ In the present study, RRD developed after cataract surgery in 89 patients (31.6%) over the 8-year observation period, and detachment occurred at a mean 2.7 ± 2.8 years (2 months - 5.3 years) after cataract surgery. This rate is consistent with the previous literature.

In terms of the tear site, Mitry et al.¹² reported that 56% of tears occurred in the upper temporal quadrant, and that multiple tears were observed in 47.7% of cases. Chou et al.¹⁵ investigated 1,032 eyes from 1995 to 2001 and reported that 58.2% of tears were in the superior hemisphere and that multiple tears were present in 23.7% of patients. In our study, 139 (49.4%) of tears leading to detachment were in the superotemporal quadrant and 45 (16.0%) were in the inferotemporal quadrant. In addition, 24.5% (69 eyes) of patients had multiple tears. These data are also compatible with the previous literature.

Studies have also investigated the relation between RRD and seasonal variations and meteorological events in addition to known risk factors. In a study by Ivanisevic et al.²⁸, 79 out of 272 cases between 1988 and 1999 occurred in summer, 71 in winter, 67 in spring, and 63 in fall. They observed no correlation between season and RRD. Li et al.⁹ also detected no seasonal variation in RRD case numbers in their study from Beijing. Mansour et al.⁶ retrospectively analyzed data pertaining to 211 consecutive patients over a 13-year period and reported 46 eyes with RRD in fall, 46 in winter, 62 in spring, and 57 in summer. Significant variation was observed, with RRD increasing in spring and summer (56%), when the weather is warmer, compared to winter and fall (44%) ($p < 0.05$). They provisionally attributed this variation to exposure to sunlight and outdoor activities in the warmer weather.⁶ An 11-year (1999-2009) study

of detachments across Taiwan revealed a significant seasonal relationship with the monthly incidence of RRD. The annual RD incidence rates were between 7.8 and 10.8 cases/100,000 during the study period, and the monthly RD incidence rates were positively associated with ambient temperature and negatively associated with atmospheric pressure.²⁹ Laatikainen et al.⁷ evaluated 301 patients over a 4-year period and reported more detachments in summer months than in winter. Paavola et al.³⁰ reported a tendency for RRD to increase in spring and summer compared to winter. In contrast, another 7-year observation study from Kuwait reported more RRD in the winter months than in summer.⁸ In a study from Canada investigating whether there was any association between external environmental temperature and retinal detachment, only a relationship between tractional detachment and high temperature was detected; no correlation was observed between RRD and high temperature. The relationship between detachments and high temperature was reported to be more significant in individuals aged over 75.³¹ However, the majority of these studies of seasonal variations in RRD have been regional and involved different time intervals.

Although the incidence of RRD was higher in summer and fall in our study, no significant variation was observed compared to the other seasons. Due to the meteorological character of our region, exposure to sunlight is not high, and the number of sunny days is generally low. The difference in length between day and night in summer and winter is also not as great as it is in northern countries. The hypothesis that sunlight contributes to the development of RRD, as posited in some studies, can therefore be disregarded for our region.^{6,7} The most common month for RRD in our 8-year evaluation was September, at 10.3%, although this was not significantly different from the incidence in other months. The higher, albeit statistically insignificant, number of cases of RRD in September may be due to the greater engagement in agricultural and outdoor activities at that time as a result of the sociodemographic nature of the region. A significant and labor-intensive part of agricultural activities generally takes place in August and September. Therefore, we believe that these physically demanding activities may have contributed to the development of RRD. The incidence of RRD was relatively higher in the third quarter (28.1%) and in the summer (27.4%) compared to the other periods. Lower rates of RRD were observed in winter and December, although these were not statistically significant.

Our study involved an 8-year period, and since ours is the only reference center in the region, patients from our and surrounding provinces requiring vitreoretinal surgery are generally referred to our clinic. We regard this as sufficiently indicative of the numbers of RRD cases in our region. Ours is the first region-based research on the subject.

The principal limitations of this study are its single-center and population-based nature. Although our clinic is the only reference center in the Eastern Black Sea region, there is still a high probability of some patients presenting to centers outside it. An advanced database is therefore needed for all cases to be

definitively evaluated. Increasing the sample size by evaluating all cases may thus elicit a more definitive result.

Ethics

Ethics Committee Approval: Karadeniz Technical University Faculty of Medicine Scientific Research Ethics Committee-2019/226.

Peer-review: Externally peer reviewed.

Authorship Contributions

Surgical and Medical Practices: H.E., M.K., Concept: H.E., Design: H.E., Data Collection or Processing: H.E, M.K., Analysis or Interpretation: H.E., D.U., Literature Search: H.E., D.U., Writing: H.E.

Conflict of Interest: No conflict of interest was declared by the authors.

Financial Disclosure: The authors declared that this study received no financial support.

References

- Rowe JA, Erie JC, Baratz KH, Hodge DO, Gray DT, Butterfield L, Robertson DM. Retinal detachment in Olmsted County, Minnesota, 1976 through 1995. *Ophthalmology*. 1999;106:154-159.
- Törnquist R, Stenkula S, Törnquist P. Retinal detachment: A study of a population-based patient material in Sweden 1971-1981. I. *Epidemiology. Acta Ophthalmol*. 1987;65:213-222.
- Wong TY, Tielsch JM, Schein OD. Racial difference in the incidence of retinal detachment in Singapore. *Arch Ophthalmol*. 1999;117:379-383.
- Zou H, Zhang X, Xu X, Wang X, Liu K, Ho PCP. Epidemiology survey of rhegmatogenous retinal detachment in Beixinjing District, Shanghai, China. *Retina*. 2002;22:294-299.
- Polkinghorne PJ, Craig JP. Northern New Zealand rhegmatogenous retinal detachment study: Epidemiology and risk factors. *Clin Exp Ophthalmol*. 2004;32:159-163.
- Mansour AM, Hamam RN, Sibai TA, Farah TI, Mehio-Sibai A, Kanaan M. Seasonal variation of retinal detachment in Lebanon. *Ophthalmic Res*. 2009;41:170-174.
- Laatikainen L, Tolppanen E-M, Harju H. Epidemiology of rhegmatogenous retinal detachment in a Finnish population. *Acta Ophthalmol*. 1985;63:59-64.
- Al Samarrai R. Seasonal Variations of Retinal Detachment among Arabs in Kuwait. *Ophthalmic Res*. 1990;22:220-223.
- Li X. Incidence and Epidemiological Characteristics of Rhegmatogenous Retinal Detachment in Beijing, China. *Ophthalmology*. 2003;110:2413-2417.
- Karacorlu M, Sayman Muslubas I, Hocaoglu M, Arf S, Ersoz MG. Correlation between morphological changes and functional outcomes of recent-onset macula-off rhegmatogenous retinal detachment: prognostic factors in rhegmatogenous retinal detachment. *Int Ophthalmol*. 2018;38:1275-1283.
- Risk Factors for Idiopathic Rhegmatogenous Retinal Detachment. The Eye Disease Case-Control Study Group. *Am J Epidemiol*. 1993;137:749-757.
- Mitry D, Singh J, Yorston D, Siddiqui MA, Wright A, Fleck BW, Campbell H, Charteris DG. The predisposing pathology and clinical characteristics in the Scottish retinal detachment study. *Ophthalmology*. 2011;118:1429-1434.
- Lewis H. Peripheral retinal degenerations and the risk of retinal detachment. *Am J Ophthalmol*. 2003;136:155-160.
- Tillery WV, Lucier AC. Round atrophic holes in lattice degeneration: an important cause of phakic retinal detachment. *Trans Sect Ophthalmol Am Acad Ophthalmol Otolaryngol*. 1976;81:509-518.
- Chou SC, Yang CH, Lee CH, Yang CM, Ho TC, Huang JS, Lin CP, Chen MS, Shih YE. Characteristics of primary rhegmatogenous retinal detachment in Taiwan. *Eye*. 2007;21:1056-1061.
- Chen SN, Lian I Bin, Wei YJ. Epidemiology and clinical characteristics of rhegmatogenous retinal detachment in Taiwan. *Br J Ophthalmol*. 2016;100:1216-1220.
- Manners S, Ng JQ, Kemp-Casey A, Chow K, Kang CY, Preen DB. Retinal detachment surgery in Western Australia (2000-2013): A whole-population study. *Br J Ophthalmol*. 2017;101:1679-1682.
- Ung T, Comer MB, Ang AJS, Sheard R, Lee C, Poulson AV, Newman DK, Scott JD, Richards AJ, Snead MP. Clinical features and surgical management of retinal detachment secondary to round retinal holes. *Eye*. 2005;19:665-669.
- Jamil MH, Farooq N, Khan MT, Jamil AZ. Characteristics and pattern of rhegmatogenous retinal detachment in Pakistan. *J Coll Physicians Surg Pakistan*. 2012;22:501-504.
- Hajari JN, Bjerrum SS, Christensen U, Kiilgaard JF, Bek T, La Cour M. A nationwide study on the incidence of rhegmatogenous retinal detachment in denmark, with emphasis on the risk of the fellow eye. *Retina*. 2014;34:1658-1665.
- Cankurtaran V, Tekin K, Citirik M, Simsek M, Inanc M, Teke MY. Long-term complications of surgical procedures for pseudophakic retinal detachment. *Int J Clin Exp Med*. 2016;9:16637-16644.
- Alió JL. Lens surgery (cataract and refractive lens exchange) and retinal detachment risk in myopes: Still an issue? *Br J Ophthalmol*. 2011;95:301-303.
- Sheu SJ, Ger LP, Ho WL. Late Increased Risk of Retinal Detachment After Cataract Extraction. *Am J Ophthalmol*. 2010;149:113-9.
- Tuft SJ, Gore DM, Bunce C, Sullivan PM, Minassian DC. Outcomes of pseudophakic retinal detachment. *Acta Ophthalmol*. 2012;90:639-644.
- Daïen V, Le Pape A, Heve D, Carriere I, Villain M. Incidence, Risk Factors, and Impact of Age on Retinal Detachment after Cataract Surgery in France: A National Population Study. *Ophthalmology*. 2015;122:2179-2185.
- Bjerrum SS, Mikkelsen KL, La Cour M. Risk of pseudophakic retinal detachment in 202,226 patients using the fellow nonoperated eye as reference. *Ophthalmology*. 2013;120:2573-2579.
- Mirshahi A, Hoehn F, Lorenz K, Hattenbach LO. Incidence of posterior vitreous detachment after cataract surgery. *J Cataract Refract Surg*. 2009;35:987-991.
- Ivanisevic M, Erceg M, Eterovic D. Rhegmatogenous retinal detachment and seasonal variations. *Acta Medica Croat*. 2002;56:49-51.
- Lin HC, Chen CS, Keller JJ, Ho JD, Lin CC, Hu CC. Seasonality of Retinal Detachment Incidence and Its Associations With Climate: An 11-Year Nationwide Population-Based Study. *Seasonality of Retinal Detachment Incidence and Its Associations With Climate: An 11-Year Nationwide Population-Based Study. Chronobiol Int*. 2011;28:942-948.
- Paavola M, Chehova S, Forsius H. Seasonal Variations in Retinal Detachment in Northern Finland and Novosibirsk. *Acta Ophthalmol*. 1983;61:806-812.
- Auger N, Rhéaume MA, Bilodeau-Bertrand M, Tang T, Kosatsky T. Climate and the eye: Case-crossover analysis of retinal detachment after exposure to ambient heat. *Environ Res*. 2017;157:103-109.



Artifacts and Anatomic Variations in Optical Coherence Tomography

© Atilla Bayer*, © Ahmet Akman**

*Dünyagöz Hospital, Ankara, Turkey

**Private Practice, Ankara, Turkey

Abstract

In recent years, ophthalmologists widely depend on optical coherence tomography (OCT), which is an objective, reliable, and repeatable structural test for both early diagnosis of glaucoma and detecting progression of the disease. Using this technology, it is now possible to take measures of various anatomic structures and layers of the optic nerve head, peripapillary retinal nerve fiber layer, and macular area. Although OCT has these powerful capabilities in general, anatomical variations, artifacts related to the ocular pathologies, and issues with image acquisition can be present in up to one-third of scans. These anatomical variations and artifacts can be misleading to an interpreter and may lead to erroneous conclusions. This review focuses on the realization and prevention of most common anatomical variations and artifacts observed with OCT imaging. The concepts of floor effect and red and green diseases are also investigated.

Keywords: Optical coherence tomography, OCT artifacts, OCT anatomic variations, red disease, green disease

Introduction

Optical coherence tomography (OCT) has been widely used in recent years for both the diagnosis and follow-up of glaucoma, as well as in other areas of ophthalmology.^{1,2,3,4} When initiating treatment for patients with glaucoma, suspected glaucoma, or ocular hypertension, ophthalmologists generally base their decisions on OCT results. As with any newly introduced diagnostic method, it may take time to understand the limitations and sources of error of OCT. Evaluating results with knowledge of these limits and sources of errors will make OCT results more reliable in the diagnosis of new cases and analysis of progression.

For a sound evaluation of OCT data, physicians should not limit themselves to the colored images, tables, or maps

that compare patient data with the normative database. The classifications in these images, tables, and maps are based on the manufacturer's normative database and are open to various sources of error. For this reason, when evaluating OCT reports the physician should examine en-face images, temporal-superior-nasal-inferior-temporal (TSNIT) profiles, and the patient's unprocessed scan results to ensure accurate data analysis. Knowing potential sources of error is critical at this stage to be able to make a correct decision.^{5,6,7,8} This is the only way we can distinguish anatomical variations and artifacts from true glaucomatous damage. Because retinal nerve fiber layer (RNFL) thickness can vary by race, this must also be considered starting from patient registration.⁹

Overlooking OCT artifacts can cause patients who actually have glaucomatous damage to be evaluated as normal (i.e., false-

Address for Correspondence: Dünyagöz Hospital, Ankara, Turkey

Phone: +90 542 244 91 91 E-mail: atillabayer@hotmail.com **ORCID-ID:** orcid.org/0000-0002-0184-8033

Received: 11.03.2019 **Accepted:** 25.12.2019

Cite this article as: Bayer A, Akman A. Artifacts and Anatomic Variations in Optical Coherence Tomography. Turk J Ophthalmol. 2020;50:99-106

negative diagnosis) or conversely, lead to false-positive diagnosis of individuals without glaucoma. False-positive diagnoses can lead to years of unnecessary treatment and follow-up. In addition to the adverse effects and expense associated with treatment, being diagnosed with a potentially blinding condition can cause patients serious psychological distress.¹⁰

The aim of this review is to examine common OCT artifacts and anatomical variations that can lead to misdiagnosis and explain how we can correct these errors in cases where they may occur. The most widely used OCT images are those of the Cirrus HD-OCT (Carl Zeiss Meditec, Dublin, CA, USA) and Spectralis OCT (Heidelberg Engineering Inc., Heidelberg, Germany) instruments.

Causes and Mechanisms of OCT Artifacts

Floor Effect

Compared to early and moderate glaucoma, OCT is less useful in advanced cases. In advanced glaucoma, only the retinal vascular structures and glial cells remain due to RNFL loss.^{5,6} In other words, glaucoma progression analysis with OCT is no longer possible at this stage, and visual field should be the focus during follow-up.

In the OCT devices currently in use, RNFL thicknesses less than 30 µm cannot be obtained, even in a small area.⁵ If a lower RNFL thickness measurement is observed, the physician should carefully examine the scan for artifacts.

Red and Green Disease

Red and green are the colors used by OCT manufacturers to indicate whether various parameters of a patient are within normal limits compared to a normative database. Red disease refers to a false-positive disease diagnosis due to the device incorrectly indicating abnormality (red) in the corresponding image when there is no damage.^{5,11} In contrast, green disease is when the software interprets actual glaucomatous damage as normal (green), leading to a false-negative diagnosis.¹²

In addition to device-related artifacts, it should also be borne in mind that red and green color assignments in OCT reports stem from the normative database used. As the normative databases used by manufacturers do not account for variations related to high refractive error, the pediatric age group, and race, results may be erroneous in some patient groups.

Common OCT Artifacts and Anatomical Variations

Imaging Artifacts

Poor Image Quality

A high-quality scan is essential for a reliable OCT result. Each OCT system has its own system for assessing image quality. For example, Cirrus HD-OCT uses the “signal strength” parameter for this purpose and repeating the scan is recommended if signal strength is below 6. Spectralis OCT uses a quality score, or the “Q” coefficient, for the same purpose; values less than 20 require repetition of the test. Signal strength may be low in patients with dry eye, refractive media opacities such as nephelion or cataract, and fixation disorders (Figure 1). Low signal strength may also occur if the lens of the OCT device has not been cleaned, the

device is heavily used, or the technician is inexperienced. In heavily used devices, dirty lenses and reduced laser emission power may result in poor image quality. Poor scanning quality can lead to inaccurate RNFL thickness measurements.^{13,14,15}

However, a quality control parameter within acceptable limits should not be interpreted as everything being in order. Other possible artifacts must also be ruled out. One of these is motion artifacts. Motion artifacts occur when patients move their eyes during the scan. These artifacts manifest as breaks in deviation maps or infrared reflectance (IR) images (Figure 2). It may be noticed during scanning that the disc or macula is not well centered. In such cases, the patient should be informed and the test repeated, using an external fixation point if necessary.

Segmentation Errors

All OCT systems have segmentation or layer-seeking algorithms to enable analysis of a target retinal layer. Segmentation errors occur when the software is unable to correctly distinguish the retinal layers. In such cases, the RNFL or other retinal layer being assessed is measured as thicker or, more commonly, thinner than it actually is. On RNFL thickness maps and graphs, large areas are marked red or green, and sometimes white (Figure 3a). When the RNFL border is manually moved to its normal position using the device settings, global and sectoral RNFL thickness values return to normal (Figure 3b). The floor effect

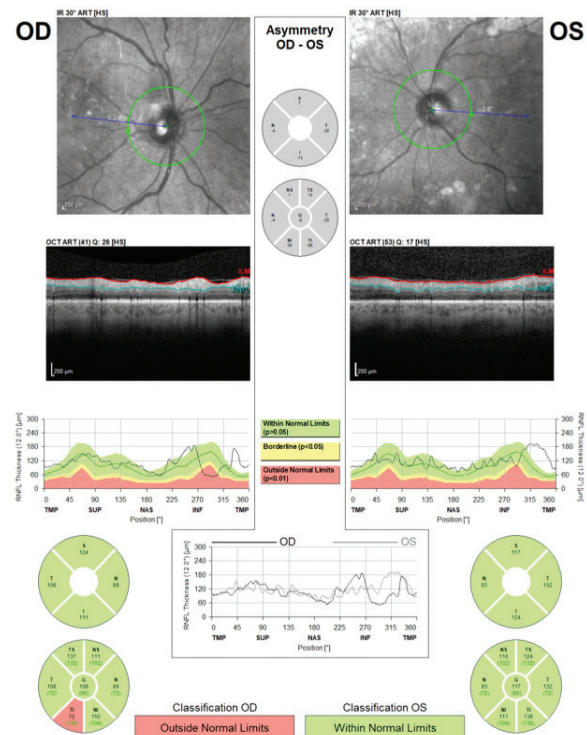


Figure 1. (Spectralis OCT) Example of a scan with low quality score for the left eye of a patient with cataract. Note that the quality coefficient (Q) is 26 on the right and 17 on the left. In the RNFL profile image of the left eye, RNFL thickness measurements are artificially high in the inferior and temporal regions due to incorrect detection of the RNFL border by the device algorithm
RNFL: Retinal nerve fiber layer, OCT: Optical coherence tomography

should also be kept in mind for measurements of very low (thinner than 30 μm) RNFL thicknesses.

In patients with high myopia and tilted discs, symmetric and bilateral nasal RNFL thinning (red disease) may be observed. This is due to temporal displacement of the RNFL bundles and vascular structures in myopic patients. The magnification effect caused by longer than normal axial length may also contribute to this measurement error. Peripapillary atrophy, which frequently accompanies myopia, is another cause of segmentation errors. Upon careful examination of the regions covered by the peripapillary scanning ring, which is normally 3.46 mm in diameter, it can be seen that the section passes through an area of peripapillary atrophy (Figure 4). In this case, the scan should be repeated using a larger ring (4.1 mm or 4.7 mm, as in Spectralis OCT) or the data from macular and optic nerve head analyses should be used.

Myelinated nerve fibers are another common anomaly. Thickly myelinated nerve fibers can hide glaucomatous RNFL loss and may cause inaccurate segmentation and green disease. Again, in such cases the peripapillary scan should be repeated with larger ring diameter, or the macular and optic nerve head analyses should be taken into account.

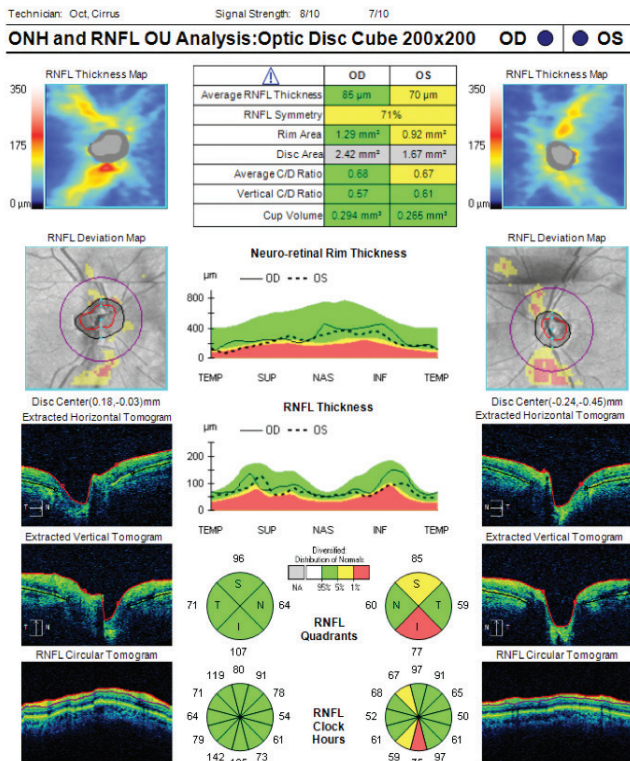


Figure 2. (Cirrus HD-OCT) Although signal strength is within normal range (≥ 6), there are significant motion artifacts in the deviation map of the right eye (note the breaks in the blood vessels). Similar motion artifacts are also present in the RNFL deviation map of the left eye. Average RNFL thickness is 85 μm in the right eye and 70 μm in the left eye. While the TSNIT profile and RNFL classification are within normal limits in the right eye, there are abnormalities in some sectors of the left eye

RNFL: Retinal nerve fiber layer, OCT: Optical coherence tomography

Patient-based Artifacts

Patient-based artifacts are the most challenging for physicians. It is common to see red areas in the results of a reliable OCT scan performed on a young and healthy person with no known ocular disease. Some of these patients are diagnosed with early glaucoma and immediately started on medical therapy, while others are referred to another center for further examination. In either case, a young person is diagnosed or suspected of having a disease that is potentially blinding and requires lifelong treatment and follow-up. This places a serious psychological burden on the patient and their family. In order to avoid misleading patients, ophthalmologists should know and distinguish the effects of anatomical differences on OCT reports.

Split RNFL and Shifted RNFL Peaks

In most individuals, the retinal ganglion cell projections converge towards the superior and inferior poles of the optic disc to form thick RNFL bundles. This anatomical feature is displayed as two peaks on the patient's expected curve on TSNIT graphs formed according to the normative database. In some

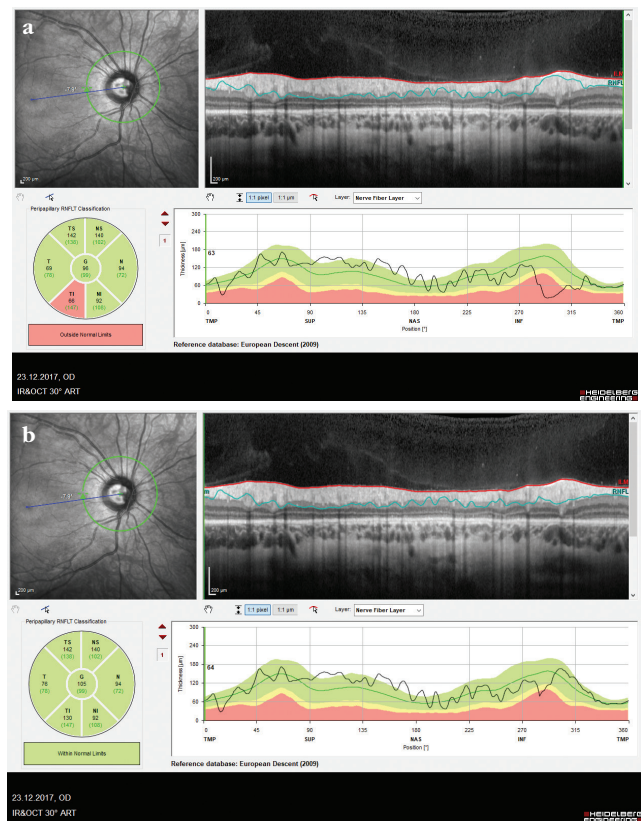


Figure 3. (Spectralis OCT) Segmentation artifact in the inferotemporal region in a myopic patient. Due to incorrect detection of the RNFL border by the device (in the upper right RNFL profile image), RNFL thickness measurement was artificially low in an area of approximately one sector, and peripapillary RNFL thickness was classified as abnormal in that sector. When the RNFL border is manually shifted to its normal position using the device settings, RNFL thickness returns to normal values and peripapillary RNFL thickness in the inferotemporal sector is also classified as normal

RNFL: Retinal nerve fiber layer, OCT: Optical coherence tomography

cases, the superior and/or inferior RNFL bundles are divided in two and enter the optic disc in the form of a pair of separate bundles each. This is called a split RNFL.¹⁶ This split RNFL structure was later demonstrated in a histopathological study to be a variation of normal rather than an artifact.¹⁷ With the widespread use of OCT scans, these types of images have become more common (Figure 5). This variation, which is mostly encountered in young, healthy people, leads to red disease by giving the appearance of a local RNFL defect.

Shifted RNFL peaks occur when average RNFL thickness values are within normal limits but the peaks are not aligned with expected positions on TSNIT graphs based on the normative database (Figure 6). In other words, the RNFL bundles have completely normal thickness but abnormal topographic position. Hong et al.¹⁸ stated that RNFL peaks can be displaced temporally and cause red disease artifact in healthy individuals. Hood et al.¹⁹ stated that the position of RNFL peaks on TSNIT graphs are in the same region as major retinal vessels. A shifted RNFL can sometimes be caused by cyclotorsion of the eye as well. To compensate for this, the Spectralis OCT has the FoBMO axis (axis between the centers of the fovea and Bruch's membrane opening) connecting the foveal center and disc center.²⁰ The starting and ending points of the TSNIT graph are calculated according to the FoBMO axis.

It is very important that the completely normal split RNFL and shifted RNFL configurations are well recognized to be able to accurately diagnose localized RNFL loss. Careful examination of the RNFL TSNIT profile and checking that optic nerve head parameters and macular scan results are within normal limits is very important for recognizing these anomalies. Split RNFL and shifted RNFL can each exist in both the superior and inferior regions or appear in only one of these quadrants, and the two variations can also be seen together in the same eye. With new software it will be easier to recognize these artifacts in the future.

Refractive Media Opacities

The presence of vitreous opacities such as Weiss ring in the scanning area can cause imaging artifacts, often leading to red disease and sometimes to green disease. Vitreous opacities

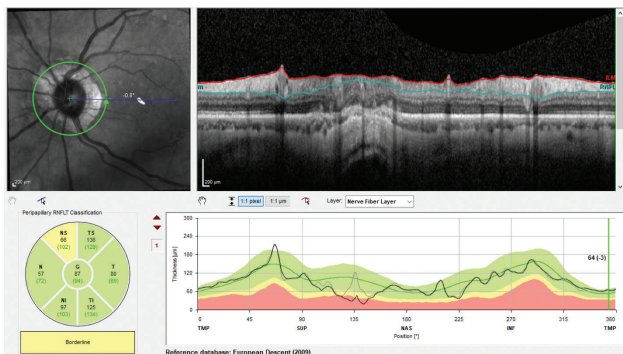


Figure 4. (Spectralis OCT) Segmentation error resulting from the passage of the scanning ring over an atrophic area in the superonasal region of a myopic patient with peripapillary atrophy. Values on the TSNIT profile are close to zero and peripapillary RNFL classification is borderline in that area
RNFL: Retinal nerve fiber layer, OCT: Optical coherence tomography

can also cause the device to incorrectly detect the disc center, resulting in scanning of the wrong area. Because these opacities change position with eye movements, repeated scans may be affected intermittently while appearing normal at other times (Figures 7a and 7b). These artifacts can be recognized by carefully examining the deviation map, IR image, and TSNIT graph. Results may return to normal in scans performed immediately after asking the patient to move their eye from

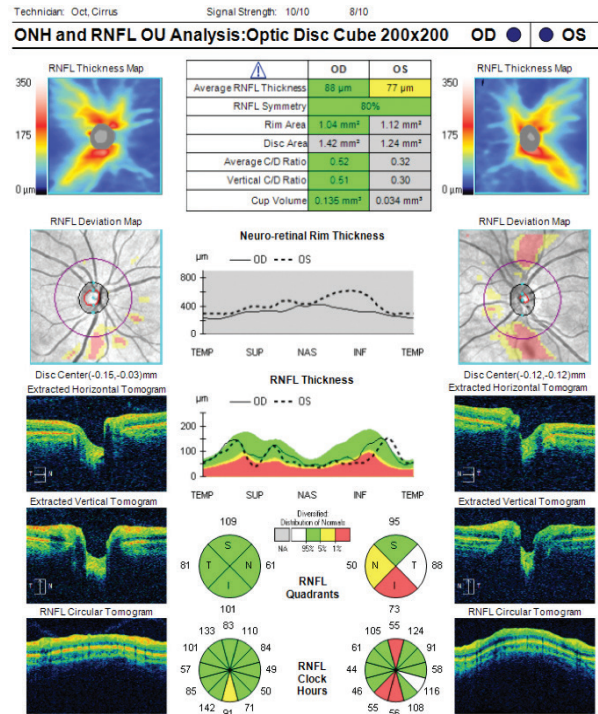


Figure 5. (Cirrus HD-OCT) The superior RNFL bundles of both eyes of this patient show split RNFL defect. On the TSNIT profile, the superior vertex in both eyes is split into two peaks separated by a valley. In addition, a displaced RNFL configuration which is more prominent in the left eye is observed in the inferior quadrants of both eyes. Average RNFL thickness is within normal limits on the right and borderline on the left

RNFL: Retinal nerve fiber layer, OCT: Optical coherence tomography

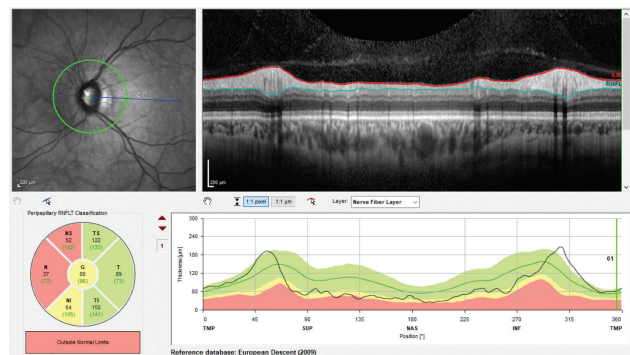


Figure 6. (Spectralis OCT) In the TSNIT profile of a myopic patient, RNFL thickness values in the nasal sectors appear low due to temporal displacement of the RNFL peaks. This occurs because the peaks do not align with expected positions in TSNIT graphs based on the normative database

RNFL: Retinal nerve fiber layer, OCT: Optical coherence tomography

side to side. In addition, cataracts, asteroid hyalosis, and vitreous hemorrhages can also cause refractive media opacities. Refractive media opacities are the most common cause of artifacts in elderly patients.

Vitreoretinal Interface Problems

Peripapillary Vitreoretinal Traction and Hyaloid Thickening:

Vitreoretinal traction can cause pseudothickening of the RNFL, resulting in green disease artifact (Figure 8). This situation can arise when posterior vitreous detachment is developing in healthy eyes, or RNFL thickness measurement may be artificially high due to posterior hyaloid thickening in conditions such as advanced diabetic retinopathy. Segmentation errors may also occur in such cases (Figure 9a). On sector analysis, average RNFL thickness values may be much higher than expected. Marked glaucomatous changes may be observed on optic disc analysis (Figure 9b). Visual field testing may also reveal glaucomatous visual field loss (Figure 9c). When the vitreous completely detaches from the retina, RNFL thickness decreases significantly and the actual values become apparent.

Optic Nerve Head Drusen

In patients with optic nerve head drusen, scan quality score is within normal limits and no artifacts are seen (Figure 10). An important clue is that cup area or volume is very small or at a value of 0 despite normal disc size. In optic nerve head measurements, neuroretinal rim thickness above normal values is conspicuous. In addition to RNFL measurements, macular scans and visual field testing for the detection of glaucomatous damage assist diagnosis. In such cases, progression analysis can be used if there is suspicion or diagnosis of glaucoma, but it should be noted here that optic disc drusen themselves may also cause progressive RNFL and visual field losses similar to glaucoma.^{21,22} It is also beneficial to use other tests for the diagnosis of disc drusen.

Large Disc

In case of oversized optic nerve head, the peripapillary RNFL scanning ring will pass close to the disc margin, leading to inaccurate results. It should not be forgotten that these discs may present with other anomalies such as tilted disc and peripapillary atrophy, and macular scans and visual field testing should be preferred as much as possible during follow-up.

Chorioretinal Scarring

Chorioretinal scars, especially those located close to the disc, cause localized RNFL losses depending on the size of the lesion. These losses are mostly sectoral and also manifest on visual field as localized absolute scotomas. It should be remembered that macular scans may also be affected, and fundus scanning should be performed carefully to rule out these lesions.

Other Artifacts That Cause Green Disease

In addition to the aforementioned diseases, green disease may also appear in the form of thinning in certain sectors in eyes with substantially high RNFL thickness values. Because the patient has very high RNFL thickness values initially, regions with glaucomatous damage will be classified as green according to the

normative database. In such cases, the importance of progression analysis becomes clear once more. This allows patients to be identified as progressive while their results are green.

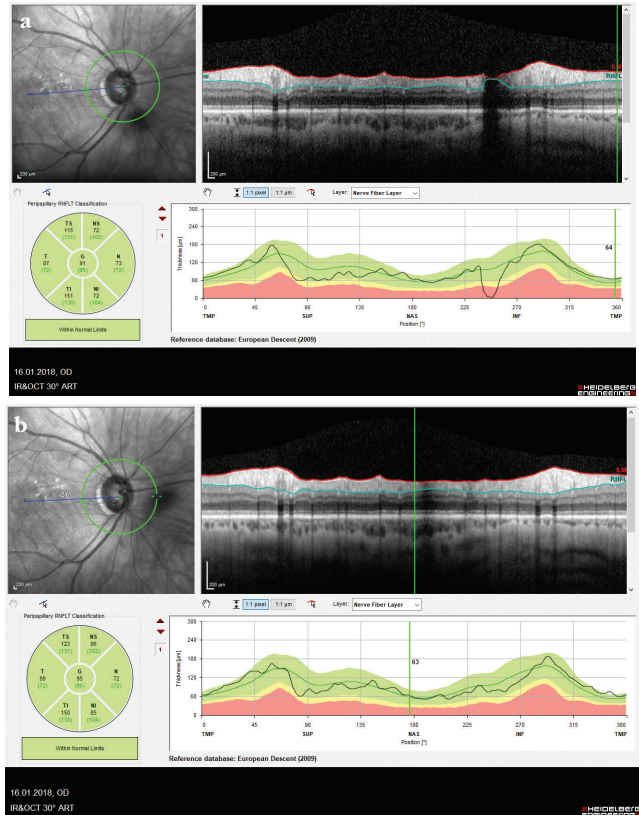


Figure 7. (Spectralis OCT) A Weiss ring coinciding with the laser scanning region causes a segmentation artifact in the inferonasal sector of the right optic disc due to shadowing. On the TSNIT profile, it is seen that RNFL thickness has a value of 0 in this region (a). Upon movement of the eye, the Weiss ring also moved and the device’s algorithm performed segmentation correctly in the inferonasal region. The Weiss ring in the nasal region produces minimal shadowing that does not impair segmentation (b)

RNFL: Retinal nerve fiber layer, OCT: Optical coherence tomography

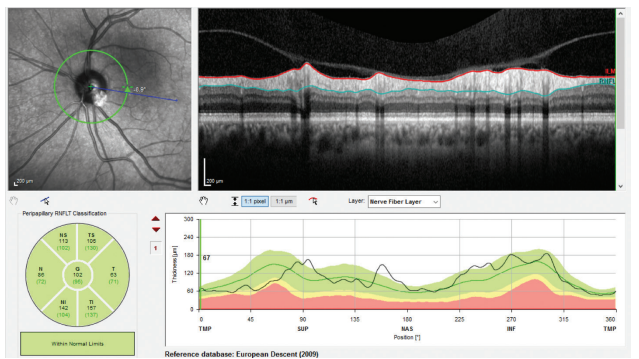


Figure 8. (Spectralis OCT) Areas of pronounced vitreoretinal traction are seen upon examination of the vitreoretinal interface in the RNFL profile of a patient being followed due to ocular hypertension. In the TSNIT profile, RNFL thickness is higher than expected normal values in certain areas in the superonasal region. Peripapillary RNFL thickness is classified as above normal in most sectors

RNFL: Retinal nerve fiber layer, OCT: Optical coherence tomography

In uveitic patients, edema causes RNFL thickening and measured values may be high. This in turn may mask glaucomatous RNFL thinning.²³

In diabetic macular edema, RNFL thickness measurements may be high due to the retinal edema despite the presence of glaucomatous damage (Figure 11a), and green classification in these sectors may obscure the glaucomatous damage. Macular

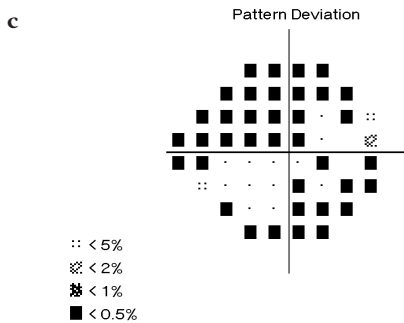
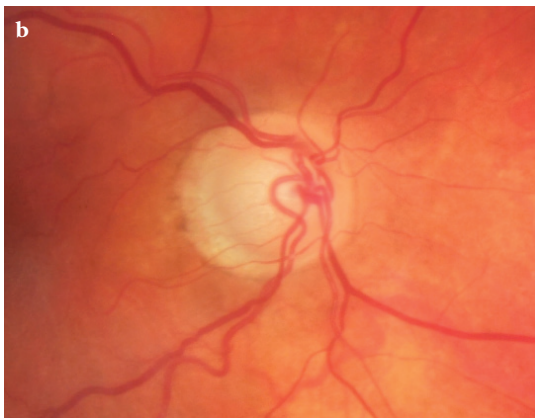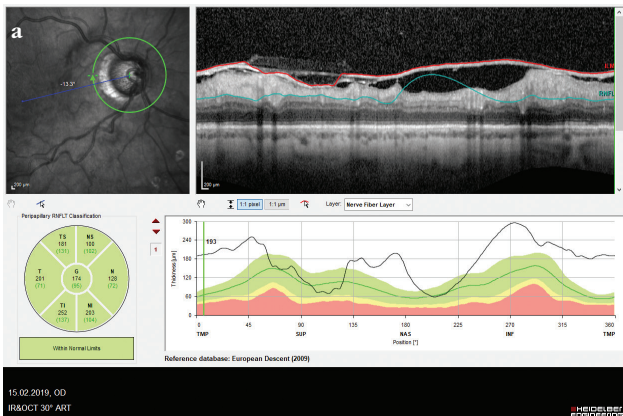


Figure 9. (Spectralis OCT) Segmentation is completely disrupted in a patient with substantial ILM thickening. Peripapillary RNFL classification appears to be within normal limits in all sectors, and analysis of the sectors shows that average RNFL thickness values are much higher than expected average values. The same findings are seen in the TSNIT profile (a). Disc photography shows prominent glaucomatous pitting and peripapillary atrophy (b). There is significant glaucomatous visual field loss in the same eye (c). Note that OCT RNFL classification appears to be within normal limits in all sectors

RNFL: Retinal nerve fiber layer, OCT: Optical coherence tomography

scanning with OCT facilitates the detection of diabetic macular edema (Figure 11b). In such cases, when the information provided by structural tests is limited, visual field testing may allow us to detect glaucomatous damage (Figure 11c).

In age-related macular degeneration, retinal edema can cause green disease as in uveitic and diabetic cases.

Epiretinal membranes can also cause artificially high RNFL thickness measurements and result in green disease.

In peripapillary retinoschisis, there is a temporary increase in RNFL thickness (Figure 12).^{24,25} Values return to normal after the resolution of retinoschisis. It should be noted that the coexistence of peripapillary retinoschisis and glaucoma is common.

The low postoperative IOP values of patients who have undergone surgery may also cause RNFL thickness to appear increased. This should be taken into account when performing progression analysis.

How to Avoid Overlooking Artifacts

The Whole Report Should Be Evaluated, Including Raw Data if Necessary

Most of the time, interpretations are made without looking at the entire report. In the course of fast-paced practice, the physician usually makes interpretations by looking at colored maps and graphs. It is only possible to catch the aforementioned artifacts when one looks at the entire report and, in suspicious cases, at the raw data. When an artifact is detected, it must be decided whether it is a localized artifact or one that affects the

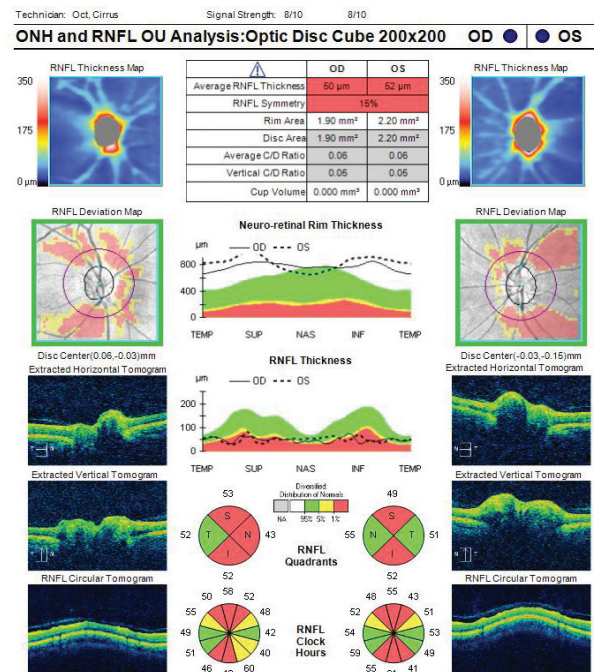


Figure 10. (Cirrus HD-OCT) Quality score is within normal limits in a scan from a patient with optic nerve head drusen. However, note that although the diameter of the disc is normal, the cup volume value is 0. Despite significant RNFL thinning, neuroretinal rim thickness is higher than normal values in optic nerve head measurements

RNFL: Retinal nerve fiber layer, OCT: Optical coherence tomography

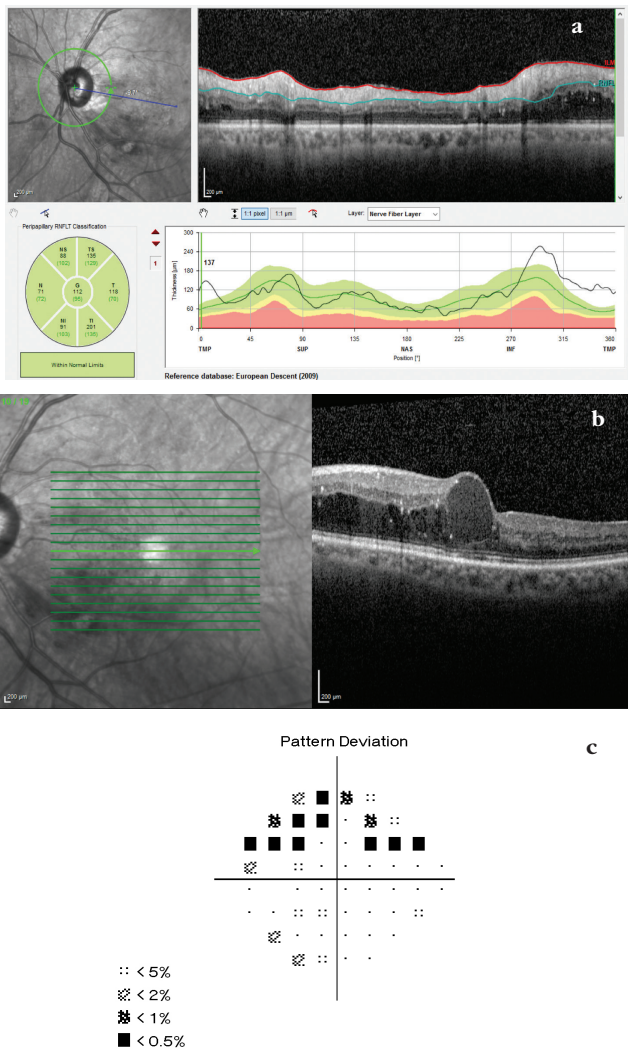


Figure 11. (Spectralis OCT) All sectors are green in the RNFL classification graph of a glaucoma patient with diabetic retinopathy and macular edema. In the TSNIT profile, the thickness curve is seen to be above normal limits in the inferotemporal, temporal, and superotemporal regions (a). Macular OCT analysis shows diabetic macular edema (b). Central 24-2 visual field testing demonstrates glaucomatous superior arcuate defect (c). Note that the sector classifications are completely within normal limits in the OCT RNFL examination of this patient

RNFL: Retinal nerve fiber layer, OCT: Optical coherence tomography

test in general, and the test should be repeated if necessary. As with artifacts associated with cataract, some artifacts cannot be avoided by repeating the test.

Output Data Should Be Consistent with Clinical Presentation

Sometimes the patient’s clinical signs say it all. For example, although we may know very well that the patient has advanced glaucomatous damage, all quadrants and sectors may be green in the OCT report, or vice versa. By examining the report in detail and the raw data in the device, it can be understood whether these OCT findings are due to an artifact.

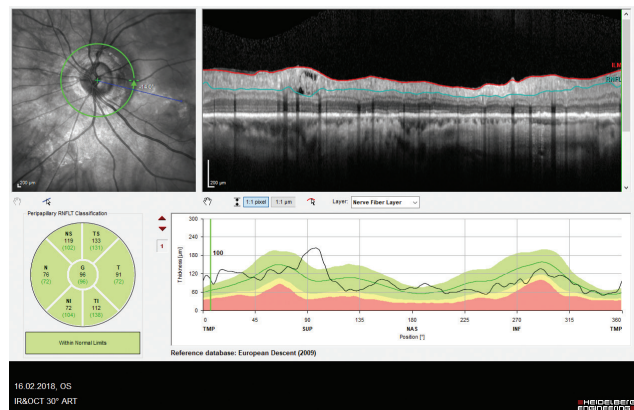


Figure 12. (Spectralis OCT) Peripapillary retinoschisis in the superior quadrant is apparent in a myopic patient (see RNFL profile image in the upper right). Note that the RNFL thickness curve is well above expected values in the location corresponding to the region of retinoschisis in the TSNIT profile

RNFL: Retinal nerve fiber layer, OCT: Optical coherence tomography

Technicians Should Be Trained to Distinguish Major Artifacts

A well-trained technician recognizes most artifacts that occur during a scan, whether they stem from device settings or are patient-based, and repeats the test after correcting the underlying cause. This prevents wasting of time and effort.

Ocular Comorbidities Should Be Considered

It should be kept in mind that ocular disorders such as diabetic macular edema, uveitic cystoid macular edema, epiretinal membrane, age-related macular degeneration, and macular edema due to postoperative hypotonia can directly affect OCT results.

Diagnosis Should Not Be Based on a Single Test Result or Region Scan

One must bear in mind that artifacts may be present in every test; therefore, important decisions regarding treatment and follow-up should not be based on a single report or a single region scan. It should also be ensured that optic disc, RNFL, and macular analyses are consistent with one another.

Peer-review: Externally and internally peer reviewed.

Authorship Contributions

Surgical and Medical Practices: A.B., A.A., Concept: A.B., A.A., Literature Search: A.B., A.A., Writing: A.B., A.A.

Conflict of Interest: No conflict of interest was declared by the authors.

Financial Disclosure: The authors declared that this study received no financial support.

References

- Stein JD, Talwar N, Laverne AM, Nan B, Lichter PR. Trends in use of ancillary glaucoma tests for patients with open-angle glaucoma from 2001 to 2009. *Ophthalmology*. 2012;119:748-758.

2. Gabriele ML, Wollstein G, Ishikawa H, Kagemann L, Xu J, Folio LS, Schuman JS. Optical coherence tomography: history, current status, and laboratory work. *Invest Ophthalmol Vis Sci.* 2011;52:2425-2436.
3. Dong ZM, Wollstein G, Schuman JS. Clinical utility of optical coherence tomography in glaucoma. *Invest Ophthalmol Vis Sci.* 2016;57:556-567.
4. Güngör SG, Akman A. Are all retinal nerve fiber layer defects on optic coherence tomography glaucomatous? *Turk J Ophthalmol.* 2017;47:267-273.
5. Asrani S, Essaid L, Alder BD, Santiago-Turla C. Artifacts in spectral-domain optical coherence tomography measurements in glaucoma. *JAMA Ophthalmol.* 2014;132:396-402.
6. Asrani S. Pitfalls in optical coherence tomography imaging. *Glaucoma Today.* 2016;(May/June):39-43.
7. Lee SY, Kwon HJ, Bae HW, Seo SJ, Lee YH, Hong S, Seong GJ, Kim CY. Frequency, type and cause of artifacts in swept-source and cirrus HD optical coherence tomography in cases of glaucoma and suspected glaucoma. *Curr Eye Res.* 2016;41:957-964.
8. Liu Y, Simavli H, Que CJ, Rizzo JL, Tsikata E, Maurer R, Chen TC. Patient characteristics associated with artifacts in spectralis optical coherence tomography imaging of the retinal nerve fiber layer in glaucoma. *Am J Ophthalmol.* 2015;159:565-576.
9. Kostanyan T, Sung KR, Schuman JS, Ling Y, Lucy KA, Bilonick RA, Ishikawa H, Kagemann L, Lee JY, Wollstein G. Glaucoma Structural and Functional Progression in American and Korean Cohorts. *Ophthalmology.* 2016;123:783-788.
10. Tastan S, Iyigun E, Bayer A, Acikel C. Anxiety, depression, and quality of life in Turkish patients with glaucoma. *Psychol Rep.* 2010;106:343-357.
11. Chong GT, Lee RK. Glaucoma versus red disease: imaging and glaucoma diagnosis. *Curr Opin Ophthalmol.* 2012;23:79-88.
12. Sayed MS, Margolis M, Lee RK. Green disease in optical coherence tomography diagnosis of glaucoma. *Curr Opin Ophthalmol.* 2017;28:139-153.
13. Rao HL, Addepalli UK, Yadav RK, Senthil S, Choudhari NS, Garudadri CS. Effect of scan quality on diagnostic accuracy of spectral-domain optical coherence tomography in glaucoma. *Am J Ophthalmol.* 2014;157:719-727.
14. Huang J, Liu X, Wu Z, Satta S. Image quality affects macular and retinal nerve fiber layer thickness measurements on fourier-domain optical coherence tomography. *Ophthalmic Surg Lasers Imaging.* 2011;42:216-221.
15. Russell DJ, Fallah S, Loer CJ, Riffenburgh RH. A comprehensive model for correcting RNFL readings of varying signal strengths in cirrus optical coherence tomography. *Invest Ophthalmol Vis Sci.* 2014;55:7297-7302.
16. Colen TP, Lemij HG. Prevalence of split nerve fiber layer bundles in healthy eyes imaged with scanning laser polarimetry. *Ophthalmology.* 2001;108:151-156.
17. Kaliner E, Cohen MJ, Miron H, Kogan M, Blumenthal EZ. Retinal nerve fiber layer split bundles are true anatomic variants. *Ophthalmology.* 2007;114:2259-2264.
18. Hong SW, Ahn MD, Kang SH, Im SK. Analysis of peripapillary retinal nerve fiber distribution in normal young adults. *Invest Ophthalmol Vis Sci.* 2010;51:3515-3523.
19. Hood DC, Salant JA, Arthur SN, Ritch R, Liebmann JM. The location of the inferior and superior temporal blood vessels and interindividual variability of the retinal nerve fiber layer thickness. *J Glaucoma.* 2010;19:158-166.
20. Bayer A. Interpretation of imaging data from Spectralis OCT. Akman A, Bayer A, Nouri-Mahdavi K. *Optical Coherence Tomography in Glaucoma* (1st ed). Cham; Switzerland; Springer Nature; 2018;6:55-76.
21. Savino PJ, Glaser JS, Rosenberg MA. A clinical analysis of pseudopapilledema. II. Visual field defects. *Arch Ophthalmol.* 1979;97:71-75.
22. Roh S, Noecker RJ, Schuman JS, Hedges TR, Weiter JJ, Mattox C. Effect of optic nerve head drusen on nerve fiber layer thickness. *Ophthalmology.* 1998;105:878-885.
23. Moore DB, Jaffe GJ, Asrani S. Retinal nerve fiber layer thickness measurements: uveitis, a major confounding factor. *Ophthalmology.* 2015;122:511-517.
24. Hwang YH, Kim YY, Kim HK, Sohn YH. Effect of peripapillary retinoschisis on retinal nerve fibre layer thickness measurement in glaucomatous eyes. *Br J Ophthalmol.* 2014;98:669-674.
25. Bayraktar S, Cebeci Z, Kabaalioglu M, Ciloglu S, Kir N, Izgi B. Peripapillary retinoschisis in glaucoma patients. *J Ophthalmol.* 2016;2016:1612720.



Fungal Keratitis, or Misled by a Small Insect?

© Betül Nurefşan Bayraktutar*, © Ayşe Yıldız Taş**, © Afsun Şahin***

*Cornea Service, New England Eye Center, Department of Ophthalmology, Tufts Medical School, Tufts University School of Medicine, Boston, USA

**Koç University Hospital, Department of Ophthalmology, İstanbul, Turkey

***Koç University Faculty of Medicine, Department of Ophthalmology, İstanbul, Turkey

Abstract

The pine processionary caterpillar is an insect that has multiple small, thin hairs around its body as a defense mechanism. These hairs have a hazardous effect on ocular structures and cause a broad range of reactions from conjunctivitis to endophthalmitis, referred to as ophthalmia nodosa. The diagnosis of the disease is based on the patient's history and the detection of the hairs on ocular structures. In this report, we present a patient with ophthalmia nodosa misdiagnosed as fungal keratitis, and the actual diagnosis was made by *in vivo* confocal microscopy. We also would like to increase awareness among ophthalmologists about the disease which has a growing distribution area due to climate change.

Keywords: Fungal keratitis, *in vivo* confocal microscopy, keratitis, ophthalmia nodosa, pine processionary caterpillar

Introduction

The pine processionary caterpillar, *Thaumetopoea pityocampa*, is an insect which has abundant fine hairs (also called setae) on its body. It is widely distributed in the pine forests of warmer regions in southern Europe, central Asia, the Near East, and North Africa.¹

The hairs of the pine processionary caterpillar have hazardous effects on the human eye, skin, and respiratory tract. The clinical presentation of the resulting ocular disease, referred to as ophthalmia nodosa, can vary in a wide spectrum as conjunctivitis, keratitis, cataracts, uveitis, vitritis, and endophthalmitis.^{2,3,4,5,6,7,8} The ocular reaction is linked to the mechanical effect of the hairs, direct toxicity of the toxin present inside the hair, and immunoglobulin E-mediated allergic reaction to various caterpillar proteins. The diagnosis of the disease is based on direct visualization of hairs and clinical history of the patient. Since it is a rare condition and the hairs are extremely small and

thin, it can be mis- or underdiagnosed during a routine slit-lamp examination.

Our aim in this case report is to present a patient who was misdiagnosed as having fungal keratitis and increase the awareness of ophthalmologists about ophthalmia nodosa, which is expected to be seen at higher frequency with a wider distribution area¹ because of global warming.

Case Report

A 74-year-old man was referred to our clinic with a presumed fungal keratitis diagnosis from a general ophthalmologist. The patient presented to the other clinic with the complaint of acute-onset eyelid swelling, redness, pain, and vision loss in his right eye. He was diagnosed with presumed fungal keratitis and treated with topical fortified antibiotic and antifungal therapy. Corneal scraping and culture was reported to be negative. However, his clinical signs and symptoms worsened despite

Address for Correspondence: Afsun Şahin, Koç University Hospital, Department of Ophthalmology, İstanbul, Turkey
Phone: +90 505 671 32 24 E-mail: afsunsahin@gmail.com **ORCID-ID:** orcid.org/0000-0002-5083-5618

Received: 22.08.2019 **Accepted:** 25.12.2019

Cite this article as: Bayraktutar BN, Taş AY, Şahin A. Fungal Keratitis, or Misled by a Small Insect? Turk J Ophthalmol. 2020;50:107-109

topical antibacterial and antifungal therapy, and he was referred to our clinic for a definitive diagnosis.

On examination in our clinic, the right periocular skin including the upper and lower lids of the right eye was severely hyperemic, swollen, and itchy (Figure 1A). Visual acuity was hand movements in the right eye, 20/20 in the left eye. Slit-lamp biomicroscopy revealed conjunctival chemosis, corneal epithelial defect, diffuse corneal haze (more dense in various foci), multiple foci of keratitis, fibrinous anterior chamber reaction, and 3-mm asymmetric hypopyon in the right eye (Figure 1B). The fundus could not be visualized. B-scan ultrasound of the posterior segment was normal. In vivo corneal confocal microscopy (IVCM) was performed for prompt diagnosis. Numerous hyperreflective, linear needle-shaped structures with small protrusions, resembling fungal hyphae, were seen (Figure 2). However, the length and sharp linearity of the structures were not consistent with typical hyphae structures seen in IVCM images. Therefore, the patient's medical history was re-evaluated in order to understand the events leading to keratitis. The patient was asked for the details of organic trauma before his complaints started and it was learned that he had seen a small tent-like nest in a pine tree in the garden of his home and had tried to remove it from the tree. With this new history, the patient was evaluated again by high-magnification slit-lamp examination and numerous caterpillar hairs embedded in the

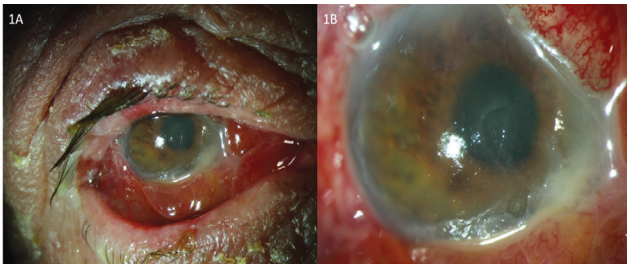


Figure 1. A) Severe eyelid edema, conjunctival hyperemia, and chemosis are seen in the right eye. B) Diffuse corneal edema, multiple foci of keratitis, fibrinous anterior chamber reaction, and 3-mm asymmetric hypopyon in the right eye are seen in the right eye

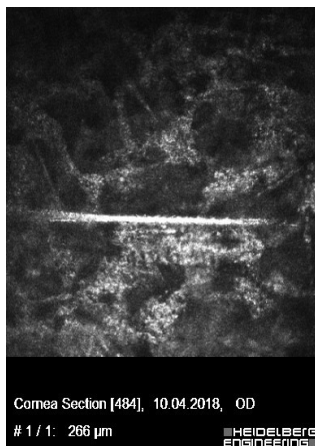


Figure 2. In vivo confocal microscopic image of caterpillar hair: Linear needle-shaped structure with small protrusions, which resembles fungal hyphae

cornea were seen with iris-scattering lighting (Figure 3A). These hairs were not seen at any other structure, including the anterior chamber, iris, vitreous, and retina.

Corneal debridement was performed under a surgical operating microscope (Figure 3B). The patient was treated with topical prednisolone acetate 1.0% solution hourly, cycloplegic eye drops 3 times a day, and moxifloxacin 0.5% eye drops 4 times a day as prophylaxis against secondary infection. On the third day of treatment, his visual acuity increased to 20/200, eyelid edema and conjunctival chemosis decreased (Figure 4A), hypopyon disappeared, +1 anterior chamber reaction was seen, and the corneal edema began to resolve (Figure 4B). Steroid therapy was tapered slowly over a month and at 1 month his visual acuity returned to 20/20 and all clinical signs resolved (Figure 5).

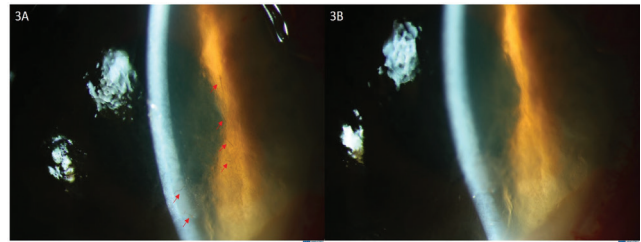


Figure 3. A) Numerous caterpillar hair (red arrows) embedded in cornea were visualized in slit-lamp examination using retroillumination from the iris. B) Corneal appearance after corneal debridement was performed under a surgical operating microscope

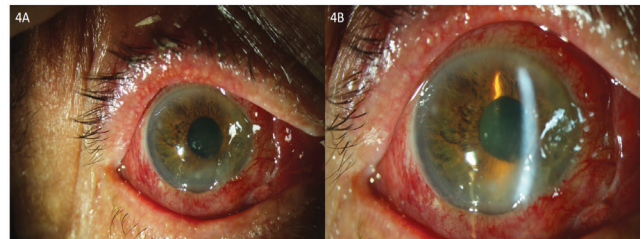


Figure 4. On post-treatment day 3, A) eyelid edema was decreased and B) conjunctival chemosis and hypopyon disappeared, corneal edema started to resolve

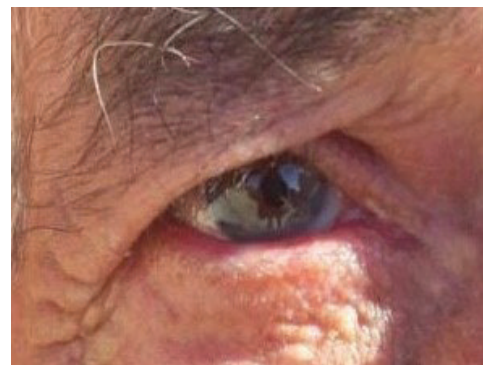

Figure 5. Photograph of the patient at post-treatment 1 month. Eyelid and anterior segment were totally quiet

Discussion

In this article, we report a rare condition called ophthalmia nodosa, which was misdiagnosed as fungal keratitis and later differentially diagnosed using IVCN. Although the disease was first described in the late 1800s, it is not generally well known by ophthalmologists.⁹ It is caused by a reaction to the hairs of a certain caterpillar which generally lives in pine forests but can be seen wherever pine trees are present. Therefore, the distribution of the disease includes warmer regions in southern Europe, the Near East, and North Africa with an expectation induced by global warming.²

The caterpillar is covered by abundant small, spined urticating hairs as a defense mechanism. When these hairs come into contact with the ocular surface, the clinical presentation may vary in a wide range from allergic conjunctivitis to endophthalmitis, since the hairs can penetrate into the eye.^{2,3,4,5,6,8,9,10} The diagnosis is based on patient history and clinically detected caterpillar hairs. However, because of the small size of the hairs, they cannot be seen in a routine slit-lamp examination and the diagnosis can be missed. In this patient, IVCN was instrumental in visualizing the caterpillar hairs and discriminating the clinical presentation from infectious keratitis. It was crucial for this patient that the treatment regimen was changed immediately from antifungal to steroid therapy.

In vivo confocal microscopy is a non-invasive, high-resolution, real-time device which is widely used for the diagnosis and treatment follow-up of many anterior segment diseases such as dry eye, keratitis, corneal dystrophies, post-refractive surgery, and post-keratoplasty. To the best of our knowledge, this is the second case in which IVCN was used as a diagnostic tool for caterpillar hairs, which appear as hyperreflective linear needle shapes with multiple small spines.¹¹ The diagnosis of ophthalmia nodosa may be very challenging in areas where these caterpillars are not common, and IVCN might assist with these specific findings.

It is important to be aware of the disease and treat immediately due to the penetration capacity of the hairs. In 2017, an entomology report pointed out that the insect responded to climate changes and insect distribution areas and their natural predators were waxing.¹ Therefore, in the near future many ophthalmologists may encounter this entity for the first time, which may result in late or misdiagnosis.

In conclusion, ophthalmologists should be aware of ocular conditions associated with caterpillar hairs and keep them in

mind in patients with organic traumas, especially when pine tree contact is present. In patients with insignificant history and clinically undetectable hairs, IVCN can be used as a diagnostic tool.

Ethics

Informed Consent: Obtained.

Peer-review: Externally peer reviewed.

Authorship Contributions

Surgical and Medical Practices: A.Ş, A.Y.T., B.N.B., Concept: A.Ş, A.Y.T., B.N.B., Design: A.Ş, A.Y.T., B.N.B., Data Collection or Processing: A.Ş, A.Y.T., B.N.B., Analysis or Interpretation: A.Ş, A.Y.T., B.N.B., Literature Search: A.Ş, A.Y.T., B.N.B., Writing: A.Ş, A.Y.T., B.N.B.

Conflict of Interest: No conflict of interest was declared by the authors.

Financial Disclosure: The authors declared that this study received no financial support.

References

1. Battisti A, Larsson S, Roques A. Processionary Moths and Associated Urtication Risk: Global Change-Driven Effects. *Annu Rev Entomol.* 2017;62:323-342.
2. Portero A, Carreno E, Galarreta D, Herreras JM. Corneal inflammation from pine processionary caterpillar hairs. *Cornea.* 2013;32:161-164.
3. Hornig CT, Chou PI, Liang JB. Caterpillar setae in the deep cornea and anterior chamber. *Am J Ophthalmol.* 2000;129:384-385.
4. Gonzalez-Martin-Moro J, Contreras-Martin I, Castro-Rebollo M, Fuentes-Vega I, Zarallo-Gallardo J. Focal cortical cataract due to caterpillar hair migration. *Clin Exp Optom.* 2019;102:89-90.
5. Conrath J, Hadjadj E, Balansard B, Ridings B. Caterpillar setae-induced acute anterior uveitis: a case report. *Am J Ophthalmol.* 2000;130:841-843.
6. Fraser SG, Dowd TC, Bosanquet RC. Intraocular caterpillar hairs (setae): clinical course and management. *Eye (Lond).* 1994;8:596-598.
7. Singh R, Tripathy K, Chawla R, Khokhar S. Caterpillar hair in the eye. *BMJ Case Rep.* 2017:2017.
8. Shibui H, Kawashima H, Kamata K, Sasaki H, Inoda S, Shimizu H. Vitrectomy for caterpillar seta-induced endophthalmitis. *Arch Ophthalmol.* 1997;115:555-556.
9. Teske SA, Hirst LW, Gibson BH, O'Connor PA, Watts WH, Carey TM. Caterpillar-induced keratitis. *Cornea.* 1991;10:317-321.
10. Agarwal M, Acharya MC, Majumdar S, Paul L. Managing multiple caterpillar hair in the eye. *Indian J Ophthalmol.* 2017;65:248-250.
11. Jullienne R, He Z, Manoli P, Grivet D, Cinotti E, Perrot JL, Labeille B, Cambazard E, Gain P, Thuret G. In vivo confocal microscopy of pine processionary caterpillar hair-induced keratitis. *Cornea.* 2015;34:350-352.



Unusual Association of Inverse Retinitis Pigmentosa, Scleromalacia, and Neovascular Glaucoma

© Ayşe Gül Koçak Altıntaş*, © Çağrı İlhan**, © Mehmet Çıtırık*

*University of Health Science, Ulucanlar Göz Training and Research Hospital, Clinic of Ophthalmology, Ankara, Turkey

**Hatay State Hospital, Clinic of Ophthalmology, Hatay, Turkey

Abstract

A 31-year-old woman with inverse retinitis pigmentosa presented with severe ocular pain and ingrained visual loss. Biomicroscopy revealed a large scleromalacia area above the superior limbus, minimal Descemet's membrane folds, aqueous flare, rubeosis iridis, and mature cataract. Intraocular pressure was 39 mmHg, and the clinical picture was consistent with neovascular glaucoma. After immediate medication to reduce ocular discomfort, an anterior chamber bevacizumab injection was performed. At 1 week post-injection, the rubeosis iridis had largely regressed and intraocular pressure was 21 mmHg. At post-injection 1 month, antiglaucomatous medication was discontinued because intraocular pressure was stable. Clear cornea, normal anterior chamber depth, and mature cataract were seen via biomicroscopy, and increased axial length with no significant change in posterior segment echogenicity were observed on ultrasonography. Three years after the single dose of bevacizumab, neovascularization was not seen in either the anterior chamber angle or on the iris surface, and intraocular pressure remained within normal range. The most important aspect of this case report is that it is the first to show an unusual association between neovascular glaucoma, scleromalacia, and inverse retinitis pigmentosa.

Keywords: Anti-vascular endothelial growth factor, inverse retinitis pigmentosa, intracameral bevacizumab, intraocular inflammation, neovascular glaucoma

Introduction

Retinitis pigmentosa (RP) is a heterogeneous group of inherited disorders characterized by photoreceptor and retinal pigment epithelium (RPE) abnormalities. It can be inherited in an autosomal dominant, autosomal recessive, or X-linked manner, and over 40 genes are associated with this group of retinal dystrophies.¹ Typical clinical symptoms are night blindness, reduced central vision, and visual field constriction. Mid-peripheral pigment migration, vascular attenuation, and disc pallor are the classical triad of retinal findings of RP.² Primary open-angle glaucoma, early-onset senile cataract, and

cystoid macular edema are relatively common complications of the disease, which accelerates permanent visual loss.²

Inverse RP is a rare form of RP that initially affects photoreceptors in the macula, causing significant visual impairment at very early stages of presentation. Autosomal recessive inheritance has been suggested. Many authors agree that this rare form of RP may correspond to cone-rod dystrophy with macular hyperpigmentation. However, diagnosis is difficult, and other inherited retinal disorders, such as Leber's congenital neurosis, progressive cone-rod dystrophy, and central areolar choroidal sclerosis should be excluded.³

Address for Correspondence: Çağrı İlhan, Hatay State Hospital, Clinic of Ophthalmology, Hatay, Turkey
Phone: +90 533 133 97 09 E-mail: cagrilhan@msn.com **ORCID-ID:** orcid.org/0000-0001-9122-2466

Received: 14.04.2019 **Accepted:** 02.03.2020

Cite this article as: Koçak Altıntaş AG, İlhan Ç, Çıtırık M. Unusual Association of Inverse Retinitis Pigmentosa, Scleromalacia, and Neovascular Glaucoma. Turk J Ophthalmol. 2020;50:110-114

©Copyright 2020 by Turkish Ophthalmological Association
Turkish Journal of Ophthalmology, published by Galenos Publishing House.

In this case report, we present a patient with an unusual association of inverse RP, scleromalacia, and neovascular glaucoma (NVG), which was treated with an intracameral anti-vascular endothelial growth factor (VEGF). To the best of our knowledge, this is the first report to show an association between RP and anterior segment neovascularization and scleromalacia.

Case Report

A 31-year-old woman presented with ocular pain and ingrained visual loss in her left eye. The best corrected visual acuity (BCVA) was counting fingers at 1 m in the right eye and light perception (LP) with projection in the left eye. Biomicroscopy revealed a 2+ cataract in the right eye and a large scleromalacia area over the superior limbus, minimal Descemet's membrane folds, aqueous flare, rubeosis iridis, and 4+ cataract in the left eye (Figure 1). Intraocular pressures (IOP) were 20 mmHg and 39 mmHg in the right and left eye, respectively. Waxy pallor optic disc, attenuation in retinal arterioles, and hyper- and hypopigmented RPE changes forming 'bone spicules' scattered in the posterior pole up to the equator, along with pigment clumping in both macular zones were seen, which are the classic clinical findings of inverse RP.

Clear color and red-free fundus photographs of the right retina could be taken after pupil dilation with 1% tropicamide due to relatively dense cataract (Figures 2 and 3). Fundus fluorescein angiography (FFA) showed central hypofluorescence due to contrasting blockage in areas with pigment accumulation and patchy hyperfluorescence due to window defects in the RPE atrophy areas. On optical coherence tomography (OCT), loss of photoreceptors, external limiting membrane, ellipsoid zone, and discontinuity of the outer retinal structures were seen (Figure 4). In B-mode ultrasonography of the left eye, the retina was attached, and there was no increase of echogenicity in the vitreous cavity. The axial length of the globe was detected as 24.58 mm on A-mode ultrasonography, which was

nearly 2 mm longer than in the right eye. Electroretinography revealed significantly decreased amplitudes in all five recordings (rod, maximum, oscillatory, cone, and flicker) ($p < 0.05$). The amplitude of b-waves in the rod, maximum, and cone responses was also reduced. Oscillatory P2 peak and flicker amplitudes also showed reduction in the recordings (Figure 5).

The patient had been receiving a combination of topical brinzolamide+0.5% timolol (1%), 0.2% brimonidine, and oral 250 mg acetazolamide 4 times a day for a week. To reduce ocular

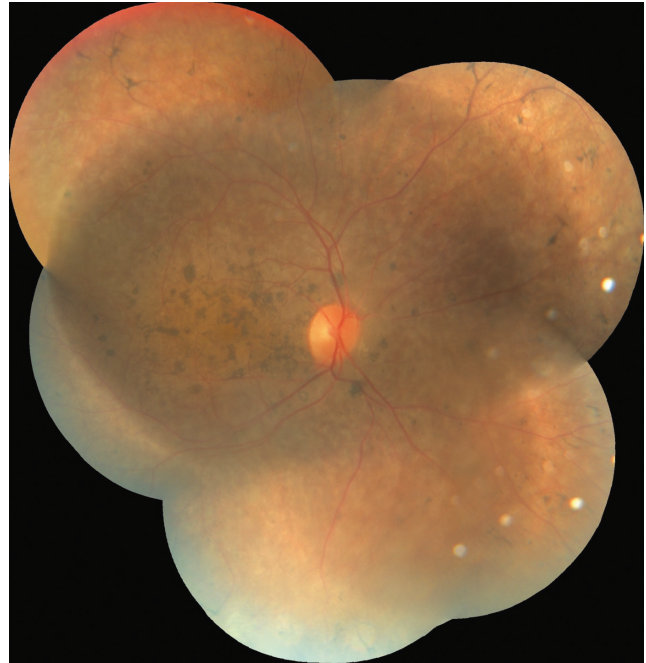


Figure 2. Color fundus photograph of the right retina

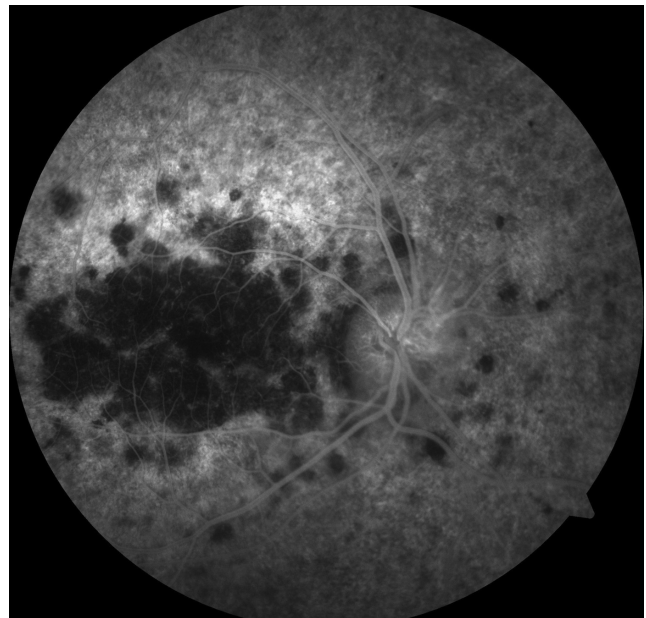


Figure 3. Red-free fundus photograph of the right retina

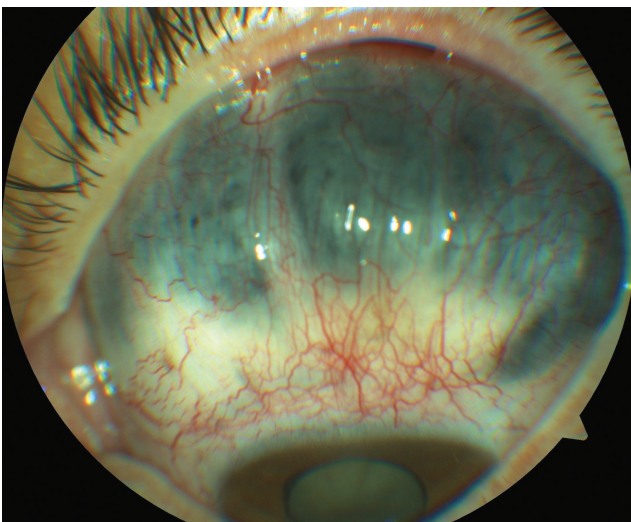

Figure 1. Large scleromalacia area over the superior limbus

discomfort, 600 cc intravenous mannitol was administered. IOP was then only slightly reduced to 30 mmHg, and her ocular discomfort did not improve significantly. To induce regression of the rubeosis iridis, 1.25 mg/0.05 mL bevacizumab was injected into the anterior chamber. At 1 week post-injection, the rubeosis iridis was seen to have largely regressed and IOP was 21 mmHg.

The patient was instructed to continue using topical antiglaucomatous medication. At 1 month post-injection, the rubeosis iridis was observed to have completely regressed, IOP was 16 mmHg, and the patient had no ocular discomfort except low vision. All topical drugs were terminated and cataract extraction was suggested; however, the patient refused.

The patient was born from a consanguineous marriage of first-degree cousins and her siblings had also had RP, while the parents had no ocular disease. There was no history of past ocular diseases, surgery, trauma, systemic diseases, or drug use. There were no previous ocular inflammation or infection-related findings including corneal leukoma, corneal vascularization, lipid keratopathy, seclusion pupil, or sectoral iris atrophy in anterior segment examination. There was no any sign of intraocular or orbital tumor-suspected lesion in ocular B-scan ultrasonography or orbital computed tomography. To investigate the presence of scleromalacia or rubeosis iridis-related inflammatory or ischemic conditions, the patient was referred to an experienced internal disease specialist. After a physical

examination, laboratory, and radiological investigations, no systemic disease was found, including diabetes mellitus, systemic lupus erythematosus, immune deficiency, leukemia/lymphoma, or plasma cell diseases. The absence of carotid artery stenosis was reported by the radiologist. No additional risk factor for presence of scleromalacia or NVG was found in any of these extensive evaluations.

Three years later, her IOP levels were 13 mmHg and 16 mmHg without medication. The anterior segment of the right eye was completely normal except for the 2+ cataract, while the left eye exhibited clear cornea, normal anterior chamber depth, an irregular moth-eaten atrophic iris, and minimal pupillary light response, along with 4+ cataract. No

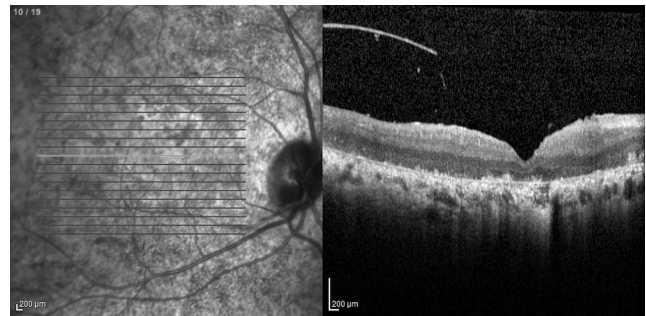


Figure 4. Optical coherence tomography of the right retina

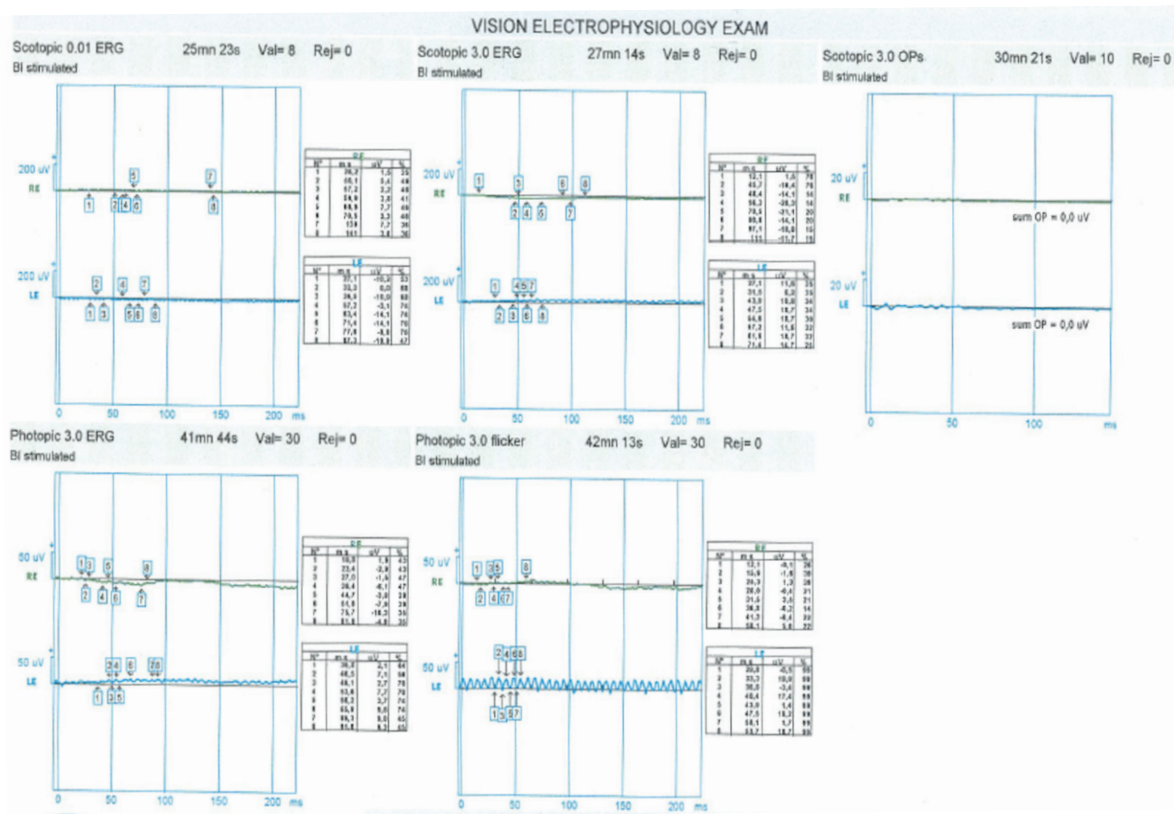


Figure 5. Electroretinography of the right retina

neovascularization in the anterior chamber angle was seen in either eye by gonioscopy. Posterior segment findings of the right eye were stable on funduscopy, FFA, and OCT, while the left eye retina was attached without increased echogenicity on B-mode ultrasonography. There were still no findings of any diagnosed systemic inflammatory or ischemic diseases and no use of any drugs. Written informed consent was obtained from the patient to use her medical records for academic purposes.

Discussion

The presence of NVG and rubeosis iridis in a case of inverse RP was very unexpected. The most common cause of NVG is retinal vein occlusion, especially an ischemic type central retinal vein occlusion.⁴ To the best of our knowledge, there is only one report in the literature that mentions ischemic central retinal vein occlusion in a patient with RP.⁵ In this case, possible past ischemic central retinal vein occlusion may have been the cause of rubeosis iridis and NVG. Even in this hypothesis, NVG can be explained with ischemic central retinal vein occlusion; however, the reason for dense cataract presentation in the same eye in a 31-year-old patient could not be explained. While early-onset senile cataracts occur in RP, this patient was very young and the cataracts in both eyes were significantly asymmetrical.² The exact reason for progression of pathological new vessels could not be determined because the posterior segment of the globe was covered by cataract. This is the most significant disadvantage of this study, that the definitive cause of rubeosis iridis and NVG in a patient with RP could not be clarified.

Some reports have mentioned the coexistence of retinal neovascularization and RP.^{6,7,8} One of these mentioned the presence of NVG in RP.⁸ However, the patient in that report had multiple ocular comorbidities including cataract, vitreous hemorrhage, subretinal exudation, and diffuse posterior pole edema.⁸ The patient had multiple ocular surgeries before NVG, including bilateral lens extraction and retinal detachment surgery on the fellow eye.⁸ The patient underwent multiple systemic steroid treatments, and there was no comprehensive investigation about NVG-related systemic inflammatory or ischemic conditions.⁸ Therefore, the relationship between NVG and RP was unclear and disputable in that case because there were many NVG-related risk factors other than RP. In contrast, NVG in our RP patient, who had no history of ocular surgery, was not associated with any other known ocular condition. In addition, the patient had no systemic NVG-related condition or history of steroid use. Therefore, it can still be argued that this case is the first presentation of NVG in a patient with RP.

Recurrent anterior uveitis attacks can be observed in RP; however, they generally do not cause neovascularization. Extensive ocular inflammatory diseases, including choroiditis, panuveitis, or scleritis can be reasons for general ocular ischemia and scleromalacia.⁹ These diseases may explain unilateral NVG and cataract, and some may result in scleromalacia. A weak

point of this hypothesis is there was no history of severe ocular inflammatory diseases or clinical findings of past uveitis, such as synechiae, keratic precipitates, pigment on the anterior lens capsule, etc. The exact mechanism of anterior segment neovascularization in this case remains unclear and it should not be completely ruled out that the relationship between RP, scleromalacia, and NVG may be just a coincidence.

Bevacizumab is a humanized monoclonal antibody that affects all VEGF isoforms. Its injection into the anterior chamber can provide a rapid regression of neovascularization on both the iris surface and anterior chamber angle.¹⁰ In the current case, IOP decreased to a normal level 1 week after the intracameral anti-VEGF injection. Throughout the 3-year follow-up, stable IOP was provided with a single injection, without additional medication. A 3-year follow-up period is sufficient for the treatment of NVG, and as far as we know, this is the longest period showing the efficacy of a single dose of intracameral bevacizumab. In addition, to the best of our knowledge, this is the first case of a patient with scleromalacia receiving intracameral bevacizumab injection without any long-term complications. Although the pathogenesis of the anterior chamber neovascularization could not be fully explained, one of the most important aspects of this study is that this is the first report to show the association of NVG, scleromalacia, and RP.

Ethics

Informed Consent: Obtained.

Peer-review: Externally and internally peer reviewed.

Authorship Contributions

Surgical and Medical Practices: A.K.A., Concept: A.K.A., C.I., M.C., Design: A.K.A., C.I., M.C., Data Collection or Processing: A.K.A., C.I., Analysis or Interpretation: A.K.A., C.I., M.C., Literature Search: C.I., M.C., Writing: A.K.A., C.I., M.C.

Conflict of Interest: No conflict of interest was declared by the authors.

Financial Disclosure: The authors declared that this study received no financial support.

References

1. Ferrari S, Di Iorio E, Barbaro V, Ponzin D, Sorrentino FS, Parmeggiani F, et al. Retinitis pigmentosa: Genes and disease mechanisms. *Curr Genomics*. 2011;12:238-249.
2. Davies EC, Pineda R 2nd. Cataract surgery outcomes and complications in retinal dystrophy patients. *Can J Ophthalmol*. 2017;52:543-547.
3. Díez-Cattini GF, Ancona-Lezama DA, Valdés-Lara C, Morales-Cantón V. The unusual association of inverse retinitis pigmentosa and Fuchs' heterochronic iridocyclitis. *Int J Retina Vitreous*. 2017;3:3.
4. Hayreh SS, Rojas P, Podhajsky P, Montague P, Woolson RF. Ocular neovascularization with retinal vascular occlusion-III. Incidence of ocular neovascularization with retinal vein occlusion. *Ophthalmology*. 1983;90:488-506.
5. Paxhia MJ, Ting TD, Fekrat S. Ischemic central retinal vein occlusion and retinitis pigmentosa: lower risk of neovascularization? *Retina*. 2001;21:179-180.

6. Butner RW. Retinitis pigmentosa and retinal neovascularization: a case report. *Ann Ophthalmol.* 1984;16:861,863-865.
7. Preethi S, Rajalakshmi AR. Proliferative diabetic retinopathy in typical retinitis pigmentosa. *BMJ Case Rep.* 2015 May 28;2015. pii: bcr2014208589.
8. Uliss AE, Gregor ZJ, Bird AC. Retinitis pigmentosa and retinal neovascularization. *Ophthalmology.* 1986;93:1599-1603.
9. Pichi F, Sarraf D, Arepalli S, Lowder CY, Cunningham ET Jr, Neri P, Albini TA, Gupta V, Baynes K, Srivastava SK. The application of optical coherence tomography angiography in uveitis and inflammatory eye diseases. *Prog Retin Eye Res.* 2017;59:178-201.
10. Altintas AG, Arifoglu HB, Tutar E, Koklu G, Ozcan PY. Effect on anterior chamber bevacizumab injection combined with seton implantation in treatment of rubeosis iridis in neovascular glaucoma *Cuban Ocul Toxicol.* 2012;31:124-127.



Anterior Chamber Migration of Ozurdex Implants

Özcan Kayıkcıoğlu*, Suzan Doğruya**, Cansu Sarıgül*, Hüseyin Mayalı*, Emin Kurt*

*Celal Bayar University Faculty of Medicine, Department of Ophthalmology, Manisa, Turkey

**Uşak University Training and Research Hospital, Clinic of Ophthalmology, Uşak, Turkey

Abstract

We present patient characteristics and follow-up results of cases with anterior chamber dexamethasone implant migration. The common feature of all six presented cases was vitrectomized eyes. Four of the patients had sutured intraocular lens (IOL) implantation due to complicated cataract surgery, one had combined retinal detachment surgery with sutured IOL implantation, and one had vitrectomy for diabetic intravitreal hemorrhage cleaning and uncomplicated cataract surgery. Anterior chamber implant migration caused corneal edema in all cases and elevated intraocular pressure in three cases. In two cases, the dexamethasone implant was directed into the vitreous cavity after maximum pupillary dilation and corneal manipulation with cotton tip applicator with the patient in reverse Trendelenburg position. There was no other complication until dexamethasone implant degradation, with clear cornea at final examination. In two cases, the implant was removed from the anterior chamber by aspiration, but keratoplasty surgery was planned due to endothelial cell loss and persistent corneal edema during follow-up. In the last two cases, the dexamethasone implant was redirected into the vitreous chamber with a 23-gauge catheter and anterior chamber maintainer but they migrated into the anterior chamber again. In one of these patients, the implant was aspirated by catheter and corneal transplantation was performed due to corneal edema, while the other patient's implant was redirected into the vitreous chamber with no further anterior migration. The risk of dexamethasone implants migrating into the anterior chamber of vitrectomized eyes and those with sutured IOL implantation should be kept in mind and the patient should be informed and advised to see an ophthalmologist immediately before permanent corneal endothelial damage occurs.

Keywords: Dexamethasone implant, phacoemulsification, corneal edema, pars plana vitrectomy

Introduction

Ozurdex (Allergan Inc. Irvine, CA, USA) is a rod-shaped, biodegradable dexamethasone implant 6 mm in length and 0.46 mm in diameter that is injected into the intravitreal cavity using a 22-gauge needle. It is effective in the treatment of macular edema due to retinal vein occlusion, non-infectious uveitis affecting the posterior segment, and diabetic macular edema.^{1,2,3} After implantation, the Ozurdex polymer matrix releases 0.7 mg preservative-free dexamethasone into the intravitreal cavity and degrades into lactic acid and glycolic acid. The most common

complication reported after dexamethasone implantation is an increase in intraocular pressure, which peaks at about 3 months.^{4,5} In addition to the side effects of dexamethasone reported in the literature, such as cataracts and increased intraocular pressure, the implantation procedure itself involves the risk of complications like dislocation to the anterior chamber, corneal endothelial damage, secondary corneal edema, and implantation in the lens.^{6,7,8} Migration of a dexamethasone implant into the anterior chamber is a rare complication that can be managed by directing the implant back into the vitreous cavity or removing it from the anterior chamber through a corneal incision.^{7,9,10} In

Address for Correspondence: Suzan Doğruya, Uşak University Training and research Hospital, Clinic of Ophthalmology, Uşak, Turkey
Phone: +90 532 227 07 32 E-mail: sdogruya@hotmail.com **ORCID-ID:** orcid.org/0000-0002-6822-9077

Received: 08.05.2019 **Accepted:** 25.12.2019

Cite this article as: Kayıkcıoğlu Ö, Doğruya S, Sarıgül C, Mayalı H, Kurt E. Anterior Chamber Migration of Ozurdex Implants. Turk J Ophthalmol. 2020;50:115-122

this series of six cases, we discuss risk factors, clinical course, and treatment approaches for migration of dexamethasone implants to the anterior chamber.

Case Report

Patients who underwent dexamethasone implantation in the ophthalmology department of Manisa Celal Bayar University Faculty of Medicine within the past 5 years and had anterior chamber dislocation of the implants during follow-up are discussed in terms of etiologies, treatment approaches, and outcomes.

Case 1

A 63-year-old man was being followed in our retina unit after undergoing pars plana vitrectomy (PPV) with silicone oil injection due to retinal detachment in the left eye, followed by silicone removal 4 months later. At last examination, his Snellen visual acuity was 0.7 in the right eye and 0.15 in the left eye. Intraocular pressure (IOP) was 14 mmHg in the right eye and 16 mmHg in the left eye. On slit-lamp examination, nuclear cataract was observed in the right eye, while pseudophakia, posterior capsule defect, and zonular dialysis were observed in the left eye. Fundus examination was normal in the right eye and showed attached retina and peripheral cryotherapy and laser scars in the left eye. On optical coherence tomography (OCT) imaging, the right eye appeared normal, while cystoid macular edema (central macular thickness: 577 μm) was observed in the left eye (Figure 1). Fundus fluorescein angiography (FFA) imaging revealed diffuse hyperfluorescence consistent with macular edema. The patient received a dexamethasone implant for post-vitrectomy macular edema. At 1-week follow-up after implantation, severe corneal edema was observed on slit-lamp examination. IOP was measured as 42 mmHg. After lowering his IOP to within normal range with medical treatment, two dexamethasone implants were observed situated at the angle in the anterior chamber (Figure 2). Both implants were removed from the anterior chamber by aspirating with a 23-gauge (G) catheter. Both were found to be their original size and were evaluated as newly implanted. There was no record of the administration of a second implant in our clinic, and sufficient information could not be obtained from the patient regarding the second implant. He reported that he was also being followed up by other ophthalmologists at another center. At 6-month follow-up, he exhibited bullous keratopathy and irreversible permanent endothelial damage. He was evaluated in the cornea unit and keratoplasty was planned (Figure 3).

Case 2

A 60-year-old woman who was referred to our clinic from another center due to complicated cataract surgery underwent PPV and sutured intraocular lens (IOL) implantation. In the last examination, her Snellen visual acuity was 0.1 in the right eye and 1.0 in the left eye, while IOP was 19 mmHg in the right eye and 18 mmHg in the left eye. On fundus examination, the macula was elevated and optic disc was normal in the right eye, while the left eye was entirely normal. OCT revealed cystoid

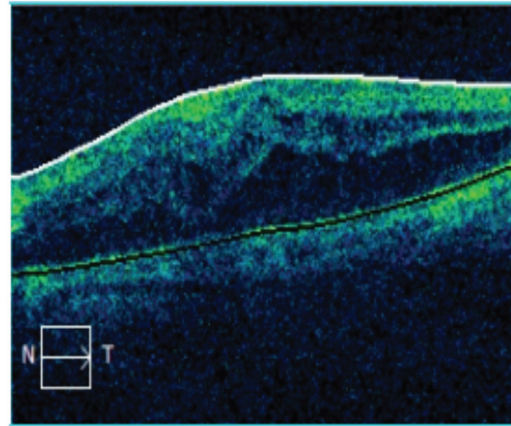


Figure 1. Follow-up OCT shows cystoid macular edema in a patient who underwent PPV with silicone oil injection due to left retinal detachment (Case 1) OCT: Optical coherence tomography, PPV: Pars plana vitrectomy

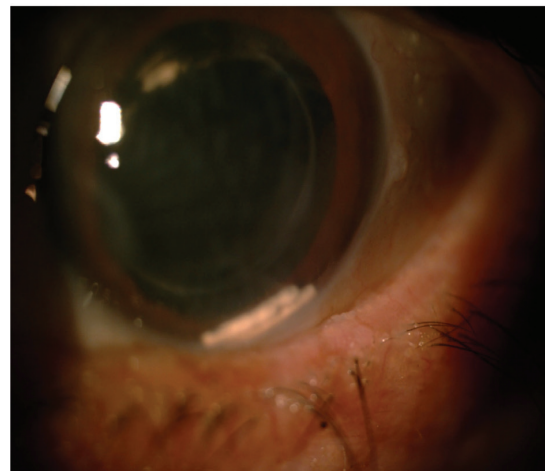


Figure 2. Two implants are observed in the anterior chamber of a patient who was given a dexamethasone implant due to post-vitrectomy macular edema and did not regularly attend follow-up visits (Case 1)

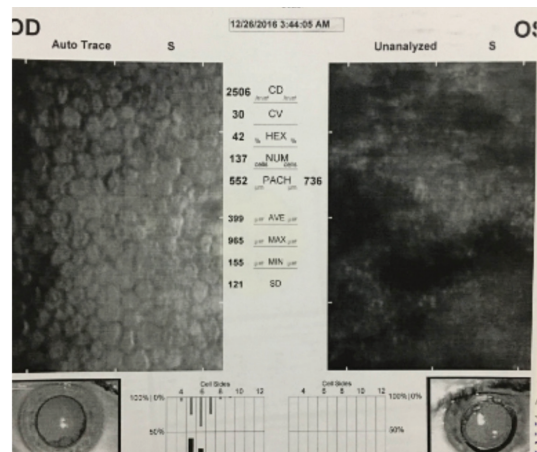


Figure 3. Follow-up specular microscopy reveals a decrease in corneal endothelial cell number after the removal of two dexamethasone implants from the anterior chamber (Case 1)

edema in the right eye and normal findings in the left eye. FFA imaging in the right eye showed late-phase hyperfluorescence in the macula, and it was decided to treat her right eye with dexamethasone implant. In examination performed 2 weeks after implantation, the right eye exhibited mild corneal edema and the dexamethasone implant was visible in the anterior chamber (Figure 4). Fundus examination showed retinal attachment. After inducing pupil dilation, the patient was placed in the reverse Trendelenburg position and the implant was directed into the vitreous cavity under topical anesthesia by corneal manipulation with a sterile cotton tip applicator. After mydriasis subsided, the patient was advised to avoid bending over forward and to sleep in a 45-degree upright position until the implant degraded. At follow-up examination, clear cornea and calm anterior chamber were observed on slit-lamp examination of the patient's right eye. On fundus examination, the retina was attached and the dexamethasone implant was observed in the inferior hemisphere. The implant did not appear in the anterior chamber again before dissolving over the follow-up period of 5 months.

Case 3

A 61-year-old man with proliferative diabetic retinopathy who underwent PPV, endolaser, and phacoemulsification with IOL implantation in the right eye and PPV and endolaser in the left eye due to bilateral intravitreal hemorrhage was being followed up in our retina unit. At last examination, visual acuity was 0.05 cm in the right eye and counting fingers at 50 cm in the left eye, while intraocular pressure was 17 mmHg in the right eye and 16 mmHg in the left eye. Slit-lamp examination revealed pseudophakia and clear cornea in the right eye and posterior subcapsular cataract in the left eye. On fundus examination, cellophane maculopathy, laser scars in the periphery, and macular edema were observed in the right eye. Laser scars and macular microhemorrhages were observed in the left eye. Bilateral cystoid macular edema was noted on OCT. No response was achieved despite 4 bilateral intravitreal

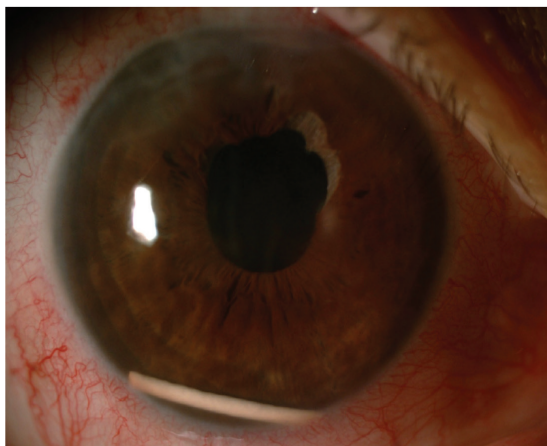


Figure 4. A dexamethasone implant given to treat macular edema in a patient who underwent PPV with sutured IOL implantation after cataract surgery is detected in the anterior chamber (Case 2)

PPV: Pars plana vitrectomy, IOL: Intraocular lens

ranibizumab injections, so the decision was made to administer dexamethasone implants. Slit-lamp examination at 1-month follow-up after dexamethasone implantation revealed corneal edema and the dexamethasone implant was seen in the anterior chamber of the right eye (Figure 5). Using a 23-G catheter and anterior chamber maintainer, the implant was moved from the anterior chamber and directed to the vitreous cavity through the zonular area. At follow-up 9 months after implantation, an increase in cystoid macular edema was observed and the patient was given a second dexamethasone implant. No complications related to the dexamethasone implant were noted during follow-up. Due to clinical and OCT findings of recurrent cystoid macular edema at 7-month follow-up, a third dexamethasone implant was administered (Figure 6). At follow-up examination 2 weeks after implantation, the cornea exhibited edema and bullae, and the dexamethasone implant was again seen in the anterior chamber (Figure 7). Using a 23-G catheter and anterior chamber maintainer, the implant was removed from the anterior chamber and repositioned in the vitreous cavity. Regression of the corneal edema was observed on follow-up examination.

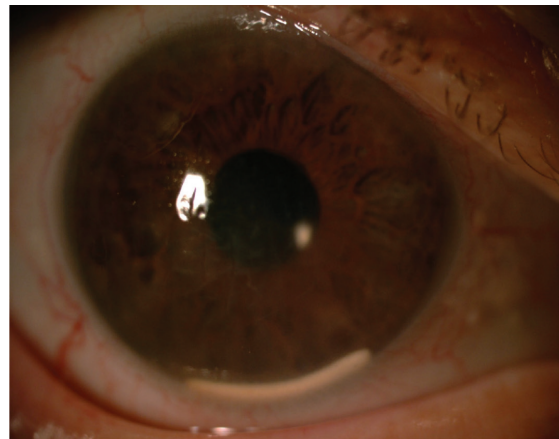


Figure 5. A dexamethasone implant given to treat macular edema in a patient with intravitreal hemorrhage due to proliferative diabetic retinopathy who underwent PPV and endolaser therapy is seen in the anterior chamber (Case 3)

PPV: Pars plana vitrectomy

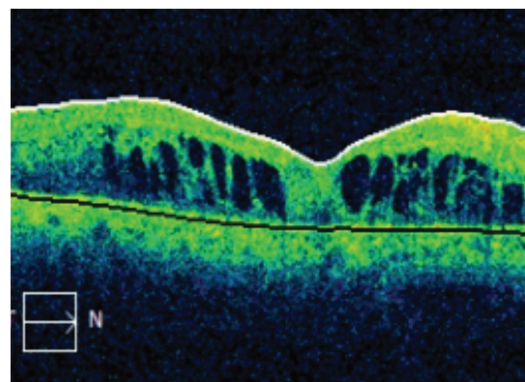


Figure 6. OCT shows persistent macular edema in a patient given dexamethasone implants to treat macular edema due to proliferative diabetic retinopathy (Case 3)

OCT: Optical coherence tomography

Case 4

A 79-year-old woman who was referred to our clinic from another center for complicated cataract surgery underwent left PPV and sutured IOL implantation. At last examination, her Snellen visual acuity was 0.6 in the right eye and counting fingers at 3 m in the left eye; IOP was 16 mmHg in the right eye and 14 mmHg in the left eye. Both eyes were found to be pseudophakic on slit-lamp examination. Fundus examination revealed irregularity of the retinal pigment epithelium in the right eye and laser scars in the inferior hemisphere of the left eye. OCT findings were normal in the right eye, while spongy edema was observed in the left eye. FFA imaging showed macular edema with traction in the inferotemporal quadrant of the left eye, and it was decided to administer a dexamethasone implantation. The implant appeared in the anterior chamber 15 days later (Figure 8). After pupillary dilation, the patient was placed in the reverse Trendelenburg position and the implant was directed into the vitreous cavity by corneal manipulation with a sterile cotton tip applicator. After mydriasis subsided, the patient was advised to

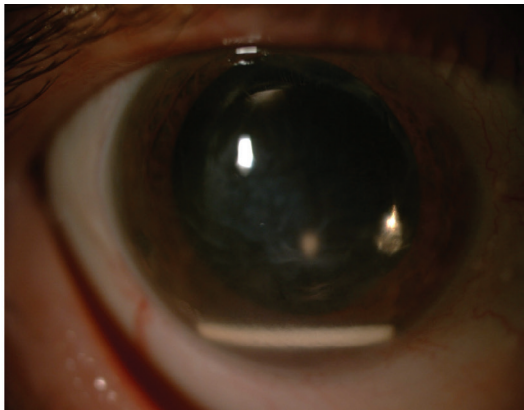


Figure 7. Anterior chamber migration of the implant was observed at follow-up in a patient who received a third dexamethasone implant due to macular edema (Case 3)

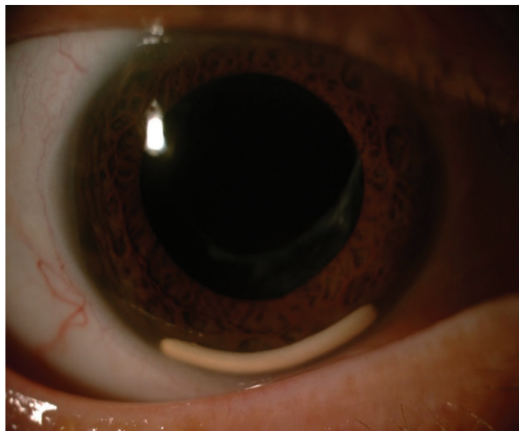


Figure 8. A dexamethasone implant given to treat macular edema in a patient who underwent PPV with sutured IOL implantation after complicated cataract surgery is observed in the anterior chamber (Case 4)

PPV: Pars plana vitrectomy, IOL: Intraocular lens

avoid bending over forward and to sleep in a 45-degree upright position until the implant degraded. At follow-up examination, the dexamethasone implant had degraded and the cornea was clear (Figure 9).

Case 5

A 73-year-old man who was referred to our clinic from another center due to traumatic cataract and zonular dialysis underwent left PPV and anterior vitrectomy, followed by scleral-fixated IOL implantation 2 months later. In ophthalmologic examination at postoperative 2 months, his Snellen visual acuity was 0.9 in the right eye and counting fingers at 1 m in the left eye, while IOP was 12 mmHg in the right eye and 18 mmHg in the left eye. Both eyes appeared pseudophakic on slit-lamp examination. Fundus examination revealed macular retinal pigment epithelial irregularity in the macula in both eyes. On OCT, the right eye was normal, while macular edema (447 μ m) was observed in the left eye. The right eye showed no leakage on FFA imaging, while the left eye showed macular edema and areas of hyperfluorescence. A dexamethasone implant was injected into the left eye. The patient presented to the clinic 25 days after implantation with further visual deterioration (hand

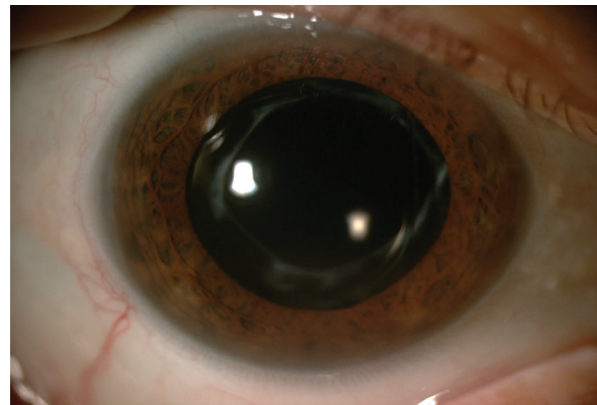


Figure 9. Clear cornea is observed at follow-up after guiding the dexamethasone implant from the anterior chamber back into the vitreous cavity (Case 4)

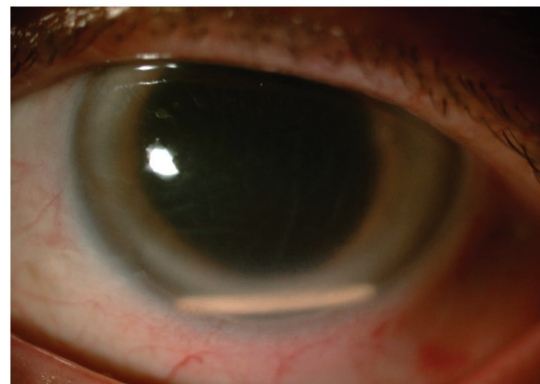

Figure 10. A dexamethasone implant given to treat macular edema in a patient who underwent PPV with scleral-fixated IOL implantation due to traumatic cataract is seen in the anterior chamber (Case 5)

PPV: Pars plana vitrectomy, IOL: Intraocular lens

movements). The implant was observed in the anterior chamber of the left eye on slit-lamp examination (Figure 10). Using a 23-G catheter and anterior chamber maintainer, the implant was removed from the anterior chamber and repositioned in the vitreous cavity. However, the dexamethasone implant appeared in the anterior chamber again the next day (Figure 11). The implant was removed from the anterior chamber by aspiration with a 23-G catheter. Follow-up examinations revealed corneal edema and visual acuity of counting fingers at 10 cm in the left eye. Upon development of bullous keratopathy, the patient was evaluated in the cornea unit and underwent keratoplasty 8 months later (Figure 12).

Case 6

A 70-year-old man who was being followed up in our clinic for angle-closure glaucoma underwent left PPV and phacoemulsification, followed by scleral-fixated IOL implantation 6 months later. At last examination, his Snellen visual acuity was 1.0 in the right eye and 0.2 in the left eye; IOP was 12 mmHg in the right eye and 17 mmHg in the left eye. On slit-lamp examination, shallow anterior chamber and patent iridotomy were observed in the right eye and clear cornea, iridotomy, centered IOL, and iris atrophy in the superior quadrant were observed in the left eye. On fundus examination, cup-to-disc

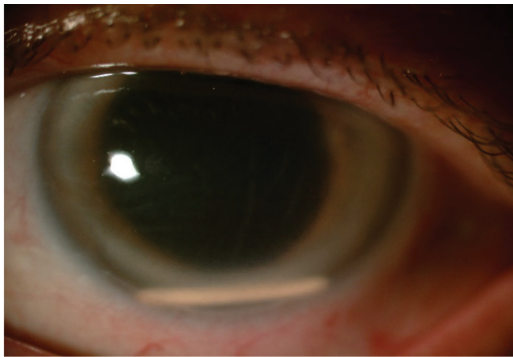


Figure 11. The dexamethasone implant migrated to the anterior chamber again the day after being repositioned in the vitreous cavity using 23-gauge catheter (Case 5)

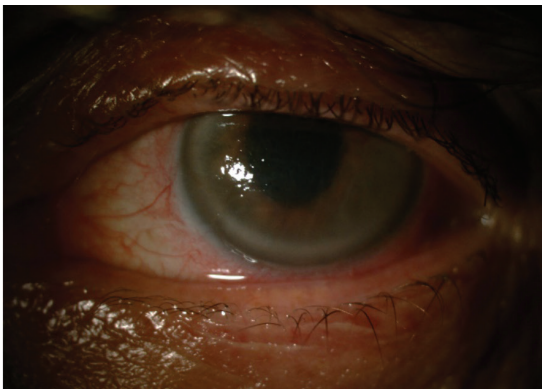


Figure 12. Bullous keratopathy is observed at follow-up after the dexamethasone implant that migrated to the anterior chamber twice was removed with a 23-gauge catheter (Case 5)

ratio was normal in the right eye and 0.3 in the left eye. OCT findings were normal in the right eye, while macular edema (434 μm) was present in the left eye. On FFA imaging, there was no leakage in the right eye, while the left eye showed macular edema with late-phase hyperfluorescent areas. The patient received 5 intravitreal ranibizumab injections. Due to macular edema (550 μm), it was decided to administer a dexamethasone implant. Twenty days after implantation, the patient presented to the clinic with complaints of vision loss. His visual acuity was at the level of hand movements in the left eye, and slit-lamp examination revealed corneal edema and the dexamethasone implant in the anterior chamber (Figure 13). His IOP was 22 mmHg with topical and systemic treatment. The implant was removed by aspiration with a 23-G catheter. In follow-up examinations, corneal edema and bullous keratopathy were detected in his left eye. He was assessed in the cornea unit and keratoplasty was planned.

The characteristics and outcomes of patients with dexamethasone implant migration from the vitreous cavity to the anterior chamber are presented in Table 1.

Discussion

In this study, we present information pertaining to patients who were followed up and treated for dislocation of dexamethasone implants into the anterior chamber. The patients included 3 women and 3 men between the ages of 60 and 79 years. All of the affected eyes were vitrectomized and pseudophakic. One patient (Case 1) had posterior capsule defect, zonular dialysis, and IOL implantation in the sulcus, 4 patients (Cases 2, 4, 5, and 6) had undergone sutured IOL implantation after complicated cataract surgery, and 1 patient (Case 3) had undergone intracapsular IOL implantation with no posterior capsule defect. Anterior chamber migration of a dexamethasone implant is a rare complication and risk factors include previous vitrectomy, aphakic eyes, posterior capsule opening, and lying in prone position.^{7,11} Long plane journeys within the first week after dexamethasone implantation were also reported to be a risk factor for anterior chamber dislocation by increasing vitreous pressure

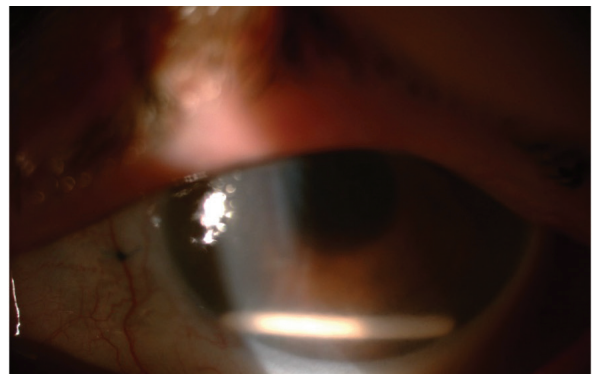


Figure 13. Anterior chamber migration of a dexamethasone implant given to treat macular edema is observed in a patient who underwent pars plana vitrectomy and scleral-fixated IOL implantation (Case 6)

IOL: Intraocular lens

Table 1. The characteristics and outcomes of patients with dexamethasone implant migration from the vitreous cavity to the anterior chamber

Patient	Age (years), sex	Diagnosis	Lens status	AC migrations	AC migration time (days)	Management	Cornea
1	63, M	Retinal detachment	Sulcus IOL	1	7	Aspiration with 23-gauge catheter (2 implants)	Bullous keratopathy
2	60, F	Nucleus drop	Sutured IOL	1	14	Reverse Trendelenburg position	Clear
3	61, M	Intravitreal hemorrhage	PC IOL	2	30 14	Surgical repositioning	Clear
4	79, F	Nucleus drop	Sutured IOL	1	15	Reverse Trendelenburg position	Clear
5	73, M	Traumatic cataract	Sutured IOL	2	25 1	Surgical repositioning, Aspiration with 23-gauge catheter	Bullous keratopathy; Keratoplasty
6	70, F	Angle-Closure Glaucoma, Cataract	Sutured IOL	1	20	Aspiration with 23-gauge catheter	Bullous keratopathy

IOL: Intraocular lens, PC-IOL: Posterior chamber IOL, AC: Anterior chamber

due to changes in air pressure.¹² The clinical findings and risk factors of our patients were consistent with the information in the literature. All of our patients had undergone PPV and had posterior capsule defect and/or zonular dialysis.

In the event of a dexamethasone implant in the anterior chamber, the implant can be removed from the anterior chamber via a corneal incision or directed back into the vitreous cavity.¹³ In addition, spontaneous return of the implant to the vitreous cavity has also been reported.¹⁴ The procedure of guiding the implant back into the vitreous cavity by placing the patient in supine position after pupil dilation was first described by Kishore and Schaal.⁹ Mateo et al.¹⁵ reported scleral fixation of the dexamethasone implant using a 10-0 suture. In 2 of our patients with dexamethasone implant in the anterior chamber (patients 2 and 4), the patients were placed in reverse Trendelenburg position after pharmacological dilation and the implant was guided back into the vitreous cavity by manipulating the cornea with a sterile cotton tip applicator. In 2 other patients (patient 3 and patient 5 after first migration), the implant was moved from the anterior chamber back into the vitreous cavity using a 23-G catheter and anterior chamber maintainer. In the patients with severe corneal edema and elevated IOP (patients 1, 6, and 5 after second migration), the dexamethasone implant was removed from the anterior chamber using a 23-G catheter. One of the 2 dexamethasone implants detected in the anterior chamber in patient 1 was implanted in our center, while the other was most likely implanted as a second dose within a short period at another center. This could not be explained conclusively.

Khurana et al.⁷ reported that corneal edema developed when anterior chamber migration occurred within the first

3 weeks after dexamethasone implantation, but did develop in migrations occurring between 5 weeks and 3 months after implantation. All of the patients in our series presented with early migration, within 1 month of implantation, and severe corneal edema was observed in 3 of the patients (patients 1, 5, and 6). Keratoplasty was planned for patient 6 and patient 1, who had 2 implants in the anterior chamber, due to persistent bullous corneal changes and very low endothelial cell counts. Patient 5 underwent keratoplasty due to bullous keratopathy and corneal endothelial failure. The patients who did not develop corneal edema were those who presented to our clinic promptly after onset of their complaints and received rapid intervention.

Kang et al.¹⁶ retrospectively analyzed 924 cases of intravitreal dexamethasone injection. Anterior chamber migration of the implant occurred in 4 patients within 2 to 6 weeks. In 2 patients, the implant was guided back into the vitreous cavity. In the other 2 patients, implant migration occurred twice in one and 3 times in the other before the implants were surgically removed. One of the patients underwent keratoplasty. All of the affected eyes lacked posterior capsule integrity.¹⁶ In our case series, 2 dexamethasone implants were detected in the anterior chamber of 1 patient (Case 1). They were removed from the anterior chamber by aspiration using a 23-gauge catheter. Keratoplasty was planned for this patient in the cornea unit because he developed bullous keratopathy and corneal endothelial decompensation. In the case of 2 other patients (Cases 2 and 4), the implant was maneuvered back into the vitreous cavity by applying pressure to the cornea with a sterile cotton tip applicator with the patient in supine position after pupil dilation and reverse Trendelenburg positioning. This resulted in no further problems until implant

degradation and the cornea was clear at final examination. In 2 of our patients (Cases 3 and 5), the implant was removed from the anterior chamber and surgically repositioned in the vitreous cavity using a 23-G catheter and anterior chamber maintainer. However, in both patients, repeat migration of the dexamethasone implant was observed. In 1 of these patients (Case 3), the implant was surgically repositioned again with no further problems, while in the other patient (Case 5) explantation was performed using a 23-G catheter. This patient later underwent keratoplasty due to corneal endothelial failure and bullous keratopathy. The implant was also explanted from another patient (Case 6) using a 23-G catheter. Keratoplasty was planned in the cornea unit due to the development of corneal endothelial failure and bullous keratopathy. In all of our patients, the dexamethasone implant migrated into the anterior chamber within 1 to 4 weeks of implantation. Five patients (Cases 1, 2, 4, 5, and 6) lacked posterior capsule integrity and all patients had undergone PPV.

Goncalves et al.¹⁷ retrospectively analyzed 468 patients who received dexamethasone implant injections at multiple centers and determined the prevalence of implant migration to be 1.6%. They also reported a significant relationship between implant migration and cataract surgery ($p=0.043$), intraocular lens status ($p=0.005$), and vitrectomy ($p=0.057$). Öner et al.¹⁸ injected a dexamethasone implant for macular edema in a patient who underwent PPV and scleral-fixated IOL implantation after complicated cataract surgery. Fifteen days after the implantation, the patient exhibited corneal edema and anterior chamber migration of the dexamethasone implant. Explantation was performed, but corneal edema persisted at 4-month follow-up. All of our patients had history of cataract surgery and vitrectomy. Four had sutured intraocular lenses, 1 had an open posterior capsule, zonular dialysis, and a sulcus lens, and 3 patients developed bullous keratopathy.

In cases of anterior chamber dislocation of dexamethasone implants, the implant should be removed or repositioned in the vitreous cavity as soon as possible in order to prevent permanent corneal edema due to corneal endothelial damage. Pupil dilation and reverse Trendelenburg positioning followed by positional guidance of the implant toward the vitreous by cornea manipulation with a sterile cotton tip applicator is a noninvasive procedure that can be used as a first approach in suitable patients. Patients should be advised to avoid long trips and the prone position after dexamethasone implantation and to see an ophthalmologist immediately if they experience any ocular complaints.

Risk factors for anterior chamber migration of dexamethasone implant such as PPV, previous complicated cataract surgery, lack of posterior capsule integrity, and zonular dialysis should be evaluated carefully and implantation should be avoided in patients who are at risk.

Ethics

Informed Consent: Obtained.

Peer-review: Externally peer reviewed.

Authorship Contributions

Surgical and Medical Practices: Ö.R.K., C.T., H.M., E.K., Consept: Ö.R.K., S.D., Design: Ö.R.K., S.D., Data Collection or Processing: Ö.R.K., S.D., Analysis or Interpretation: Ö.R.K., S.D., Literature Search: S.D., Writing: Ö.R.K., S.D., C.T.

Conflict of Interest: No conflict of interest was declared by the authors.

Financial Disclosure: The authors declared that this study received no financial support.

References

1. Kuppermann BD, Blumenkranz MS, Haller JA, Williams GA, Weinberg DV, Chou C, Whitcup SM. Randomized controlled study of an intravitreal dexamethasone drug delivery system in patients with persistent macular edema. *Archives of ophthalmology (Chicago, Ill : 1960)* 2007;125:309-317.
2. Haller JA, Bandello F, Belfort R, Jr., Blumenkranz MS, Gillies M, Heier J, Loewenstein A, Yoon YH, Jacques ML, Jiao J, Li XY, Whitcup SM. Randomized, sham-controlled trial of dexamethasone intravitreal implant in patients with macular edema due to retinal vein occlusion. *Ophthalmology*. 2010;117:1134-46.e3.
3. Rahimy E, Khurana RN. Anterior segment migration of dexamethasone implant: risk factors, complications, and management. *Current opinion in ophthalmology*. 2017;28:246-251.
4. Meyer LM, Schonfeld CL. Secondary glaucoma after intravitreal dexamethasone 0.7 mg implant in patients with retinal vein occlusion: a one-year follow-up. *Journal of ocular pharmacology and therapeutics: the official journal of the Association for Ocular Pharmacology and Therapeutics*. 2013;29:560-565.
5. Güler HA, Örnek N, Oğurel T, Yumuşak ME, Gökçınar NB, Örnek K. İntravitreal Deksametazon İmplant (Ozurdex®) Uygulamasının Göz İçi Basıncı ve Ön Kamera Açısına Etkileri. *Journal of Glaucoma-Cataract*. 2018;13:110-116.
6. Coca-Robinot J, Casco-Silva B, Armada-Maresca F, Garcia-Martinez J. Accidental injections of dexamethasone intravitreal implant (Ozurdex) into the crystalline lens. *European journal of ophthalmology*. 2014;24:633-636.
7. Khurana RN, Appa SN, McCannell CA, Elman MJ, Wittenberg SE, Parks DJ, Ahmad S, Yeh S. Dexamethasone implant anterior chamber migration: risk factors, complications, and management strategies. *Ophthalmology*. 2014;121:67-71.
8. Yılmaz T, Dikci S, Yeşilöz Ö, Tuncer İ, Fırat M, Genç O. Kazara Lens İçi Deksametazon İmplant Enjeksiyonu: İki Olgu Sunumu. *Journal of Glaucoma-Cataract*. 2017;12:148-150.
9. Kishore SA, Schaal S. Management of anterior chamber dislocation of dexamethasone implant. *Ocular immunology and inflammation*. 2013;21:90-91.
10. Ha JY, Jang JY, Ji YS. Management of Anterior Chamber Migration of Dexamethasone Intravitreal Implant. *Korean journal of ophthalmology:KJO*. 2017;31:574-575.
11. Malcles A, Janin-Manificat H, Yhuel Y, Russo A, Agard E, El Chehab H, Ract Madoux G, Masse H, Burillon C, Dot C. [Anterior chamber migration of intravitreal dexamethasone implant (Ozurdex(R)) in pseudophakic eyes: report of three cases]. *Journal francais d'ophtalmologie*. 2013;36:362-367.
12. Kreissig I. Surgical techniques for repair of primary retinal detachment: Part II. Comparison of present techniques in relation to morbidity. *Folia medica*. 2010;52:5-11.
13. Bellocq D, Korobelnik JF, Burillon C, Voirin N, Dot C, Souied E, Conrath J, Milazzo S, Massin P, Baillif S, Kodjikian L. Effectiveness and safety of dexamethasone implants for post-surgical macular oedema including Irvine-Gass syndrome: the EPISODIC study. *The British journal of ophthalmology*. 2015;99:979-983.

14. Turaka K, Kwong HM, Jr, De Souza S. Intravitreal implant migration into anterior chamber in a post-vitreotomy eye with central retinal vein occlusion and persistent macular edema. *Ophthalmic surgery, lasers & imaging retina*. 2013;44:196-197.
15. Mateo C, Alkabetz M, Bures-Jelstrup A. Scleral fixation of dexamethasone intravitreal implant (OZURDEX(R)) in a case of angle-supported lens implantation. *International ophthalmology*. 2014;34:661-665.
16. Kang H, Lee MW, Byeon SH, Koh HJ, Lee SC, Kim M. The clinical outcomes of surgical management of anterior chamber migration of a dexamethasone implant (Ozurdex(R)). *Graefe's archive for clinical and experimental ophthalmology*. 2017;255:1819-1825.
17. Goncalves MB, Alves BQ, Moura R, Magalhaes O, Jr., Maia A, Belfort R, Jr., de Avila MP, Zas M, Saravia M, Lousas M, Wu L, Arevalo JF, Pacheco KD, Johnson T, Farah ME, Rodriguez EJ, Maia M. Intravitreal dexamethasone implant migration into the anterior chamber: A Multicenter Study From the Pan-American Collaborative Retina Study Group. *Retina (Philadelphia, Pa)* 2019 Feb 14.
18. Öner A, Yıldırım Y, Sinim N. Skleral Fiksasyonlu Göz İçi Lensi Olan Bir Olguda İntravitreal Deksametazon İmplantının Ön Kamaraya Migrasyonu. *Journal of Retina-Vitreous*. 2015:191-194.



Acute Macular Neuroretinopathy in Purtscher Retinopathy

© Berrak Şekeryapan Gediz

University of Health Sciences, Ankara Ulucanlar Eye Training and Research Hospital, Clinic of Ophthalmology, Ankara, Turkey

Abstract

Purtscher retinopathy and acute macular neuroretinopathy are two rare clinical disorders that are both probably associated with ischemic pathogenesis. In this report, we describe for the first time the coexistence of Purtscher retinopathy and acute macular neuroretinopathy in a patient with visual complaints after chest trauma. Optical coherence tomography (OCT) scans demonstrated outer retinal defects, while OCT angiography illustrated areas of hypoperfusion in the superficial and deep capillary plexuses as well as the choriocapillaris. In this report, it is emphasized that acute macular neuroretinopathy is a clinical condition that should be kept in mind in patients presenting with post-traumatic vision loss. Although its clinical diagnosis is difficult, characteristic OCT and OCT angiography findings facilitate diagnosis.

Keywords: Purtscher retinopathy, acute macular neuroretinopathy, optical coherence tomography, optical coherence tomography angiography, ischemia

Introduction

Purtscher retinopathy is a rare condition characterized by vision loss and central visual field defects that develops after traumas that do not involve direct contact with the eyes, such as chest and head trauma. Clinical findings include peripapillary cotton-wool spots, areas of retinal whitening (Purtscher flecken), and hemorrhages. Although the pathogenesis remains unclear, the findings are believed to arise due to retinal ischemia caused by embolic occlusion of the precapillary arterioles.^{1,2}

Acute macular neuroretinopathy (AMN) is an uncommon clinical entity characterized by dark intraretinal lesions accompanied by acute-onset paracentral scotomas. It was first described in young women using oral contraceptives, and later publications demonstrated it could also be associated with viral infections, trauma, surgery, or medications.^{3,4,5} Retinal

microvascular changes are implicated in the pathogenesis of AMN.⁶ Optical coherence tomography (OCT) and OCT angiography (OCTA) findings reveal the presence of superficial and/or deep capillary plexus and choriocapillaris ischemia in AMN.^{6,7,8,9,10}

Although there have been a few previous reports in the literature of AMN associated with trauma, here we present for the first time a patient who developed AMN due to Purtscher retinopathy, with findings of nonperfusion in both the superficial and deep capillary plexuses and choriocapillaris.

Case Report

A 61-year-old man presented with complaints of decreased vision in the right eye and central scotoma in the left eye. He reported having an intravehicular traffic accident 15 days earlier

Address for Correspondence: Berrak Şekeryapan Gediz, University of Health Sciences, Ankara Ulucanlar Eye Training and Research Hospital, Clinic of Ophthalmology, Ankara, Turkey Phone: +90 533 369 41 83 E-mail: berrakgediz@gmail.com **ORCID-ID:** orcid.org/0000-0002-3456-1178

Received: 02.10.2019 **Accepted:** 25.12.2019

Cite this article as: Şekeryapan Gediz B. Acute Macular Neuroretinopathy in Purtscher Retinopathy. Turk J Ophthalmol. 2020;50:123-126

and that his visual complaints started immediately after the accident. General physical examination was unremarkable except for a fractured rib. On ophthalmologic examination, his best corrected visual acuity (BCVA) was 20/400 in the right eye and 20/20 in the left eye. Intraocular pressures and anterior segment findings were normal in both eyes. Fundus examination revealed cotton-wool spots in the peripapillary region, intraretinal hemorrhages, and dark lesions with indistinct borders in the central fovea of the right eye. On examination of the left eye, it was seen that the same dark lesion was present in the nasal fovea and did not cross the vertical midline (Figures 1a and b). An infrared image of the right eye revealed a hyporeflective foveal lesion; the OCT section passing through the lesion showed hyperreflective thickening of the ganglion cell and nerve fiber layers caused by soft exudates, in addition to loss of the subfoveal photoreceptor inner segment/outer segment (IS/OS) band and photoreceptor outer segment/retinal pigment epithelium (OS/RPE) band (Figure 2a). On the infrared image of the left eye, the borders of a hyporeflective lesion located in the nasal fovea were clearly visible, while the OCT section corresponding to the lesion revealed losses in the IS/OS and OS/RPE bands (Figure 3a). The patient was followed for a diagnosis of AMN secondary to Purtscher retinopathy. At 6-month follow-up, his BCVA was 20/40 in the right eye and 20/20 in the left eye, and the central scotoma in his left eye had disappeared. The infrared image of the right eye demonstrated that the borders of the lesion had shrunk, while OCT showed that the IS/OS band was visible although still faint in places, the OS/RPE band was visible except in two localized areas, and the outer nuclear layer had thinned (Figure 2b). Similarly, the infrared image of the left eye showed that the borders of the lesion had shrunk, while OCT revealed that the IS/OS band had reappeared and the defect in the OS/RPE band had diminished in size (Figure 3b). OCTA sections revealed superficial and deep capillary plexus hypoperfusion and reduced flow in the choriocapillaris corresponding to the areas of retinal hypoperfusion in the right eye (Figure 4a). Evaluation of the left eye was normal (Figure 4b).

Discussion

Purtscher retinopathy is believed to develop as a result of leukocyte aggregation due to trauma-related activation of the

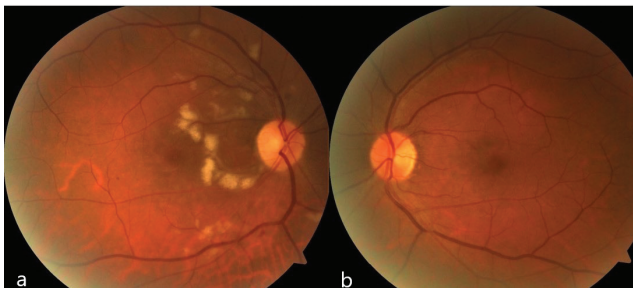


Figure 1. a) Color fundus photograph of the right eye shows cotton-wool spots in the peripapillary region, intraretinal hemorrhages, and a dark lesion with indistinct borders located in the central fovea. **b)** Color fundus photograph of the left eye shows a dark lesion located in the nasal fovea that does not cross the vertical midline

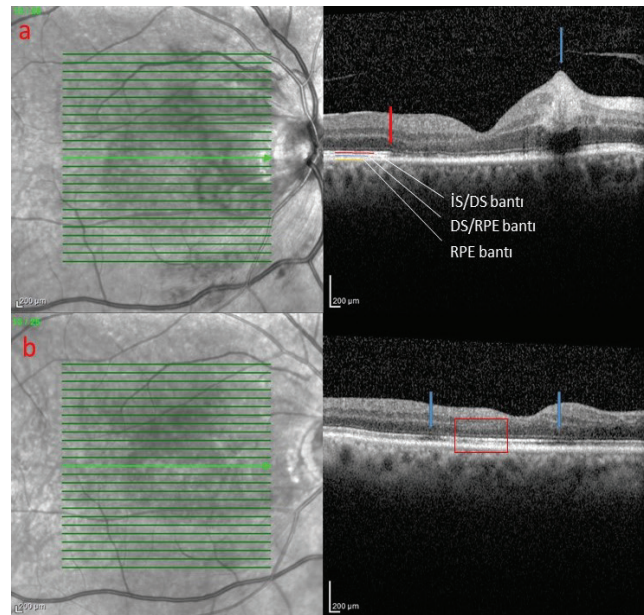


Figure 2. a) Infrared image of the right eye and OCT section through the lesion. The outer retinal layers are individually marked. The point where loss of the IS/OS and OS/RPE bands begins is indicated with a red arrow; the hyperreflective thickening caused by soft exudate is shown with a blue arrow. **b)** In the OCT image of the same eye 6 months later, areas of OS/RPE band loss are indicated with blue arrows. The IS/OS band is faint in these areas. The area of outer nuclear layer thinning is indicated with a rectangle

OCT: Optical coherence tomography

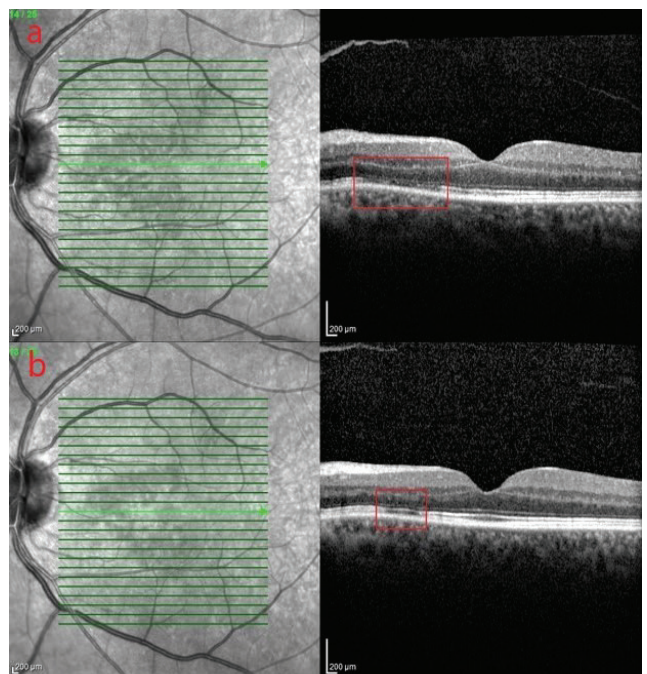


Figure 3. a) Infrared image of the left eye and OCT section through the lesion. In the section through the hyporeflective lesion in the nasal fovea, loss of the IS/OS and OS/RPE bands is marked with a rectangle. **b)** OCT image of the same eye 6 months later shows the indicated area decreased in size and the IS/OS band reappeared, but loss of the OS/RPE band persists

OCT: Optical coherence tomography

complement system. These aggregates cause occlusion and secondary infarction in the retinal arterioles. Occlusion of the precapillary arterioles results in cotton-wool spots when it involves the superficial capillary network and Purtscher flecken when the deep capillary network is affected.^{1,2}

AMN is a rare disease first described in 1975 by Bos and Deutman³ based on clinical observation and fundus fluorescein angiography findings. The acute onset of the disease and the presence of risk factors such as infection, inflammation, and ischemia suggested a vascular etiology. With the development of multimodal imaging techniques, the pathogenesis of AMN has become clearer and OCT started to be used in diagnosis.^{4,5,6} The OCT findings of AMN can be separated into the early and late period. Early findings include the appearance of a hyperreflective band in the outer plexiform and outer nuclear layer, disruption of the IS/OS and OS/RPE lines, and the hyperreflective band usually regresses within 1 week. In the late period, the IS/OS line reappears, OS/RPE disruption continues, and permanent thinning of the outer nuclear layer is added to the findings. In light of OCT findings, deep capillary plexus ischemia is believed to be responsible for the pathogenesis.⁶ Our patient presented all OCT findings other than the hyperreflective band in the outer nuclear layer that appears and disappears in the early period. This hyperreflective band may not have been observed because the patient presented 2 weeks after the trauma.

With the introduction of OCTA, the hypoperfusion involved in the pathogenesis of AMN has been more clearly demonstrated. However, the vascular region in which hypoperfusion is observed varies in different publications. While some publications report that choriocapillaris ischemia alone is responsible for the pathogenesis, there are also cases in which superficial and/or deep retinal perfusion is affected with no impact on the internal choroid layers.^{7,8,9,10} OCT findings of outer nuclear layer thinning subsequent to early changes in the outer plexiform layer indicate that hypoperfusion in the choriocapillaris as well as the deep capillary plexus is responsible for the pathogenesis. This suggests that the hypoperfusion in AMN may occur at the level of the ophthalmic artery, thus affecting both the deep capillary plexus

and choriocapillaris.¹¹ Both superficial and deep capillary plexus and choriocapillaris hypoperfusion was observed in our patient's right eye. The appearance of cotton-wool spots demonstrates that ischemia also affects the superficial capillary plexus.

A few cases of AMN developing after trauma have been reported in the literature. The association between indirect trauma and AMN was first demonstrated clinically by Gillies et al.¹², who reported that the increase in intrathoracic pressure resulting from an accident caused an elevation in intravascular pressure, thereby resulting in acute disruption of the blood-retina barrier. Later case series presented the OCT findings of AMN and reported that hypotension or catecholamine discharge due to trauma may cause ischemia in the deep capillary plexus.^{13,14} Our patient's left eye exhibited the clinical and OCT findings of AMN in the absence of any signs of Purtscher retinopathy. Perhaps AMN and Purtscher retinopathy can be regarded as two points on a single disease spectrum that occur when the same ischemic process affects different levels.

In this article, we present a patient who developed AMN due to Purtscher retinopathy together with OCTA findings for the first time. Although there are no OCTA images from the patient's initial presentation, his 6-month follow-up images show that the choriocapillaris was affected along with the superficial and deep capillary plexuses. The outer retinal defects observed on OCT in the early period had partially resolved and at 6 months appeared as localized disruptions in the OS/RPE line and thinning of the inner nuclear layer.

In conclusion, AMN is a clinical condition that should be kept in mind when a patient presents with post-traumatic vision loss. Although clinical diagnosis is difficult, it is easier to diagnose based on characteristic findings on OCT and OCTA.

Ethics

Informed Consent: Obtained.

Peer-review: Externally peer reviewed.

Financial Disclosure: The authors declared that this study received no financial support.

References

- Şahan B, Altunsoy M, Tatlıpınar S. Purtscher retinopatisi. *Ret-Vit Özel Sayı*. 2015;23:216-219.
- Yalçınbayır Ö, Toka F. Purtscher retinopatisi ve Terson sendromu. *Ret-Vit Özel Sayı* 2012;20:71-75.
- Bos PM, Deutman AF. Acute macular neuroretinopathy. *Am J Ophthalmol*. 1975;80:573-584.
- Turbeville SD, Cowan LD, Gass JD. Acute macular neuroretinopathy: A review of the literature. *Surv Ophthalmol*. 2003;48:1-11.
- Bhavsar KV, Lin S, Rahimy E, Joseph A, Freund KB, Sarraf D, Cunningham ET Jr. Acute macular neuroretinopathy: A comprehensive review of the literature. *Surv Ophthalmol*. 2016;61:538-565.
- Fawzi AA, Pappuru RR, Sarraf D, Le PP, McCannel CA, Sobrin L, Goldstein DA, Honowitz S, Walsh AC, Sadda SR, Jampol LM, Elliott D. Acute macular neuroretinopathy: long-term insights revealed by multimodal imaging. *Retina*. 2012;32:1500-1513.
- Aggarwal K, Agarwal A, Katoch D, Sharma M, Gupta V. Optical coherence tomography angiography features of acute macular neuroretinopathy in dengue fever. *Indian J Ophthalmol*. 2017;65:1235-1238.

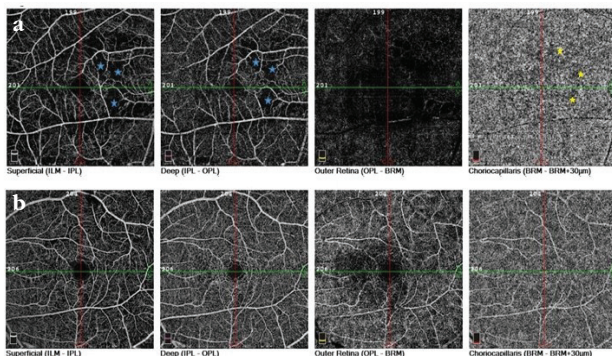


Figure 4. a) OCTA image of the right eye. Areas marked with a blue star indicate superficial and deep capillary plexus hypoperfusion; areas marked with a yellow star indicate choriocapillaris hypoperfusion corresponding to the areas of retinal hypoperfusion. **b)** OCTA image of the left eye appears normal

OCTA: OCT angiography

8. Chen YC, Chen SN. Microvascular change in acute macular neuroretinopathy by using optical coherence tomography angiography. *Taiwan J Ophthalmol.* 2019;9:118-121.
9. Casalino G, Arrigo A, Romano F, Munk MR, Bandello F, Parodi MB. Acute macular neuroretinopathy: pathogenetic insights from optical coherence tomography angiography. *Br J Ophthalmol.* 2019;103:410-414.
10. Lee SY, Cheng JL, Gehrs KM, Folk JC, Sohn EH, Russell SR, Guo Z, Abramoff MD, Han IC. Choroidal features of acute macular neuroretinopathy via optical coherence tomography angiography and correlation with serial multimodal imaging. *JAMA Ophthalmol.* 2017;135:1177-1183.
11. Dansingani KK, Freund KB. Paracentral acute middle maculopathy and acute macular neuroretinopathy: Related and distinct entities. *Am J Ophthalmol.* 2015;160:1-3.
12. Gillies M, Sarks J, Dunlop C, Mitchell P. Traumatic retinopathy resembling acute macular neuroretinopathy. *Aust N Z J Ophthalmol.* 1997;25:207-210.
13. Nentwich MM, Leys A, Cramer A, Ulbig MW. Traumatic retinopathy presenting as acute macular neuroretinopathy. *Br J Ophthalmol.* 2013;97:1268-1272.
14. Chinskey ND, Rahimy E, Johnson MW. Acute macular neuroretinopathy following non-ocular trauma: A hypothesis regarding pathophysiologic mechanism. *Ophthalmic Surg Lasers Imaging Retina.* 2015;46:1013-1020.