



## Ab Interno Goniotomy/Goniectomy Techniques

Zeynep Aktaş<sup>1</sup>, Syril Dorairaj<sup>2</sup>, Mohamed Sayed<sup>3</sup>, Arsham Sheybani<sup>4</sup>, Ahmet Yücel Üçgül<sup>5</sup>, Isabella Wagner<sup>2</sup>,  
 Mohamed Khodeiry<sup>6</sup>

<sup>1</sup>University of Texas Health, Department of Ophthalmology, San Antonio, TX, USA

<sup>2</sup>Mayo Clinic School of Medicine, Department of Ophthalmology, Jacksonville, FL, USA

<sup>3</sup>Cleveland Clinic Abu Dhabi, Abu Dhabi, UAE

<sup>4</sup>Washington University School of Medicine, Department of Ophthalmology and Visual Sciences, St Louis, MO, USA

<sup>5</sup>Kırşehir Ahi Evran University, Training and Research Hospital, Clinic of Ophthalmology, Kırşehir, Türkiye

<sup>6</sup>University of Kentucky College of Medicine, Department of Ophthalmology and Visual Sciences, Lexington, KY; Bascom Palmer Eye Institute, University of Miami Miller School of Medicine, Miami, FL, USA

### Abstract

Minimally invasive glaucoma surgeries (MIGS), such as Kahook Dual Blade (KDB), bent ab interno needle goniectomy (BANG), gonioscopy-assisted transluminal trabeculotomy (GATT), OMNI, Trabectome, Streamline, and TrabEx+, have significantly advanced the treatment of glaucoma by improving aqueous humor outflow and reducing intraocular pressure (IOP). These innovative procedures target the trabecular meshwork (TM) and Schlemm's canal, offering effective alternatives to more invasive filtration surgeries. By enhancing the natural drainage pathways, MIGS can achieve notable reductions in IOP and minimize the need for long-term glaucoma medications. Each device has a distinct mechanism of action. The KDB excises a strip of TM, while BANG uses a bent hypodermic needle for controlled goniectomy. GATT performs a 360-degree trabeculotomy using a microcatheter or Prolene (polypropylene) suture to open Schlemm's canal. OMNI combines canaloplasty and trabeculotomy in a single procedure. The Trabectome ablates TM tissue with electrical energy, whereas Streamline performs viscodilation to expand outflow channels. TrabEx+ facilitates goniectomy with integrated irrigation and aspiration. Clinical studies have shown these MIGS techniques to be both safe and effective, with fewer complications compared to traditional surgeries like trabeculectomy or tube shunt implantation. MIGS procedures are particularly appealing due to their reduced recovery time and lower risk profile. However, further research

is essential to establish their long-term efficacy and durability. Continued advancements and comprehensive long-term studies will ensure that MIGS provide sustainable and reliable benefits for glaucoma patients, optimizing treatment strategies in clinical practice.

**Keywords:** Minimal invasive glaucoma surgery, goniotomy, goniectomy

### Introduction

Glaucoma is a leading cause of irreversible blindness worldwide, characterized by progressive optic neuropathy associated with elevated intraocular pressure (IOP). It is a multifactorial disease, and timely management of IOP remains the most effective strategy to prevent disease progression. Despite advancements in medical and laser therapies, many patients require surgical intervention to achieve adequate IOP control. Traditional glaucoma surgeries, such as trabeculectomy and tube shunts, have long been the standard options for managing advanced disease. While effective, these procedures are invasive, associated with significant risks such as hypotony, infection, bleb-related complications, and prolonged recovery periods.

To address these limitations, the past two decades have witnessed the emergence of minimally invasive glaucoma surgeries (MIGS), which aim to enhance aqueous humor outflow with minimal disruption to ocular structures. First introduced in the early 2000s, MIGS techniques have revolutionized glaucoma management by offering safer, less invasive alternatives to traditional surgeries. Unlike trabeculectomy, MIGS procedures are often performed via an ab interno approach, eliminating the need for conjunctival dissection and reducing the risk of postoperative complications. Additionally, MIGS techniques are associated with shorter operative times, quicker recovery,

**Cite this article as:** Aktaş Z, Dorairaj S, Sayed M, Sheybani A, Üçgül AY, Wagner I, Khodeiry M. Ab Interno Goniotomy/Goniectomy Techniques. *Turk J Ophthalmol.* 2025;55:159-170

**Address for Correspondence:** Zeynep Aktaş, University of Texas Health, Department of Ophthalmology, San Antonio, TX, USA

E-mail: drzeynep2000@yahoo.com ORCID-ID: [orcid.org/0000-0001-8339-3433](https://orcid.org/0000-0001-8339-3433)

Received: 05.08.2024 Accepted: 12.01.2025

DOI: 10.4274/tjo.galenos.2025.29345

and better preservation of conjunctival integrity, making them particularly advantageous for patients who may require future surgical interventions.

The necessity for MIGS stems from their ability to bridge the gap between medical therapy and more invasive surgical options. With an expanding range of devices and techniques, MIGS can be tailored to address specific anatomical and physiological challenges of glaucoma, offering versatility in treatment approaches. These procedures have demonstrated significant success in lowering IOP and reducing dependence on glaucoma medications, particularly in patients with mild to moderate glaucoma. Moreover, the ability to combine MIGS with cataract surgery has further broadened their applicability and appeal.

This review aims to provide an overview of MIGS techniques, highlighting their evolution, applications, and outcomes. By comparing different MIGS procedures, we seek to elucidate their roles in modern glaucoma management and their advantages over traditional surgical approaches.

### Kahook Dual Blade Goniotomy

#### Technical Information

The Kahook Dual Blade (KDB; New World Medical) is an ophthalmic knife specifically designed for ab interno goniotomy. It functions by engaging, stretching, and removing a strip of diseased trabecular meshwork (TM) tissue in both pediatric and adult glaucoma patients.<sup>1</sup> This MIGS device was cleared by the United States Food and Drug Administration (FDA) in 2015 under a 510(k) class I exemption. The device features a unique design that facilitates precise tissue removal. Key elements include a distal 230- $\mu$ m-wide footplate with a pointed tip for penetrating target tissue, a ramp for tissue elevation, and a pair of posteriorly integrated elevated parallel blades that stretch and excise TM tissue.<sup>2,3</sup> Literature consistently demonstrates that the KDB procedure significantly reduces IOP and dependence on glaucoma medications across a wide range of glaucoma types and severities, with a safety profile favorable to traditional incisional procedures.

#### Surgical Application

Excisional goniotomy with the KDB is performed under direct gonioscopic visualization. An intraoperative image of KDB goniotomy can be found in [Figure 1A](#). The device is introduced into the anterior chamber via a temporal peripheral clear corneal incision, targeting the nasal TM. The pointed tip creates an opening, while the footplate seats against the anterior wall of Schlemm's canal. The device advances through the canal, lifting TM onto the ramp and directing it toward the dual blades, facilitating clean tissue excision. This process maximizes the width of the excised TM strip while minimizing collateral damage to surrounding structures.<sup>4</sup>

Three excisional approaches are available, as described by Dorairaj et al.<sup>2</sup>: 1) *Mark and meet*: The device creates an initial opening at one end, is removed, re-enters the TM at

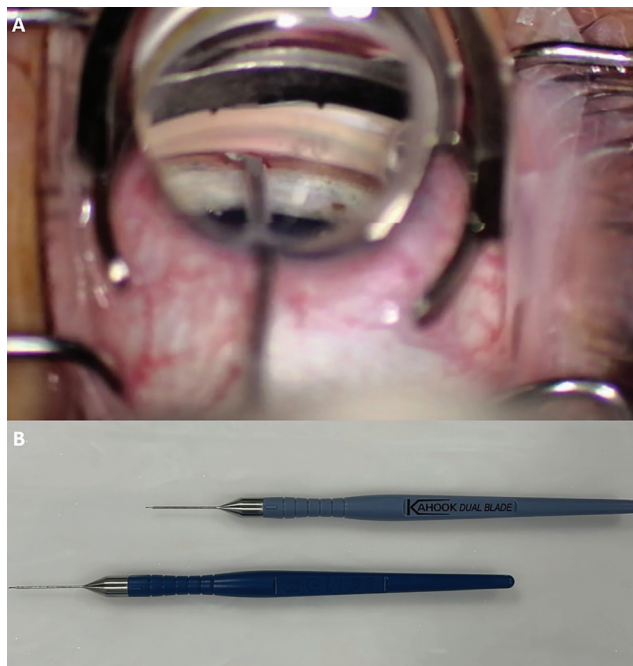
the opposite end, and excises the tissue strip between the two points. 2) *Outside-in*: The device creates an incision at one end and cuts to the midpoint, then makes a connecting cut from the opposite end for complete strip excision. 3) *Inside-out*: The device engages the midpoint of the excision, moves to one end, rotates 180 degrees, and returns to excise the strip in two halves or leaves them in place, based on surgeon preference.

#### Indications

KDB is indicated for 1) *Open-angle glaucoma (OAG)*: As a standalone procedure or in combination with phacoemulsification, addressing mild to severe disease, 2) *Angle-closure glaucoma (ACG)*: Combined with goniosynechialysis (GSL) to manage peripheral anterior synechiae (PAS) and reduce IOP.

#### Literature Review

KDB excisional goniotomy can be performed as a standalone procedure or in combination with phacoemulsification in the treatment of OAG and across the spectrum of disease severity. In a multicenter retrospective analysis, ElMallah et al.<sup>5</sup> evaluated the safety and efficacy of standalone KDB goniotomy in a sample of 42 eyes with predominantly mild to severe primary open-angle glaucoma (POAG; 85.7%) and reported mean percentage reductions from baseline in IOP (-27.7%; -19.3%) and glaucoma medications (-32.6%; -12.5%) at 6 and 12 months, respectively, with 40.5% of eyes experiencing reduction by >1 IOP-lowering medications at 12 months. Dorairaj et al.<sup>6</sup> evaluated clinical outcomes of KDB goniotomy combined with phacoemulsification in a prospective, multicenter case series of 52 eyes. The authors found significant percentage reductions in IOP (-26.2%) and glaucoma medications (-50.0%) by month



**Figure 1.** A) Intraoperative image of the Kahook Dual Blade goniotomy procedure; B) Image of the first-generation Kahook Dual Blade model (top) and the second-generation Kahook Dual Blade Glide® model (bottom)

12, with an IOP reduction of >20% from baseline in 57.7% of eyes and reduction in glaucoma medication burden by >1 medications in 63.5% of eyes. Reports have also compared the outcomes of standalone KDB goniotomy to phacoemulsification with KDB goniotomy. In a single-center retrospective report of 90 patients with mild to severe POAG or pseudoexfoliative glaucoma (PEXG), Barkander et al.<sup>7</sup> found KDB goniotomy to produce significant percentage reductions in IOP (-39.5%; -37.3%) and number of glaucoma medications (-11.4%; -30.3%) at 24 months when performed as a standalone procedure and when combined with phacoemulsification, respectively. The authors noted a lower rate of postoperative hyphema (4% vs. 26%;  $p=0.008$ ) and lower risk of subsequent glaucoma surgery ( $p=0.026$ ) in the combined group, suggesting additional benefits of the KDB procedure when performed in combination with phacoemulsification.<sup>7</sup> The follow-up time of most KDB studies in the current literature ranges from 6 to 24 months, but two studies have found the procedure to exhibit excellent reductions in IOP (by 24.7-39.0%) and glaucoma medication burden (by 33.3-50.0%) at 36 months when combined with phacoemulsification in eyes with OAG.<sup>8,9</sup> Additionally, long-term (60-month) success has also been demonstrated in eyes with mild to moderate OAG on >1 IOP-lowering medications at baseline, regardless of phacoemulsification status.<sup>10</sup>

While KDB goniotomy is indicated for the treatment of OAG and ocular hypertension, success has been demonstrated when treating ACG. Across multiple retrospective studies of a cohort of 42 eyes with ACG, Dorairaj et al.<sup>11,12,13</sup> showed that KDB-assisted GSL and excisional goniotomy with phacoemulsification induced significant mean percentage reductions in both IOP (-48.8%; -47.2%; -47.1%) and glaucoma medications (-91.7%; -91.7%; -76%) at 6, 12, and 24 months, respectively. By 24 months, no subsequent glaucoma surgeries were required in the study cohort and all eyes had achieved >20% IOP reduction from baseline, with 69% becoming medication-free. The authors suggested that the excellent safety and efficacy seen with this combined procedure were due in part to its ability to address PAS present, which cannot be accomplished with phacoemulsification alone. Al Habash and Albuainain<sup>14</sup> prospectively analyzed outcomes of this combined procedure in 11 eyes with ACG and of KDB goniotomy with phacoemulsification performed in 37 eyes with OAG. At 24 months, significant percentage reductions in mean IOP (-31.4%; -32.1%) and glaucoma medications (-56.3%; -62.7%) were observed in eyes with ACG and OAG, respectively, with no secondary surgical reinterventions required in either group.

A recent study compared the outcomes of standalone KDB goniotomy with other MIGS techniques. A single-center retrospective study by Boopathiraj et al.<sup>15</sup> compared KDB goniotomy to the Xen gel stent in moderate to severe OAG. At 36 months, KDB goniotomy achieved a 23.5% reduction in IOP (from  $23.2\pm 6.0$  mmHg to  $16.6\pm 5.4$  mmHg) and a 30.8%

reduction in medication burden (from  $2.2\pm 1.4$  to  $1.1\pm 0.7$ ). These outcomes were comparable to Xen, which reduced IOP by 22.1% and medication burden by 25.6%. However, the KDB group showed fewer surgical reinterventions (11.5% vs. 42.2% in the Xen group), suggesting that KDB may have a lower long-term complication rate and a reduced need for additional surgeries.<sup>15</sup>

### Complications

Reported complications include 1) *Transient hyphema*: Common but resolves with conservative treatment. 2) *IOP spikes*: Observed postoperatively but manageable. 3) *Hypotony*: Cyclodialysis cleft, though rare (approximately 1.2% of cases), can lead to significant complications such as hypotony maculopathy. A recent case study demonstrated that minimally invasive direct internal cyclopexy (MIDIC) can effectively address cyclodialysis clefts associated with KDB goniotomy.<sup>16</sup> MIDIC avoids conjunctival or scleral incisions, making it an appropriate option for patients who may require future trabeculectomy. This technique has shown success in resolving hypotony maculopathy and restoring visual acuity, as well as maintaining long-term IOP control.<sup>16</sup>

Patients undergoing KDB should be monitored for signs of persistent hypotony, such as choroidal detachment and hypotony maculopathy. Management options include conservative treatment with cycloplegics or surgical repair using cyclopexy for refractory cases. Recommendations include early detection and tailored intervention based on the severity of complications.

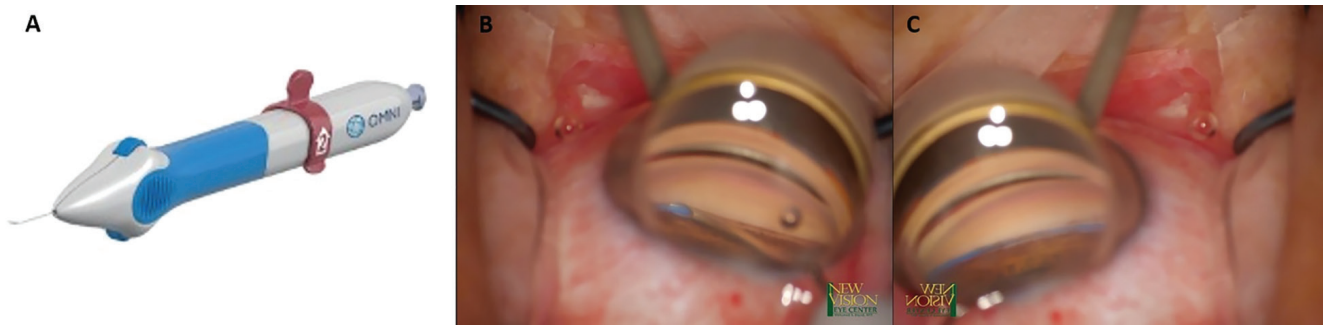
### Future Advancements

The second-generation KDB device, KDB Glide<sup>®</sup>, received FDA approval in 2020. An image of both KDB models can be found in [Figure 1B](#). Enhancements include beveled edges and rounded footplate corners for smoother passage through Schlemm's canal. Preclinical data suggest superior TM excision capabilities compared to other devices like TrabEx<sup>™</sup>, 360° trabeculectomy with Prolene (polypropylene) sutures, and iAccess<sup>®</sup> Trabecular Trephine. Further studies are anticipated to confirm these findings.<sup>17,18</sup>

### OMNI Surgical System

#### Technical Information

The OMNI surgical system (Sight Sciences Inc., Menlo Park, CA, USA) combines canaloplasty and trabeculectomy through a single corneal incision, addressing multiple points of resistance in the aqueous humor outflow pathway. The device, approved by the FDA in December 2017 and launched in March 2018, includes a disposable handpiece with a cannula tip for delivering a microcatheter, an advancement wheel for microcatheter deployment and retraction, and a port for loading an ophthalmic viscosurgical device ([Figure 2A](#)). This system allows for microcatheterization and viscodilation of Schlemm's canal followed by trabeculectomy, making it a versatile option for treating mild to moderate glaucoma.<sup>19</sup>



**Figure 2.** A) OMNI surgical system; B) OMNI device introducing the suture into the Schlemm's canal; C) Appearance of the suture in the canal

### *Surgical Application*

The surgical procedure begins with a temporal corneal incision. The microcatheter is inserted into Schlemm's canal for viscodilation (Figure 2B), targeting resistance in both proximal (TM and Schlemm's canal inner wall) and distal (collector channels) portions of the outflow pathway. Trabeculotomy follows canaloplasty, addressing TM resistance and enhancing aqueous outflow (Figure 2C). The OMNI device avoids scleral dissection or conjunctival disruption and leaves no implant in the eye, which contributes to its minimally invasive profile.

### *Indications*

The OMNI device is indicated for mild to moderate glaucoma and can be used as a standalone procedure or in combination with cataract surgery. It is particularly suited for pseudophakic patients and in cases where enhancing outflow at multiple levels is critical.

### *Literature Review*

Outflow resistance arises from various parts of the physiological outflow pathway. In primates, up to 75% of this resistance is attributed to the TM, specifically the juxtacanalicular tissue.<sup>20,21</sup> The inner wall of Schlemm's canal, on the other hand, contributes 10% or less to the resistance in normal eyes.<sup>22</sup> Studies suggest that in eyes with POAG, the cross-sectional area of Schlemm's canal is on average 54% lower, and mean outflow facility is 55% lower compared to normal eyes. These findings suggest atrophy of Schlemm's canal as a potential source of resistance.<sup>23</sup> Another point of resistance is observed at the collector channel ostia, as demonstrated in bovine eyes, where increased IOP led to the herniation of the inner wall and juxtacanalicular tissue into the ostia of the collector channels.<sup>24</sup>

Combining canaloplasty and trabeculotomy addresses both proximal (TM and inner wall of Schlemm's canal) and distal (Schlemm's canal and collector channels) points of conventional outflow resistance.<sup>25</sup> The canaloplasty part of the procedure opens the distal outflow pathway, including the collector channel ostia, and subsequent trabeculotomy removes the resistance due to the TM. Using the OMNI system also has the advantage of avoiding scleral dissection, sparing the conjunctiva, and not leaving an implant inside the eye.<sup>26</sup> This provides an efficient and safe MIGS option for glaucoma patients.

The ROMEO study is a retrospective multicenter study that evaluated the efficacy and safety profiles of the OMNI system in mild to moderate glaucoma (with IOP  $\leq 36$  mmHg on  $\leq 4$  medications).<sup>26,27,28</sup> In pseudophakic patients who underwent standalone canaloplasty and trabeculotomy, the rate of success (defined as 20% reduction in IOP from baseline or IOP between 6 and 18 mmHg on the same or fewer medications without glaucoma reoperation) was 72.9% at 1 year. Patients with high baseline IOP ( $>18$  mmHg) showed a statistically significant reduction of IOP from  $21.8 \pm 3.3$  mmHg on  $1.7 \pm 1.3$  medications at baseline to  $15.6 \pm 2.4$  mmHg on  $1.2 \pm 1.3$  medications at 1 year. However, in patients with low baseline IOP ( $\leq 18$  mmHg), IOP reduced from  $15.4 \pm 2.0$  mmHg preoperatively to  $13.9 \pm 3.5$  at postoperative month 12 ( $p=0.24$ ), with a decrease in medication burden from  $2.0 \pm 1.3$  at baseline to  $1.3 \pm 1.3$  at month 12 ( $p=0.003$ ). The percentages of patients who used the same number of medications or fewer than at baseline were 91.7% and 89.5% among patients with baseline IOP  $>18$  mmHg and  $\leq 18$  mmHg, respectively. No difference in IOP reduction based on the extent of canaloplasty or trabeculotomy was noted. Most of the reported complications in that study were mild and transient. Mild postoperative inflammation was noted in 12.5% of the eyes, 10.5% of the patients required additional glaucoma procedures, IOP spikes occurred in 5% of the eyes, and corneal edema, clinically significant hyphema (layered and  $>1$  mm and/or persisting for 1 week or more and/or required a secondary intervention), and decreased visual acuity were reported in 4.2% of the eyes.<sup>26</sup>

After 2 years of follow-up, the patients with high baseline IOP who underwent combined canaloplasty/trabeculotomy with cataract surgery had an IOP reduction from a preoperative mean of 21.7 mmHg on 2.2 medications to 15.6 mmHg on 1.4 medications.<sup>27</sup> On the other hand, standalone canaloplasty/trabeculotomy resulted in an IOP reduction from 22.1 mmHg on 1.9 medications to 14.7 mmHg on 1.64 medications. The overall success rate of the cohort was 75% at 2 years, compared to 80.2% at 1 year, which suggests the persistence of the IOP-lowering effect of the canaloplasty/trabeculotomy surgery in the majority of patients. Around one-third of patients were medication-free at 2 years, compared to 12% at baseline.<sup>28</sup>

In the prospective GEMINI study, 360° canaloplasty and 180° trabeculotomy performed with the OMNI surgical system at the time of phacoemulsification resulted in a reduction of unmedicated diurnal IOP from 23.8±3.1 mmHg at baseline to 15.6±4.0 at month 12, with 84.2% of eyes achieving IOP reductions of ≥20% from baseline. Similarly, the mean IOP reduction was 6.2 mmHg at 24 months and 6.9 mmHg at 36 months, with the proportion of eyes with ≥20% reduction in IOP being 77% and 78% at 24 and 36 months, respectively. Moreover, significantly fewer medications were reported at months 12, 24, and 36 (0.4±0.9, 0.4±0.9, and 0.3±0.6, respectively, vs. 1.8±0.9 at baseline). Seventy-four percent of the enrolled patients were medication-free at 36 months. Transient hyphema (>1 mm) was the most commonly reported adverse event in the study, occurring in 6% of the treated eyes, and none of the patients experienced decreased visual acuity due to the procedure. One patient required glaucoma reoperation to control IOP at month 30.<sup>29,30</sup> One of the important risk factors for glaucoma progression is IOP fluctuations.<sup>31</sup> In the post-hoc analysis of the diurnal IOP from the GEMINI study at three different time points (9 am, 12 pm, and 4 pm), it was found that after treatment, the peak IOP was around 8 mmHg lower and IOP fluctuations were 1 mmHg lower than baseline. Additionally, postoperative IOP measurements at each diurnal time point were statistically significantly lower than the corresponding time points preoperatively.<sup>32</sup>

The OMNI device can be used in conjunction with other MIGS to enhance IOP lowering and decrease the number of glaucoma medications.<sup>33</sup> In a retrospective study by Dickinson et al.<sup>34</sup> the success rates (meeting target IOP without medications or further surgical intervention) were 44.5% in patients who underwent phacoemulsification with the Hydrus microstent alone versus 70.0% in the phacoemulsification-Hydrus-canaloplasty (using the OMNI device) group at 6 months (p=0.04). The percentage of medication reduction was 67% in the microstent group alone compared to 88% in the microstent-canaloplasty group (p<0.05). None of the patients in either group required glaucoma reoperation to control IOP. The authors postulated that the increased success rate of the microstent-canaloplasty group was likely due to the downstream dilating effect of canaloplasty, which reverses the herniated tissue in the collector channels and possibly provides a larger outflow area distal to the Hydrus implant. Additionally, the viscodilation of Schlemm's canal might make the correct positioning of the Hydrus implant in the canal easier. Similarly, in patients with inadequate IOP control after iStent (Glaukos, San Clemente, CA, USA) implantation, canaloplasty and trabeculotomy using the OMNI device resulted in a 23% reduction of IOP and an 18% decrease in medication burden.<sup>35</sup> The additive IOP- and medication-lowering effects of combined or sequential MIGS procedures should be weighed against the cost of these procedures.<sup>36,37</sup>

In our experience, we prefer to perform canaloplasty/trabeculotomy after completing cataract surgery in combined

cases using a temporal approach, as most of the active collector channels are thought to be located inferiorly and nasally.<sup>38</sup> Additionally, we tend to perform 360° canaloplasty with 180° trabeculotomy (instead of 360° trabeculotomy) since the success rates of 360° and 180° trabeculotomy were comparable.

### *Complications*

The most commonly reported complications with OMNI include mild and transient postoperative inflammation (12.5%), IOP spikes (5%), and hyphema (>1 mm), noted in 4.2% of cases. These adverse events typically resolve with conservative management. Performing 360° canaloplasty with 180° trabeculotomy instead of full 360° trabeculotomy reduces the likelihood of complications such as hyphema while maintaining efficacy. Rare cases of corneal edema and transient vision changes have also been reported.<sup>39,40</sup>

### *Gonioscopy-Assisted Transluminal Trabeculotomy*

#### *Technical Information*

Gonioscopy-assisted transluminal trabeculotomy (GATT) is a MIGS introduced in 2014.<sup>41</sup> It involves the ab interno cannulation of Schlemm's canal through a single or dual corneal incision, providing a less invasive alternative to traditional filtering surgeries. The procedure directly addresses TM dysfunction and the adjacent inner wall of Schlemm's canal, enhancing aqueous outflow and reducing IOP. GATT has demonstrated efficacy across a variety of glaucoma types, including primary and secondary OAG, ACG, pediatric, and juvenile glaucoma, offering a versatile option for different patient populations.

#### *Surgical Application*

GATT is performed via an ab interno approach, minimizing surgical trauma and postoperative complications. Following standard sterile preparation, a paracentesis track is created as an entry site. Viscoelastic is injected to maintain the depth of the anterior chamber. An illuminated microcatheter is introduced into the anterior chamber, positioned at the nasal angle, and a goniotomy is performed. The microcatheter is carefully advanced circumferentially through Schlemm's canal using microsurgical forceps to ensure complete traversal. Once the microcatheter completes its passage, a 360-degree trabeculotomy is performed. Residual viscoelastic and blood are cleared using a bimanual irrigation-aspiration system. Postoperative care typically includes corticosteroid and antibiotic drops.

GATT is most suitable for ACG patients with manageable PAS. Combining GATT with GSL is key to opening angles with PAS and allowing access to Schlemm's canal. The surgical technique for ACG differs from standard GATT by incorporating GSL using a blunt spatula, which ensures visualization of the TM and facilitates canal cannulation.

#### *Variations in Technique and Instrumentation*

*Prolene GATT:* A novel adaptation of the GATT technique involves thermally marking and blunting the tip of a 5-0

Prolene® (polypropylene) suture for enhanced visualization during the procedure (Figure 3). This modification maintains similar safety to the use of an illuminated microcatheter but is more cost-effective. This approach allows for good visualization of the suture tip during the circumnavigation of Schlemm's canal, contributing to the ease and effectiveness of the surgery.<sup>42,43</sup>

**Prolene GATT with Marker Suture:** This method utilizes a Prolene® suture for canalization and an additional Vicryl® (polyglactin 910) suture as a marker, enabling the surgeon to estimate the degree of Schlemm's canal cannulated. The technique proved to be safe and effective, even in partial canalizations, offering a low-cost alternative to illuminated microcatheters. The use of the marker suture aids in tracking the progress and success of the procedure.<sup>44</sup>

**Trabectome-initiated GATT (TIGATT):** The TIGATT procedure, a modification of GATT, replaces the initial goniotomy incision with an ab interno trabeculectomy ablation using the trabectome. This approach showed promising results in a preliminary case series, offering a feasible alternative with comparable safety and efficacy to traditional GATT and trabectome surgeries.<sup>45</sup> The authors proposed that conducting TM ablation by trabectome could be advantageous, as the initial incision of the TM may result in bleeding and obstruct the surgeon's field of vision. This approach offers a clearer view of Schlemm's canal lumen and its outer wall, while also reducing the likelihood of needing to reapproximate the wound in the trabectome-treated portion of the angle. Patients undergoing TIGATT experienced significant IOP reduction and a decrease in medication use, highlighting its potential effectiveness in glaucoma management.<sup>45</sup>

**Hemi-GATT:** Hemi-GATT involves treating only 180 degrees of the Schlemm's canal, compared to the 360 degrees in traditional GATT. This approach is adaptable to anatomically difficult cannulations and may have an improved safety profile. It allows for future interventions if necessary, providing a stepwise approach to glaucoma management. Evidence suggests that



**Figure 3.** Prolene (polypropylene) gonioscopy-assisted transluminal trabeculectomy. The suture is in the canal and the distal tip is grasped

treating fewer degrees might not compromise the efficacy of the procedure.<sup>46</sup>

#### Indications

GATT is indicated for a wide range of glaucoma types, including primary and secondary OAG, ACG, pigmentary glaucoma, pediatric glaucoma, and glaucoma refractory to conventional medical treatments. Its minimally invasive nature and ability to avoid conjunctival disruption make it a preferred option for patients who may require future surgeries.

#### Literature Review

The effectiveness of GATT has been demonstrated in several studies. Dar et al.<sup>47</sup> reported a mean IOP reduction from 19.3 mmHg to 13.2 mmHg in advanced OAG, achieving a 91% success rate for IOP  $\leq$ 18 mmHg at 6 months. Faria et al.<sup>48</sup> observed a significant decrease from 24.85 mmHg to 12.58 mmHg at 24 months in cases resistant to medical therapy, with a success rate of 64.9% for standalone GATT procedures. Liu et al.<sup>49</sup> documented a 45% IOP reduction at 4 years across various OAG types, though with a cumulative failure rate of 53.9%.

GATT's efficacy extends to PEXG, with Aktas et al.<sup>50</sup> reporting a higher success rate in PEXG (97.6%) compared to POAG (86.8%) in the first year. Grover et al.<sup>51</sup> demonstrated an average IOP reduction of 9.2 mmHg in POAG and 14.1 mmHg in secondary OAG at 24 months, highlighting its broader applicability. Furthermore, Rahmatnejad et al.<sup>52</sup> reported an overall success rate of 63.0% at 12 months, with IOP reductions from 26.1 mmHg to 14.6 mmHg.

Beyond primary glaucomas, GATT has shown promise in other types. Parikh et al.<sup>53</sup> documented an IOP reduction from 37.8 mmHg to 12.2 mmHg at 12 months in uveitic glaucoma, with an 81% success rate and a reduction in glaucoma medications from 4.6 to 2.2. Belkin et al.<sup>54</sup> observed a decrease in IOP from 31.4 mmHg to 13.8 mmHg in uveitic glaucoma over 1 year. Aktas et al.<sup>55</sup> reported an IOP reduction from 31.0 mmHg to 15.6 mmHg in vitrectomized patients, with a success rate of 93.3%. Similarly, Smith et al.<sup>56</sup> demonstrated significant decreases in IOP and medication dependency in eyes with prior keratoplasty. Hopen et al.<sup>57</sup> emphasized the effectiveness of GATT in pediatric patients with steroid-induced glaucoma, achieving IOP reduction through 360° GATT.

GATT has proven effective in ACG, with Fontana et al.<sup>58</sup> reporting a reduction from 30.27 mmHg to 15.20 mmHg at 1 year and a 93-100% success rate at 6 and 12 months. Sharkawi et al.<sup>59</sup> documented reductions from 21.4 mmHg to 12.1 mmHg at 24 months, with a 78% success rate. Additionally, Chira-Adisai et al.<sup>60</sup> found IOP reductions from 21.8 mmHg to 15.1 mmHg over 2 years in ACG.

In primary congenital glaucoma (PCG), Aktas et al.<sup>61</sup> noted significant IOP reductions (from preoperative mean of 31 mmHg to 17.8 mmHg) and a decrease in medication count, while Elhusseiny et al.<sup>62</sup> reported a reduction in mean IOP from 25.7 mmHg to 11.5 mmHg. Grover et al.<sup>63</sup> also observed a mean

decrease in IOP of 12.5 mmHg in PCG and juvenile glaucoma. Haidu and Aktas<sup>64</sup> found postoperative IOPs of 10 and 11 mmHg at 6 months in a child with Klippel-Trenaunay-Weber syndrome. These outcomes collectively suggest that GATT is a versatile and effective surgical option across various glaucoma types.

### Complications

The most commonly reported complication of GATT is transient hyphema. Naftali Ben Haim et al.<sup>65</sup> noted IOP spikes in 24% of 217 eyes, often associated with medication withdrawal. The average duration of IOP spikes was 4.9 days, and these spikes were linked to GATT failure. Gunay et al.<sup>66</sup> reported PAS formation in 38.3% of nasal quadrants and 25.3% of temporal quadrants at 6 months post-surgery, which could limit long-term outcomes. Rao et al.<sup>67</sup> identified causes of IOP spikes, including retained viscoelastic and uncontrolled hypertension, often associated with PAS in multiple quadrants or fibrotic TM tissue. Another rare but severe complication is the wipe-out phenomenon, as reported in patients undergoing GATT combined with phacoemulsification.<sup>68</sup> Wipe-out is characterized by sudden postoperative vision loss, central visual field deterioration, and decreased visual acuity, often seen in patients with advanced glaucoma. This underscores the importance of cautious patient selection, particularly for those with advanced optic nerve damage. Other rare complications include persistent mydriasis, delayed-onset hyphema, panscleritis, cystoid macular edema, intracapsular hematoma, Descemet membrane separation, and transient myopia due to supraciliary effusion.<sup>69,70,71,72,73,74,75</sup>

### Bent Ab interno Needle Goniectomy

#### Technical Information

Bent ab interno needle goniectomy (BANG) is a cost-effective alternative to commercially available TM-based glaucoma procedures. This technique employs a bent 25-gauge hypodermic needle to create a goniotome, forming two cutting edges for TM removal. Unlike commercialized devices with a fixed 90-degree bend, the needle bevel can be adjusted to a 75-degree angle, facilitating smoother travel within Schlemm's canal and reducing resistance encountered along curved canalicular structures (Figure 4A). Histological studies confirm that the excised tissue is indeed TM, demonstrating the procedure's targeted effectiveness.

#### Surgical Application

The BANG procedure involves creating a goniotome by bending the distal 1 mm of a sterile 25-gauge hypodermic needle toward the bevel using a needle driver. For standalone procedures, a 1.4-mm incision suffices, while a temporal incision is utilized when combined with cataract surgery. The bent needle is used to excise the nasal TM, effectively lowering resistance and facilitating aqueous outflow (Figure 4B). The shorter needle design may limit access to all angles from a temporal approach, highlighting the importance of precise adjustments for surgical efficacy.

### Indications

BANG is indicated for patients with OAG seeking a low-cost alternative to other MIGS. It can be performed as a standalone procedure or combined with cataract surgery, making it a versatile option for various patient needs.

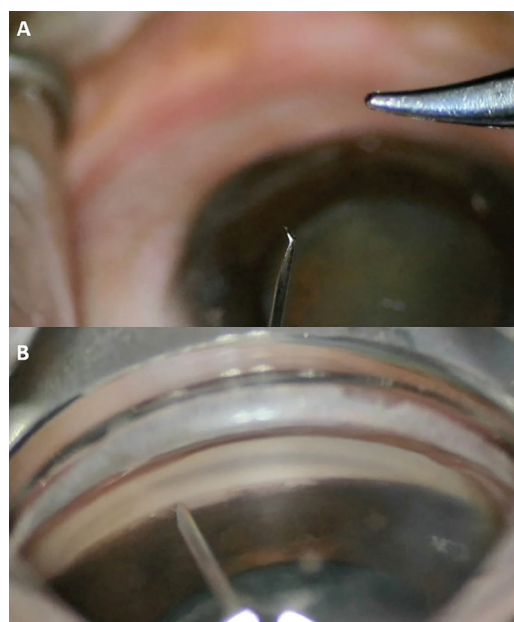
### Literature Review

Initial data on the efficacy of the BANG procedure is promising but limited in scope. Shute et al.<sup>76</sup> analyzed outcomes from 41 eyes of 23 OAG patients undergoing BANG, either as a standalone procedure (2 eyes) or combined with phacoemulsification (39 eyes). The average preoperative IOP was  $17.4 \pm 4.1$  mmHg on  $1.1 \pm 1.4$  topical glaucoma medications. At 6 months postoperatively, the mean IOP decreased to  $13.3 \pm 2.5$  mmHg, with 73% of patients achieving  $\geq 20\%$  IOP reduction ( $p=0.01$ ). Additionally, 73% of patients required at least one fewer medication, and 41% achieved IOP  $\leq 12$  mmHg.

Despite these promising results, the absence of comparative studies among goniotomy devices and limited long-term data highlights the need for further research. Current efforts include multicenter, longitudinal studies aimed at assessing the long-term efficacy and safety of the procedure.

### Complications

The BANG procedure shares a complication profile similar to other TM-based surgeries, although specific reports are sparse due to the limited volume of published data. Potential complications may include transient hyphema, IOP spikes, and mild postoperative inflammation, consistent with findings in similar goniotomy techniques. The straightforward nature of the BANG technique and the use of readily available materials suggest a favorable safety profile, but more data are needed to confirm this assumption.



**Figure 4.** A) The tip of a 25-gauge hypodermic needle is bent; B) The needle tip is inserted along Schlemm's canal for goniectomy

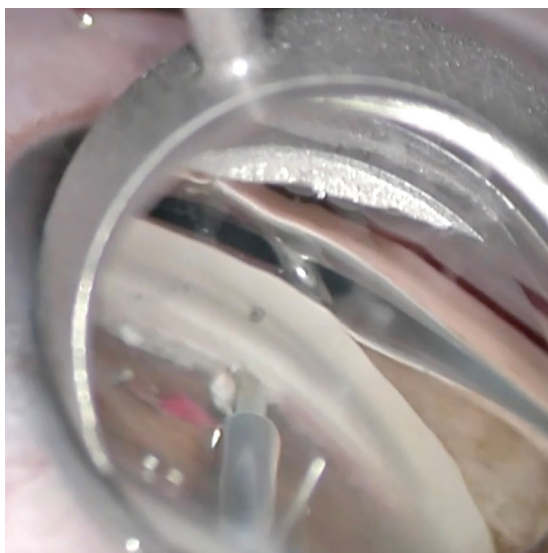
## Trabectome

### Technical Information

The Trabectome, developed by NeoMedix Corporation, is a surgical device approved by the FDA in 2004 for the treatment of glaucoma. It is designed to enhance aqueous humor outflow by ablating a strip of the TM and the inner wall of Schlemm's canal using high-frequency electrical energy (Figure 5).<sup>6,77</sup> This technique minimizes tissue damage while facilitating direct outflow of aqueous humor into Schlemm's canal, reducing IOP. The procedure's minimally invasive nature results in less postoperative inflammation and scarring compared to traditional glaucoma surgeries. However, the high-frequency ablation method is associated with a higher risk of intraoperative blood reflux, a temporary complication that can obscure the surgical field and potentially prolong surgery duration. Despite this, the Trabectome has demonstrated consistent efficacy in reducing IOP and dependence on glaucoma medications.

### Surgical Application

The Trabectome procedure begins with the creation of a small corneal incision. The device is inserted under gonioscopic visualization to access the TM. High-frequency electrical energy is used to ablate a portion of the TM and the inner wall of Schlemm's canal, creating a pathway for improved aqueous humor outflow. Careful technique is required to manage potential blood reflux from Schlemm's canal, which typically resolves spontaneously and does not significantly impact postoperative outcomes. Postoperatively, anti-inflammatory and antibiotic medications are prescribed to minimize inflammation and infection risk.



**Figure 5.** Tip of the Trabectome device, ablating and removing the trabecular meshwork strip

### Indications

The Trabectome is indicated for patients with OAG, particularly those seeking a minimally invasive procedure to improve aqueous outflow and reduce IOP. It can be performed as a standalone procedure or in combination with cataract surgery, offering flexibility for a range of patient needs.

### Literature Review

The Trabectome has been extensively studied, with results consistently demonstrating its efficacy and safety in managing glaucoma. Studies have shown that the Trabectome achieves significant reductions in IOP, with average decreases ranging from 20% to 40% depending on the patient population and follow-up duration. For example, Mosaed et al.<sup>78</sup> reported an IOP reduction from 24.6 mmHg to 16.4 mmHg at 12 months in patients with POAG, with a simultaneous reduction in glaucoma medications. In a multicenter study, Kaplowitz et al.<sup>79</sup> reported that the Trabectome lowered IOP by approximately 31% to a final IOP near 15 mmHg while reducing the number of medications by less than one, with a low rate of serious complications. When combined with phacoemulsification, the Trabectome has shown additive effects in IOP reduction. Minckler et al.<sup>80</sup> reported a decrease from 21.1 mmHg to 15.6 mmHg at 12 months in patients undergoing combined Trabectome-phacoemulsification procedures. Although the Trabectome is generally effective, its success may vary based on patient factors such as age, disease severity, and baseline IOP. Additionally, while the device is effective in reducing IOP, its outcomes may be less predictable in secondary glaucomas compared to POAG.

### Complications

The most commonly reported complication of Trabectome surgery is intraoperative blood reflux from Schlemm's canal, which occurs due to the direct connection created between the anterior chamber and the canal. Although this reflux can obscure the surgical field, it typically resolves spontaneously without impacting long-term outcomes. Other complications include transient hyphema, postoperative IOP spikes, and mild inflammation, all of which are generally self-limiting and manageable with standard postoperative care.

### Other Procedures

TrabEx+ surgery, an ab interno trabeculectomy, offers a minimally invasive approach to managing glaucoma by removing the TM to enhance aqueous humor outflow and IOP. Utilizing a serrated dual-bladed device with integrated irrigation and aspiration ports, TrabEx+ maintains the anterior chamber stability during surgery, eliminating the need for ocular viscoelastic devices. A recent study reported significant outcomes with TrabEx+, showing an average IOP reduction from 31.3 mmHg preoperatively to 20.9 mmHg postoperatively over a follow-up period of up to 38 months. Additionally, the study found that 73% of eyes achieved over a 20% reduction in IOP



without requiring additional surgeries or increased medication, highlighting the procedure's efficacy.<sup>81</sup>

TrabEx+ surgery was performed as a standalone procedure or combined with cataract surgery, with both methods showing substantial IOP reductions and a decrease in the need for glaucoma medications. The incorporation of irrigation and aspiration ports into the TrabEx+ device stabilizes the anterior chamber during surgery, improving surgical precision and reducing complications. Despite these benefits, some patients experienced postoperative complications, such as hyphema and transient IOP spikes, which were managed medically in most cases. Overall, the early results of TrabEx+ surgery demonstrate its potential as a safe and effective option for reducing IOP in glaucoma patients, with the added benefit of minimizing the need for postoperative glaucoma medications. Gosling et al.<sup>81</sup> underscored the need for further long-term research to fully establish the procedure's efficacy and safety profile over extended follow-up periods. These findings align with the growing trend of utilizing MIGS to provide safer and more effective alternatives to traditional filtration surgeries.

The Streamline® (New World Medical) is a MIGS system aimed at enhancing aqueous humor outflow by targeting Schlemm's canal. Unlike trabeculotomy, it employs canaloplasty, involving cannulation and viscodilation of Schlemm's canal. The device features a disposable stainless-steel cutting cannula within a polymer sleeve, introduced through a corneal incision. Upon retraction, it creates a 150-µm goniotomy and injects viscoelastic material to dilate the canal and collector channels, reducing

IOP. FDA-approved in 2021, initial trials show promising IOP reduction and medication decrease at 6 months.<sup>82</sup> Further studies are needed to assess its long-term efficacy and safety.

## Conclusion

This review of various MIGS procedures highlights advancements in techniques aimed at reducing IOP by enhancing aqueous humor outflow. Devices like the TrabEx+, Streamline, and KDB demonstrate significant IOP reductions and decreased medication dependence with favorable safety profiles. These MIGS procedures offer less invasive alternatives to traditional filtration surgeries and show promising short-term results. However, further long-term studies are needed to fully establish their efficacy and safety, ensuring sustainable benefits for glaucoma patients. [Table 1](#) provides a comparative summary of various ab interno goniectomy techniques, highlighting their pressure-lowering effects, strengths, weaknesses, and recommended clinical applications.

Additionally, the success of angle surgeries heavily relies on the surgeon's proficiency in gonioscopy, which is critical for proper angle assessment, surgical planning, and intraoperative visualization. Gonioscopy training should be emphasized as a cornerstone in the skill set of ophthalmic surgeons performing angle surgeries. Enhanced gonioscopy proficiency can improve surgical outcomes, reduce complications, and expand the accessibility of MIGS procedures by increasing surgeon confidence and competence.

**Table 1. Summary of ab interno goniectomy techniques**

Technique	Pressure-lowering effect	Strengths	Weaknesses	Recommended for
<b>GATT</b>	30-50% reduction	Minimally invasive; effective in various glaucomas	Requires skill; hyphema risk	Mild to advanced OAG
<b>Trabectome</b>	20-40% reduction	Minimal inflammation; combines with phaco	Blood reflux; less predictable in PEXG	Early to moderate OAG
<b>BANG</b>	Comparable to marketed devices	Cost-effective; simple setup	Limited data; potential for IOP spikes	Mild to moderate OAG, resource-limited settings
<b>OMNI</b>	20-30% reduction	Targets proximal and distal resistance	Device cost; mild transient inflammation	Mild to moderate glaucoma
<b>KDB</b>	25-40% reduction	Safe and effective; combines with cataract surgery	Hyphema; less efficacy in advanced stages	Mild to moderate glaucoma

GATT: Gonioscopy-assisted transluminal trabeculotomy, BANG: Bent ab interno needle goniectomy, KDB: Kahook Dual Blade, PEXG, Pseudoexfoliative glaucoma, IOP: Intraocular pressure, OAG: Open-angle glaucoma

## Declarations

### Authorship Contributions

Surgical and Medical Practices: Z.A., S.D., M.S., I.W., A.S., M.K., Concept: Z.A., A.Y.Ü., Design: Z.A., Data Collection or Processing: Z.A., S.D., M.S., A.Y.Ü., I.W., A.S., M.K., Analysis or Interpretation: Z.A., S.D., M.S., A.Y.Ü., I.W., A.S., M.K., Literature Search: Z.A., S.D., M.S., A.Y.Ü., I.W., A.S., M.K., Writing: Z.A., S.D., M.S., A.Y.Ü., I.W., A.S., M.K.

**Conflict of Interest:** No conflict of interest was declared by the authors.

**Financial Disclosure:** The authors declared that this study received no financial support.

## References

- Dorairaj SK, Kahook MY, Williamson BK, Seibold LK, ElMallah MK, Singh IP. A multicenter retrospective comparison of goniotomy versus trabecular bypass device implantation in glaucoma patients undergoing cataract extraction. *Clin Ophthalmol.* 2018;12:791-797.
- Dorairaj S, Radcliffe NM, Grover DS, Brubaker JW, Williamson BK. A review of excisional goniotomy performed with the Kahook Dual Blade for glaucoma management. *J Curr Glaucoma Pract.* 2022;16:59-64.
- Seibold LK, Soohoo JR, Ammar DA, Kahook MY. Preclinical investigation of ab interno trabeculectomy using a novel dual-blade device. *Am J Ophthalmol.* 2013;155:524-529.
- Kuerten D, Walter P, Baumgarten S, Fuest M, Plange N. 12-month outcomes of ab interno excisional goniotomy combined with cataract surgery in primary open-angle glaucoma and normal tension glaucoma. *Int Ophthalmol.* 2023;43:2605-2612.
- ElMallah MK, Berdahl JP, Williamson BK, Dorairaj SK, Kahook MY, Gallardo MJ, Mahootchi A, Smith SN, Rappaport LA, Diaz-Robles D, Lazcano-Gomez GS. Twelve-month outcomes of stand-alone excisional goniotomy in mild to severe glaucoma. *Clin Ophthalmol.* 2020;14:1891-1897.
- Dorairaj SK, Seibold LK, Radcliffe NM, Aref AA, Jimenez-Román J, Lazcano-Gomez GS, Darlington JK, Mansouri K, Berdahl JP. 12-month outcomes of goniotomy performed using the Kahook Dual Blade combined with cataract surgery in eyes with medically treated glaucoma. *Adv Ther.* 2018;35:1460-1469.
- Barkander A, Economou MA, Jóhannesson G. Kahook Dual-Blade goniotomy with and without phacoemulsification in medically uncontrolled glaucoma. *Clin Ophthalmol.* 2023;17:1385-1394.
- Albuainain A, Al Habash A. Three-year clinical outcomes of phacoemulsification combined with excisional goniotomy using the Kahook Dual Blade for cataract and open-angle glaucoma in Saudi Arabia. *Saudi J Ophthalmol.* 2022;36:213-217.
- Iwasaki K, Kakimoto H, Orii Y, Arimura S, Takamura Y, Inatani M. Long-term outcomes of a Kahook Dual Blade procedure combined with phacoemulsification in Japanese patients with open-angle glaucoma. *J Clin Med.* 2022;11:1354.
- Wagner IV, Boopathiraj N, Lentz C, Dorairaj EA, Draper C, Kumar D, Checo L, Miller DD, Krambeer C, Dorairaj S. Long-term efficacy of successful excisional goniotomy with the Kahook Dual Blade. *Clin Ophthalmol.* 2024;18:713-721.
- Dorairaj S, Tam MD. Kahook Dual Blade excisional goniotomy and goniosynechialysis combined with phacoemulsification for angle-closure glaucoma: 6-month results. *J Glaucoma.* 2019;28:643-646.
- Dorairaj S, Tam MD, Balasubramani GK. Twelve-month outcomes of excisional goniotomy using the Kahook Dual Blade® in eyes with angle-closure glaucoma. *Clin Ophthalmol.* 2019;13:1779-1785.
- Dorairaj S, Tam MD, Balasubramani GK. Two-year clinical outcomes of combined phacoemulsification, goniosynechialysis, and excisional goniotomy for angle-closure glaucoma. *Asia Pac J Ophthalmol (Phila).* 2020;10:183-187.
- Al Habash A, Albuainain A. Long term outcome of combined phacoemulsification and excisional goniotomy with the Kahook Dual Blade in different subtypes of glaucoma. *Sci Rep.* 2021;11:10660.
- Boopathiraj N, Wagner IV, Lentz PC, Draper C, Krambeer C, Abubaker YS, Ang BCH, Miller DD, Dorairaj S. 36-month outcomes of standalone Kahook Dual Blade goniotomy compared with ab-interno closed conjunctiva Xen gel stent implantation. *Clin Ophthalmol.* 2024;18:2593-2603.
- Matsuo M, Ichioka S, Harano A, Takayanagi Y, Tanito M. Minimally invasive direct internal cyclohexy in the management of goniotomy-related cyclodialysis cleft with hypotony maculopathy. *Int Med Case Rep J.* 2024;17:545-553.
- Ammar DA, Seibold LK, Kahook MY. Preclinical investigation of goniotomy using four different techniques. *Clin Ophthalmol.* 2020;14:3519-3525.
- Ammar DA, Porteous E, Kahook MY. Preclinical investigation of ab interno goniotomy using three different techniques. *Clin Ophthalmol.* 2023;17:2619-2623.
- Balas M, Mathew DJ. Minimally invasive glaucoma surgery: a review of the literature. *Vision (Basel).* 2023;7:54.
- Grant WM. Experimental aqueous perfusion in enucleated human eyes. *Arch Ophthalmol.* 1963;69:783-801.
- Mäpea O, Bill A. Pressures in the juxtacanalicular tissue and Schlemm's canal in monkeys. *Exp Eye Res.* 1992;54:879-883.
- Bill A, Svedbergh B. Scanning electron microscopic studies of the trabecular meshwork and the canal of schlemm-an attempt to localize the main resistance to outflow of aqueous humor in man. *Acta Ophthalmol.* 1972;50:295-320.
- Allingham RR, De Kater AW, Ethier CR. Schlemm's canal and primary open angle glaucoma: correlation between schlemm's canal dimensions and outflow facility. *Exp Eye Res.* 1996;62:101-109.
- Battista SA, Lu Z, Hofmann S, Freddo T, Overby DR, Gong H. Reduction of the available area for aqueous humor outflow and increase in meshwork herniations into collector channels following acute IOP elevation in bovine eyes. *Invest Ophthalmol Vis Sci.* 2008;49:5346-5352.
- Elhusseiny AM, El Sayed YM, El Sheikh RH, Gawdat GI, Elhilali HM. Circumferential Schlemm's canal surgery in adult and pediatric glaucoma. *Curr Eye Res.* 2019;44:1281-1290.
- Vold SD, Williamson BK, Hirsch L, Aminlari AE, Cho AS, Nelson C, Dickerson JE Jr. Canaloplasty and trabeculotomy with the OMNI system in pseudophakic patients with open-angle glaucoma: the ROMEO study. *Ophthalmol Glaucoma.* 2021;4:173-181.
- Hirsch L, Cortlar J, Vold S, Selvadurai D, Campbell A, Ferreira G, Aminlari A, Cho A, Heersink S, Hochman M, Gallardo M, Williamson B, Phan R, Nelson C, Dickerson JE Jr. Canaloplasty and trabeculotomy ab interno with the OMNI system combined with cataract surgery in open-angle glaucoma: 12-month outcomes from the ROMEO study. *J Cataract Refract Surg.* 2021;47:907-915.
- Williamson BK, Vold SD, Campbell A, Hirsch L, Selvadurai D, Aminlari AE, Cortlar J, Dickerson JE. Canaloplasty and trabeculotomy with the OMNI system in patients with open-angle glaucoma: two-year results from the ROMEO study. *Clin Ophthalmol.* 2023;17:1057-1066.
- Gallardo MJ, Pyfer MF, Vold SD, Sarkisian SR Jr, Campbell A, Singh IP, Flowers B, Dhamdhere K; GEMINI study group. Canaloplasty and trabeculotomy combined with phacoemulsification for glaucoma: 12-month results of the GEMINI study. *Clin Ophthalmol.* 2022;16:1225-1234.
- Greenwood MD, Yadgarov A, Flowers BE, Sarkisian SR Jr, Ohene-Nyako A, Dickerson JE Jr; GEMINI 2 Study Group. 36-month outcomes from the prospective GEMINI study: canaloplasty and trabeculotomy combined with cataract surgery for patients with primary open-angle glaucoma. *Clin Ophthalmol.* 2023;17:3817-3824.
- Asrani S, Zeimer R, Wilensky J, Gieser D, Vitale S, Lindenmuth K. Large diurnal fluctuations in intraocular pressure are an independent risk factor in patients with glaucoma. *J Glaucoma.* 2000;9:134-142.

32. Pyfer MF, Gallardo M, Campbell A, Flowers BE, Dickerson JE Jr, Talla A, Dhamdhare K. Suppression of diurnal (9AM-4PM) IOP fluctuations with minimally invasive glaucoma surgery: an analysis of data from the prospective multicenter single-arm GEMINI study. *Clin Ophthalmol.* 2021;15:3931-3938.
33. Mai DD, Ingram Z, Oberfeld B, Solá-Del Valle D. Combined microinvasive glaucoma surgery - a review of the literature and future directions. *Semin Ophthalmol.* 2023;38:529-536.
34. Dickinson A, Leidy L, Nusair O, Mihailovic A, Ramulu P, Yohannan J, Johnson TV 3rd, Kaleem M, Rachapudi S, An J. Short-term outcomes of Hydrus microstent with and without additional canaloplasty during cataract surgery. *J Glaucoma.* 2023;32:769-776.
35. Terveen DC, Sarkisian SR Jr, Vold SD, Selvadurai D, Williamson BK, Ristvedt DG, Bleeker AR, Dhamdhare K, Dickerson JE Jr. Canaloplasty and trabeculotomy with the OMNI surgical system in OAG with prior trabecular microbypass stenting. *Int Ophthalmol.* 2023;43:1647-1656.
36. Elhousseiny AM, Yannuzzi NA, Khodeiry MM, Lee RK, Smiddy WE. Cost-analysis of surgical intraocular pressure management in glaucoma. *J Glaucoma.* 2021;30:947-951.
37. Mader G, Ghinelli F, Torelli F, Patel C, Masseria C, Dickerson J, Nguyen D, Cantor L. The budget impact of introducing the OMNI surgical system to a United States health plan for managing mild-to-moderate primary open-angle glaucoma. *Expert Rev Pharmacoecon Outcomes Res.* 2023;23:805-812.
38. Zeppa L, Ambrosone L, Guerra G, Fortunato M, Costagliola C. In vivo near-infrared fluorescence imaging of aqueous humor outflow structures. *J Ophthalmol.* 2016;2016:8706564.
39. Sato T, Kawaji T. 12-month randomised trial of 360° and 180° Schlemm's canal incisions in suture trabeculotomy ab interno for open-angle glaucoma. *Br J Ophthalmol.* 2021;105:1094-1098.
40. Song Y, Zhu X, Zhang Y, Shu J, Dang G, Zhou W, Sun L, Li F, Lin F, Zhang Y, Liang X, Wang Z, Zhang Y, Zhang Y, Chen W, Zeng L, Tang L, Xie L, Lam DSC, Wang N, Barton K, Weinreb RN, Zhang X; PVP study group. Outcomes of partial versus complete goniotomy with or without phacoemulsification for primary open angle glaucoma: a multicenter study. *J Glaucoma.* 2023;32:563-568.
41. Grover DS, Godfrey DG, Smith O, Feuer WJ, Montes de Oca I, Fellman RL. Gonioscopy-assisted transluminal trabeculotomy, ab interno trabeculotomy: technique report and preliminary results. *Ophthalmology.* 2014;121:855-861.
42. Grover DS, Fellman RL. Gonioscopy-assisted transluminal trabeculotomy (GATT): thermal suture modification with a dye-stained rounded tip. *J Glaucoma.* 2016;25:501-504.
43. Aktas Z, Ucgul AY, Bektas C, Sahin Karamert S. Surgical outcomes of prolene gonioscopy-assisted transluminal trabeculotomy in patients with moderate to advanced open-angle glaucoma. *J Glaucoma.* 2019;28:884-888.
44. Asafali F, Rajamani M, Ramamurthy C, Chaya CJ, M V. Relationship of degrees of gonioscopy assisted transluminal trabeculotomy and trabecular shelf to success using a marker suture technique. *Eye (Lond).* 2023;37:132-138.
45. Smith BL, Ellyson AC, Kim WI. Trabectome-initiated gonioscopy-assisted transluminal trabeculotomy. *Mil Med.* 2018;183(Suppl 1):146-149.
46. Waldner DM, Chaban Y, Penny MD, Al-Ani A, Belkin A, Ahmed IIK, Schlenker MB, Gooi P. Segmental suture gonioscopy-assisted transluminal trabeculotomy: comparison of superior versus inferior hemisphere outcomes. *J Glaucoma.* 2023;32:396-406.
47. Dar N, Naftali Ben Haim L, Yehezkeili V, Sharon T, Belkin A. Gonioscopy-assisted transluminal trabeculotomy in patients with advanced glaucoma. *Indian J Ophthalmol.* 2023;71:3024-3030.
48. Faria BM, Daga FB, Rebouças-Santos V, Araújo RB, Matos Neto C, Jacobina JS, Faria MAR. Gonioscopy-assisted transluminal trabeculotomy (GATT) outcomes in eyes with open-angle glaucoma resistant to maximum treatment. *Arq Bras Oftalmol.* 2021;84:587-593.
49. Liu WW, Petkovsek D, Shalaby WS, Arbabi A, Moster MR. Four-year surgical outcomes of gonioscopy-assisted transluminal trabeculotomy in patients with open-angle glaucoma. *Ophthalmol Glaucoma.* 2023;6:387-394.
50. Aktas Z, Ozdemir Zeydanli E, Uysal BS, Yigiter A. Outcomes of prolene gonioscopy assisted transluminal trabeculotomy in primary open angle glaucoma and pseudoexfoliation glaucoma: a comparative study. *J Glaucoma.* 2022;31:751-756.
51. Grover DS, Smith O, Fellman RL, Godfrey DG, Gupta A, Montes de Oca I, Feuer WJ. Gonioscopy-assisted transluminal trabeculotomy: an Ab interno circumferential trabeculotomy: 24 months follow-up. *J Glaucoma.* 2018;27:393-401.
52. Rahmatnejad K, Pruzan NL, Amanullah S, Shaukat BA, Resende AF, Waisbourd M, Zhan T, Moster MR. Surgical outcomes of gonioscopy-assisted transluminal trabeculotomy (GATT) in patients with open-angle glaucoma. *J Glaucoma.* 2017;26:1137-1143.
53. Parikh DA, Mellen PL, Kang T, Shalaby WS, Moster MR, Dunn JP. Gonioscopy-assisted transluminal trabeculotomy for the treatment of glaucoma in uveitic eyes. *Ocul Immunol Inflamm.* 2023;31:1608-1614.
54. Belkin A, Chaban YV, Waldner D, Samet S, Ahmed IIK, Gooi P, Schlenker MB. Gonioscopy-assisted transluminal trabeculotomy is an effective surgical treatment for uveitic glaucoma. *Br J Ophthalmol.* 2023;107:690-697.
55. Aktas Z, Ucgul AY, Ozdek S, Boluk CE. Outcomes of gonioscopy-assisted transluminal trabeculotomy in vitrectomized patients with secondary glaucoma after silicone oil removal. *J Glaucoma.* 2021;30:114-118.
56. Smith OU, Butler MR, Grover DS, Kommann HL, Emanuel ME, Godfrey DG, Fellman RL, Feuer W. Twenty-four-month outcome of gonioscopy-assisted transluminal trabeculotomy (GATT) in eyes with prior corneal transplant surgery. *J Glaucoma.* 2022;31:54-59.
57. Hopen ML, Gallardo MJ, Grover D. Gonioscopy-assisted transluminal trabeculotomy in a pediatric patient with steroid-induced glaucoma. *J Glaucoma.* 2019;28:156-158.
58. Fontana L, De Maria M, Iannetta D, Moramarco A. Gonioscopy-assisted transluminal trabeculotomy for chronic angle-closure glaucoma: preliminary results. *Graefes Arch Clin Exp Ophthalmol.* 2022;260:545-551.
59. Sharkawi E, Artes PH, Lindegger DJ, Dari ML, Wardani ME, Pasquier J, Guarnieri A. Gonioscopy-assisted transluminal trabeculotomy in primary angle-closure glaucoma. *Graefes Arch Clin Exp Ophthalmol.* 2021;259:3019-3026.
60. Chira-Adisai T, Mori K, Kobayashi A, Ueno M, Ikeda Y, Sotozono C, Kinoshita S. Outcomes of combined gonioscopy-assisted transluminal trabeculotomy and goniosynechialysis in primary angle closure: a retrospective case series. *Int Ophthalmol.* 2021;41:1223-1231.
61. Aktas Z, Ozmen MC, Ozdemir Zeydanli E, Oral M, Eskalen O. Efficacy and safety of gonioscopy-assisted transluminal trabeculotomy for primary congenital glaucoma. *J Glaucoma.* 2023;32:497-500.
62. Elhousseiny AM, Aboulhassan RM, El Sayed YM, Gawdat GI, Elhilali HM. Gonioscopy-assisted transluminal trabeculotomy following failed glaucoma surgery in primary congenital glaucoma: one-year results. *Case Rep Ophthalmol Med.* 2023;2023:6761408.
63. Grover DS, Smith O, Fellman RL, Godfrey DG, Butler MR, Montes de Oca I, Feuer WJ. Gonioscopy assisted transluminal trabeculotomy: an ab interno circumferential trabeculotomy for the treatment of primary congenital glaucoma and juvenile open angle glaucoma. *Br J Ophthalmol.* 2015;99:1092-1096.
64. Haidu SD, Aktas Z. Gonioscopy-assisted transluminal trabeculotomy for congenital glaucoma secondary to Klippel-Trenaunay-Weber syndrome: a case report. *Am J Ophthalmol Case Rep.* 2022;28:101734.
65. Naftali Ben Haim L, Yehezkeili V, Abergel Hollander E, Dar N, Sharon T, Belkin A. Intraocular pressure spikes after gonioscopy-assisted transluminal trabeculotomy (GATT). *Graefes Arch Clin Exp Ophthalmol.* 2024;262:927-935.
66. Gunay M, Turk A, Ozturk H, Bulanik FT, Uzlu D. Evaluation of peripheral anterior synechia formation following gonioscopy-assisted transluminal trabeculotomy surgery. *Int Ophthalmol.* 2023;43:3045-3053.
67. Rao A, Khan SM, Mukherjee S. Causes of immediate and early IOP spikes after circumferential gonioscopy-assisted transluminal trabeculotomy using ASOCT. *Clin Ophthalmol.* 2023;17:313-320.

68. Ozmen MC, Acar B, Uysal BS. Wipe-out following gonioscopy-assisted transluminal trabeculotomy combined with phacoemulsification. *J Glaucoma*. 2025;34:58-60.
69. Hallaj S, Wong JC, Shalaby WS, Ayres BD, Moster MR. Persistent mydriasis following gonioscopy-assisted transluminal trabeculotomy. *J Glaucoma*. 2024;33:55-58.
70. Espinoza G, Rodriguez-Una I, Pedraza-Concha A. A case of bilateral delayed-onset hyphema following pupil dilation after gonioscopy-assisted transluminal trabeculotomy. *J Curr Glaucoma Pract*. 2020;14:72-75.
71. Aktas Z, Bektas C, Hasanreisoglu M. Panscleritis as an unusual complication of gonioscopy-assisted transluminal trabeculotomy. *J Glaucoma*. 2019;28:21-23.
72. Espinoza G, Pedraza-Concha A, Tello A, Galvis V, Rangel CM, Castellanos YA. Cystoid macular edema after an uncomplicated gonioscopy- assisted transluminal trabeculotomy on a previously vitrectomized patient. *Clin Ter*. 2022;173:198-202.
73. Yalinbas D, Aktas Z, Hepsen İ, Dilekmen N. An unusual complication of combined gonioscopy-assisted transluminal trabeculotomy and phacoemulsification: vision loss due to intracapsular hematoma. *Int Ophthalmol*. 2018;38:2223-2226.
74. Donmez Gun R, Kugu S, Erkan M, Simsek S. Partial schlemm canal, trabecular meshwork, and Descemet membrane separation during gonioscopy-assisted transluminal trabeculotomy: a case report. *J Glaucoma*. 2020;29:1-2.
75. Aktas Z, Ucgul AY, Segawa A. Transient myopia secondary to supraciliary effusion: unusual complication after an uneventful prolene gonioscopy-assisted transluminal trabeculotomy. *J Glaucoma*. 2020;29:60-63.
76. Shute T, Green W, Liu J, Sheybani A. An alternate technique for goniotomy: description of procedure and preliminary results. *J Ophthalmic Vis Res*. 2022;17:170-175
77. Maeda M, Watanabe M, Ichikawa K. Evaluation of trabectome in open-angle glaucoma. *J Glaucoma*. 2013;22:205-208.
78. Mosaed S, Minckler DS, Dustin L. Trabectome outcomes in adult open-angle glaucoma patients: one-year follow-up. *Clin Surg Ophthalmol*. 2010;38:130-135.
79. Kaplowitz K, Bussel II, Honkanen R, Schuman JS, Loewen NA. Review and meta-analysis of ab-interno trabeculectomy outcomes. *Br J Ophthalmol*. 2016;100:594-600.
80. Minckler DS, Mosaed S, Dustin L, Francis BA. Trabectome (trabeculectomy-internal approach): additional experience and extended follow-up. *Trans Am Ophthalmol Soc*. 2008;106:149-159.
81. Gosling D, Wang H, Auger G. Early results of irrigating goniectomy with TrabEx+: a novel device for the treatment of open-angle glaucoma. *J Glaucoma*. 2022;31:268-273.
82. Lazcano-Gomez G, Garg SJ, Yeu E, Kahook MY. Interim analysis of STREAMLINE® surgical system clinical outcomes in eyes with glaucoma. *Clin Ophthalmol*. 2022;16:1313-1320.