



Report of a Rare Syndromic Retinal Dystrophy: Asphyxiating Thoracic Dystrophy (Jeune Syndrome)

● Batuhan Aksoy, ● Gülipek Tigrel

İstanbul University-Cerrahpaşa, Cerrahpaşa Faculty of Medicine, Department of Ophthalmology, İstanbul, Türkiye

Abstract

Jeune syndrome (JS), first described by Jeune as asphyxiating thoracic dystrophy, is an autosomal recessive osteochondrodysplasia with characteristic skeletal abnormalities and variable renal, hepatic, pancreatic, and ocular complications. Approximately 1 in every 100,000 to 130,000 babies is born with JS. Most patients with JS have respiratory distress due to inadequate lung development and many lose their lives due to respiratory failure. Those who survive have serious comorbidities. In terms of ophthalmological diseases, JS is classified among the hereditary syndromic retinopathies. Most, if not all, hereditary syndromic retinopathies can be analyzed in two main groups: inherited metabolic diseases and ciliopathies. The main cause of ocular pathologies in JS is genetic mutations in ciliary proteins that prevent normal function of retinal photoreceptor cells. Here we describe a patient with JS who presented with the complaint of night blindness. Although Snellen visual acuity was 20/20, the patient's visual function was severely impaired due to photoreceptor dysfunction caused by ciliopathy secondary to the genetic mutation. This case shows that in patients with syndromic comorbidities accompanying nyctalopia, even those with perfect visual acuity, hereditary retinal dystrophies should be considered and asphyxiating thoracic dystrophy (JS) included in the differential diagnosis. Multimodal retinal imaging, including structural and functional assessments, should be used for the diagnosis and genetic counselling should also be provided.

Keywords: Jeune syndrome, retinal dystrophies, nyctalopia, asphyxiating thoracic dystrophy, inherited retinal diseases

Introduction

Jeune syndrome (JS), first described by Prasad and Prasad¹ as asphyxiating thoracic dystrophy, is an autosomal recessive osteochondrodysplasia with characteristic skeletal abnormalities and variable renal, hepatic, pancreatic, and ocular complications. Approximately 1 in every 100,000 to 130,000 infants is born with JS.¹

Here we describe a patient with JS who presented with the complaint of night blindness.

Case Report

An 18-year-old boy with JS was referred to our retina clinic from the pediatrics clinic of our university. Detailed systemic and genetic examinations were performed. His parents are first cousins and he was born at term. His physical characteristics at presentation included a narrow rib cage, height of 110 cm, flattened nasal root, wide nasal tip, disproportionate shortening of all limbs (more pronounced the upper limbs), and short, thick fingers. He has no intellectual disability. In the exome sequencing panel performed on the Illumina Nextseq platform, homozygous variants were evaluated first due to the familial consanguinity. Then, OMIM genes associated with JS and primary ciliary dyskinesia were filtered. The results revealed a c21+26_21+33dupTGAGCGGG variation in the *TTC21B* gene that was homozygous in the patient and heterozygous in his parents. Ophthalmological examination revealed bilateral best-corrected visual acuity of 0.9-1.0 decimal. Refractive errors were +1.00 diopter (D) spherical and +1.50 D cylindrical (95° axis) in the right eye and +1.25 D spherical and +1.50 D cylindrical (85° axis) in the left eye. Globe movements in all directions were normal bilaterally. Direct and indirect light reflexes were normal and there was no relative afferent pupillary defect bilaterally. No pathology was detected on bilateral slit-lamp examination. Central corneal thickness was

Cite this article as: Aksoy B, Tigrel G. Report of a Rare Syndromic Retinal Dystrophy: Asphyxiating Thoracic Dystrophy (Jeune Syndrome). *Turk J Ophthalmol*. DOI: 10.4274/tjo.galenos.2024.76574. [Ahead of Print].

Address for Correspondence: Batuhan Aksoy, İstanbul University-Cerrahpaşa, Cerrahpaşa Faculty of Medicine, Department of Ophthalmology, İstanbul, Türkiye
E-mail: draksoybatu@gmail.com ORCID-ID: orcid.org/0009-0008-4742-5643
Received: 24.06.2024 Accepted: 12.10.2024

DOI: 10.4274/tjo.galenos.2024.76574



626 μm in the right eye and 642 μm in the left eye. Bilateral fundoscopic examination revealed retinal pigment epithelium (RPE) alterations. Changes in the RPE were observed both in the fundus examinations and in color fundus photographs taken with a Zeiss Visucam 500 fundus camera system (Figure 1). Fundus autofluorescence examination with the same system revealed a hyper-autofluorescent Robson-Holder ring (Figure 2). Optical coherence tomography (OCT) macula scan (Avanti RTVue XR) to evaluate the retinal architecture demonstrated fovea-sparing ellipsoid zone defects, thinning of the outer nuclear layer, and thinning of the reflex of the RPE-Bruch's membrane complex (Figure 3). Flash visual evoked potential test was performed in the electrophysiology clinic of our university. Amplitude and latency values were found to be within normal limits for both eyes. In the flash electroretinogram test, bilateral latency values were found to be within the normal range, while amplitude values were found to be severely low (Table 1). Other advanced tests could not be performed due to technical limitations in our electrophysiology laboratory. These results pointed to retinal dystrophy associated with ciliopathies caused by the *TTC21B* gene mutation.

Discussion

Asphyxiating thoracic dystrophy (JS) is a rare autosomal recessive ciliopathy characterized by multiple musculoskeletal abnormalities, multi-organ involvement, and variable severity. JS was first recognized in 1954.² One of the most commonly described defects is a mutation in the *DYNC2H1* gene.³ The prevalence of JS is 1 in 100,000 to 130,000.¹ Children with JS

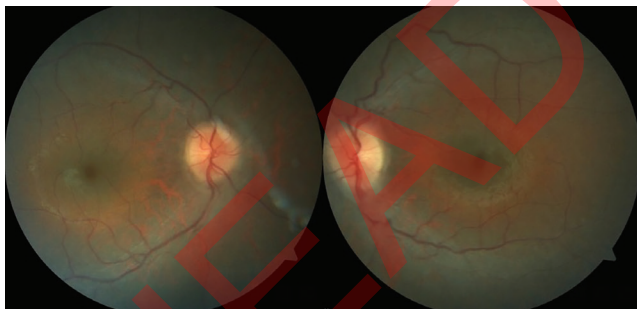


Figure 1. Color fundus photography revealed diffuse retinal pigment epithelial changes

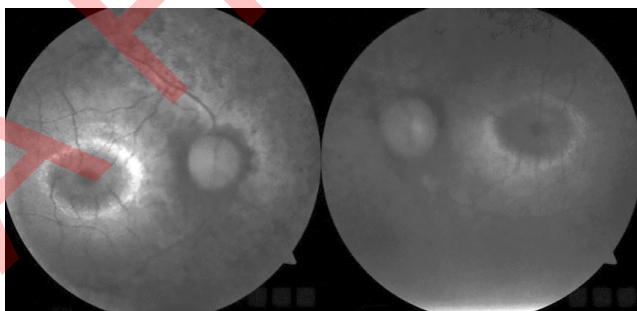


Figure 2. Fundus autofluorescence imaging revealed a hyper-autofluorescent Robson-Holder ring

often present with respiratory distress and recurrent infections in the neonatal period, although it has been found that respiratory problems tend to decrease with age in long-term survivors. Kidney, liver, and retinal function should be monitored regularly in these patients. Tüysüz et al.⁴ stated that besides the clinical variability, prognosis also differs greatly among patients. It is difficult to differentiate JS from chondroectodermal dysplasia (Ellis-van Creveld syndrome).⁵ There are also no genetic or biochemical markers that can be used effectively in the prenatal diagnosis of the disease.⁶

Retinal dystrophies are a clinically and genetically heterogeneous group of degenerative diseases of the retina. Haim⁷ described retinal dystrophies as a group of conditions with various clinical manifestations which are estimated to affect as many as 1 in 4,000 individuals. By more recent estimates, the prevalence is approximately 1 in 1,380, and 5.5 million people worldwide are believed to be affected.⁸ Tatour and Ben-Yosef⁹ reported that over 80 forms of syndromic inherited retinal diseases have been described and approximately 200 genes identified in association with these syndromes. They are classified into two major disease groups: inborn errors of metabolism and ciliopathies. Common manifestations include color blindness or night blindness, abnormalities of peripheral vision, and the subsequent progression to complete blindness in those with progressive disease. Many causative genetic defects have been identified.

The main cellular units responsible for visual phototransduction are rod and cone photoreceptors. Rhodopsin is composed of opsin protein and 11-cis retinal, a form of vitamin A. When light is absorbed by the retina, the structure of the opsin protein changes and the G-protein cascade begins.¹⁰ Phototransduction is the process by which light signals are converted into action potentials in the retina, thus facilitating the perception of an image by the brain. During this process, photosensitive pigments are produced and recycled. Retinal dystrophies result from both photoreceptor abnormalities

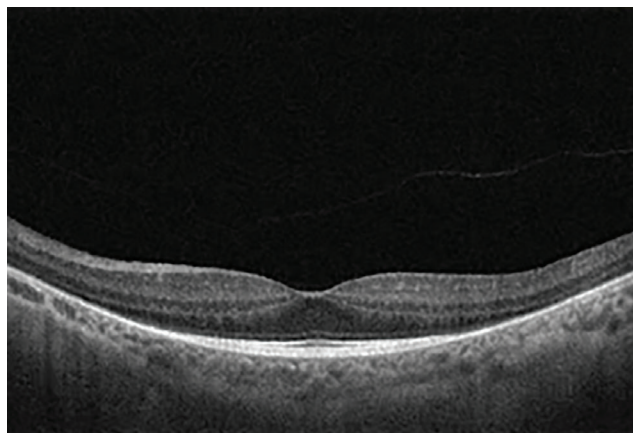


Figure 3. Optical coherence tomography macula section demonstrated fovea-sparing defects of the ellipsoid zone, thinning of the outer nuclear layer, and thinning of the reflex of the RPE-Bruch's membrane complex

RPE: Retinal pigment epithelium

Table 1. Flash visual evoked potential (VEP) and electroretinography (ERG) results interpreted according to International Society for Clinical Electrophysiology of Vision criteria (normal values for VEP: N2 latency <90 ms, P2 latency <120 ms, amplitude: >3.5 mV; for ERG: a wave latency <55 ms, b wave latency <85 ms, amplitude >10 mV). The a-wave represents photoreceptor response, while the b-wave represents activities of bipolar cells or Müller cells

Flash VEP	N2	P2	Amplitude	
	Latency	Latency		
Bilateral	Normal	Normal	Normal	
Right	Normal	Normal	Normal	
Left	Normal	Normal	Very low	
Flash ERG	a	b	Amplitude	b/a
	Latency	Latency		
Right	Normal	Normal	Very low	a wave dominant
Left	Normal	Normal	Very low	a wave dominant

and phototransduction defects. Genetic tests can be used to analyze the mutations involved. Management aims at slowing the degenerative process, treating complications, and helping patients to cope with the social and psychological impact of blindness.¹¹

Nyctalopia, or night blindness, is a condition that makes it difficult or impossible to see in relatively dim light. It is a symptom of many eye diseases. Night blindness can be present from birth or result from injury or poor nutrition. It can be described as inadequate adaptation to darkness. The most common cause of nyctalopia is retinitis pigmentosa, a disorder in which the rod cells in the retina gradually lose their ability to respond to light.

Multimodal structural and functional imaging modalities such as spectral-domain OCT, color fundus photography, fundus autofluorescence, and electrophysiological testing are used in the diagnosis and follow-up of retinal dystrophies. The Robson-Holder ring is among the retinal examination findings and consists of perifoveal hyper-autofluorescence surrounding centrally preserved retinal structure and function. Early descriptions attributed Robson-Holder rings to increased RPE lipofuscin and photoreceptor pigment changes. However, due to an unmasking effect, reduced macular pigment overlying the RPE increases the intrinsic fundus autofluorescence. It is likely that one of the mechanisms responsible for the hyperautofluorescent rings is reduced macular pigment at greater eccentricities from the foveal center.¹²

In our case, we reported a patient with Snellen best corrected visual acuity of 20/20 but night blindness. Genetic testing revealed a mutation in the *TTC21B* gene compatible with JS. The patient also had musculoskeletal changes phenotypically consistent with the disease. Although visual acuity was 20/20, the patient had difficulty in night vision. Multimodal retinal imaging showed changes compatible with retinal dystrophy. OCT showed a preserved fovea but outer retinal zone atrophy. Color fundus photography and fundus autofluorescence imaging indicated a preserved macula and peripheral chorioretinal atrophy. Electrophysiological test results were also consistent with retinal dystrophy.

As in our case, mutations in the *TTC21B* gene cause ciliopathies in humans. Specialized sensory cilia in the photoreceptors of the eye are responsible for converting light stimuli into neural responses. Inherited retinal degenerations are caused by mutations in several photoreceptor-specific and common ciliary genes.

Although our patient had 20/20 visual acuity according to Snellen chart, his visual function was severely impaired due to photoreceptor dysfunction caused by ciliopathy secondary to the genetic mutation.

In conclusion, asphyxiating thoracic dystrophy (JS) should be kept in mind during the differential diagnosis of retinal dystrophies that cause nyctalopia, and multimodal retinal imaging, including structural and functional assessments, should be used for diagnosis.

Ethics

Informed Consent: Obtained.

Declarations

Authorship Contributions

Surgical and Medical Practices: G.T., B.A., Concept: G.T., B.A., Design: G.T., B.A., Data Collection or Processing: G.T., B.A., Analysis or Interpretation: G.T., B.A., Literature Search: G.T., B.A., Writing: G.T., B.A.

Conflict of Interest: No conflict of interest was declared by the authors.

Financial Disclosure: The authors declared that this study received no financial support.

References

- Prasad PL, Prasad AN. Jeune syndrome. Med J Armed Forces India. 2006;62:293-294.
- Jeune M, Beraud C, Carron R. Dystrophie thoracique asphyxiante de caractère familial [Asphyxiating thoracic dystrophy with familial characteristics]. Arch Fr Pediatr. 1955;12:886-891.
- Emiralioglu N, Wallmeier J, Olbrich H, Omran H, Özçelik U. DYNC2H1 mutation causes Jeune syndrome and recurrent lung infections associated with ciliopathy. Clin Respir J. 2018;12:1017-1020.
- Tüysüz B, Barış S, Aksoy F, Madazli R, Ungür S, Sever L. Clinical variability of asphyxiating thoracic dystrophy (Jeune) syndrome: Evaluation

- and classification of 13 patients. *Am J Med Genet A*. 2009;149:1727-1733.
5. Kozłowski K, Szmigiel C, Barylak A, Stopyrowa M. Difficulties in differentiation between chondroectodermal dysplasia (Ellis-van Creveld syndrome) and asphyxiating thoracic dystrophy. *Australas Radiol*. 1972;16:401-410.
 6. de Vries J, Yntema JL, van Die CE, Crama N, Cornelissen EA, Hamel BC. Jeune syndrome: description of 13 cases and a proposal for follow-up protocol. *Eur J Pediatr*. 2010;169:77-88.
 7. Haim M. Epidemiology of retinitis pigmentosa in Denmark. *Acta Ophthalmol Scand Suppl*. 2002;233:1-34.
 8. Ben-Yosef T. Inherited retinal diseases. *Int J Mol Sci*. 2022;23:13467.
 9. Tatour Y, Ben-Yosef T. Syndromic inherited retinal diseases: genetic, clinical and diagnostic aspects. *Diagnostics (Basel)*. 2020;10:779.
 10. Burns ME, Pugh Jr EN. Visual transduction by rod and cone photoreceptors” in *The New Visual Neurosciences*. In: Chalupa LM, Werner JH, eds. Cambridge MA: MIT Press; 2014:7-19.
 11. Hamel CP. Cone rod dystrophies. *Orphanet J Rare Dis*. 2007;2:7.
 12. Cabral D, Ramtohul P, Freund KB. Reassessment of hyperautofluorescent rings in retinitis pigmentosa using novel retinal imaging techniques. *Am J Ophthalmol Case Rep*. 2023;32:101872.

A HEAD OF PRINT