



## Demographic, Etiological, and Clinical Characteristics of Eyelid Lacerations

Emine Doğan\*, Şule Bahadır Coşkun\*, Büşra Güner Sönmezoğlu\*\*, Gürsoy Alagöz\*

\*Sakarya University Training and Research Hospital, Clinic of Ophthalmology, Sakarya, Türkiye

\*\*Serdivan State Hospital, Clinic of Ophthalmology, Sakarya, Türkiye

### Abstract

**Objectives:** To evaluate the demographic, etiological, and accompanying clinical factors in eyelid lacerations (EL).

**Materials and Methods:** The records of patients who presented to our clinic between 2018 and 2022 with eyelid trauma were retrospectively reviewed. Age, gender, cause of injury, clinical findings, accompanying ocular findings, and additional complications were analyzed.

**Results:** The study included 135 patients (106 male, 29 female) with a mean age of  $37.0 \pm 18.6$  years. Among the patients, 29 (21.4%) were 18 years old or younger, 93 (68.8%) were between 19 and 64 years old, and 13 (9.6%) were 65 years old or older. EL were most caused by various sharp objects in 44 patients (33%), blunt trauma in 40 patients (30%), falls in 30 patients (22%), and traffic accidents in 21 patients (15%). Fifteen eyes (11.1%) had foreign bodies at the wound site. Thirty patients (22.2%) (20 lower eyelid, 10 upper eyelid) had accompanying canalicular lacerations. Twenty-three (17%) patients had accompanying conjunctival lacerations, 14 (10.3%) had open-globe injury, 10 (7.4%) had corneal epithelial defects, 9 (6.6%) had intravitreal hemorrhage, 6 (4.4%) had hyphema, and 5 (3.7%) had retinal detachment. Four patients had lid notching and 1 patient (0.7%) had ectropion. Five patients (3.7%) required suturing. No additional complications were observed.

**Conclusion:** EL are more commonly seen in young adulthood and in males. The most common mechanism of injury is impact by various objects. Eyelash margin and canalicular lacerations frequently accompany these injuries. Serious ocular pathologies such as hyphema and open-globe injury can accompany eyelid trauma.

**Keywords:** Eyelid trauma, epidemiology, complications

### Introduction

The eyelids, which protect the globe against external factors, are frequently affected by orbital and periorbital trauma. Eyelid traumas encompass a wide spectrum, ranging from simple lacerations to more severe injuries that can lead to deeper tissue damage and vision-threatening globe injuries. Eyelid injuries account for approximately 10% of all ocular injuries, with an incidence of 185.9 per million reported in a study conducted in the United States (US).<sup>1</sup> The causes of eyelid trauma are often preventable, vary in frequency according to age group, socio-economic status, and geographical region, and include workplace-related injuries, falls, traffic accidents, sports injuries, and assaults.<sup>2</sup>

Eyelid lacerations (EL) present with various findings, such as partial- or full-thickness lid defects, canalicular damage, and accompanying ocular damage.<sup>3,4</sup> If not promptly and appropriately treated, these injuries can result in serious anatomic and functional problems, including lid deformities, ocular surface disorders, and associated ocular damage.<sup>5</sup> Incomplete or inadequate repair of the eyelids may lead to complications such as entropion, ectropion, trichiasis, and epiphora, significantly affecting the patient's quality of life.<sup>5,6</sup>

Understanding the factors that contribute to eyelid trauma and having knowledge of the epidemiological features are crucial in the prevention of such injuries. While there are numerous publications on ocular trauma in the literature, studies specifically focusing on eyelid injuries are relatively limited, often being included within the broader category of ocular trauma.

The aim of this study was to determine the demographics, epidemiological factors, and clinical characteristics of EL.

### Materials and Methods

The data of patients who presented to the emergency department due to eyelid trauma and were subsequently referred to the ophthalmology department for EL between 2018 and

**Cite this article as:** Doğan E, Bahadır Coşkun Ş, Güner Sönmezoğlu B, Alagöz G. Demographic, Etiological, and Clinical Characteristics of Eyelid Lacerations. *Turk J Ophthalmol* 2024;54:17-22

Address for Correspondence: Emine Doğan, Sakarya University Training and Research Hospital, Clinic of Ophthalmology, Sakarya, Türkiye

E-mail: dremined@yahoo.com ORCID-ID: orcid.org/0000-0002-6505-3328

Received: 07.08.2023 Accepted: 15.12.2023

DOI: 10.4274/tjo.galenos.2023.05684

2022 were retrospectively analyzed. Approval for this study was received from the Sakarya University Faculty of Medicine Ethics Committee (decision no: E-71522473-050.01.04-241666-111) and was conducted in accordance with the principles outlined in the Declaration of Helsinki. Written informed consent was obtained from all patients included in the study.

The medical records of 135 patients who were followed up for at least 3 months were reviewed and the following information was collected: demographic data (age, gender, laterality), the cause and nature of the trauma, the presence of eyelid margin and canalicular injuries, the presence of foreign bodies, and accompanying clinical findings such as conjunctival laceration, corneal abrasion, hyphema, and open-globe injury. Based on the involvement of the eyelid margin or canaliculus, trauma type was classified as eyelid margin involvement, canalicular involvement, or only periocular involvement. Details of the surgical procedures performed (primary and additional) and findings from follow-up examinations, including any ocular complications, were also reviewed.

EL were ideally repaired within 12 to 24 hours of the injury to minimize future complications. In patients with life-threatening injuries, EL repair was delayed until an appropriate time, after the wound had been cleaned and adequate corneal lubrication had been achieved.

In cooperative adults, most EL were managed using local anesthesia, while in cases involving small children or EL with canalicular or open-globe injury, general anesthesia was typically employed.

In simple superficial EL affecting only the anterior lamella, the wound was first irrigated with saline solution to remove all foreign bodies and debris. Then subcutaneous suturing with 6-0 or 7-0 polyglactin (Vicryl, Ethicon, Ohio, USA) was done, followed by reapproximating the wound edges using simple interrupted sutures using 6-0 or 7-0 nylon or polypropylene (Prolene, Ethicon, Ohio, USA) for non-absorbable sutures, or 6-0 polyglactin absorbable sutures. Non-absorbable sutures were avoided in patients who were unlikely to be compliant with follow-up (such as children and patients with dementia).

In cases of EL involving the eyelid margin, the process began with suturing the edges of eyelid margin using one simple interrupted 6-0 polyglactin suture from gray line to gray line. Then, the tarsus was reapproximated using several additional interrupted lamellar 6-0 polyglactin sutures. Subsequently, one or two additional 6-0 polyglactin sutures were applied at the eyelid margin parallel to the first but closer to the lash line in an interrupted vertical mattress or buried interrupted fashion. The wound edges in the skin were then sutured with absorbable polyglactin sutures. If there was a canalicular injury, the procedure involved reuniting the two edges of the canaliculus using bicanalicular intubation with a pigtail probe or monocanalicular stent, after which the EL was repaired.

After EL repair, topical antibiotic or a combination of antibiotic and steroid ointment was applied to the wound. Oral antibiotics were prescribed if the wound was contaminated, such as a bite wound, or if the patient was at high risk of infection.

Patients were typically examined 5-14 days later for any complications and the removal of any non-absorbable sutures.

### Statistical Analysis

Data were analyzed using the Statistical Package for the Social Sciences version 15 (SPSS Inc, Chicago, IL, USA) and descriptive variables were reported as number and percentage.

## Results

The mean age of the 135 patients (106 male, 29 female) was  $37.0 \pm 18.6$  years. The male to female ratio was 3.9:1. Most of the patients were between the ages of 19 and 64 years. The right and left eyes were similarly affected ( $p=0.942$ ). Of the EL, 54 involved the lower eyelid, 70 involved the upper eyelid, and 11 included both eyelids ([Table 1](#), [Figure 1](#)).

The most frequent causes of EL were various sharp objects (glass, scissors, iron, twig, wire, cat scratch, drill, nails, umbrella, hook) in 44 patients (33%), blunt trauma (assault, horn) in 40 patients (30%), falls in 30 patients (22%), and traffic accidents in 21 patients (15%) ([Figure 2](#)). When examined by age group, the most common cause of EL was trauma with sharp objects in patients aged 18 and under, blunt trauma in patients between the ages of 19 and 64, and falls in patients 65 and over ([Table 2](#)).

In the classification of trauma types, it was determined that of the 135 patients, 37 (27.4%) had full-thickness EL, 30 (22.2%) had full-thickness laceration involving the lacrimal passage, and 68 (50.3%) had laceration limited to the periocular area ([Figure 3](#)). Among the patients with lacrimal passage injury, 20 (66.6%) had lower canalicular injury and 10 (33.3%) had upper canalicular injury. Falls were found to be the most common cause of injury in these patients.

Fifteen patients (11.1%) had a foreign body present in the trauma region ([Figure 4](#)). The most common clinical findings accompanying the EL were conjunctival laceration in 23 patients (17%) and open-globe injury in 14 patients (10.3%). Other accompanying clinical findings are listed in [Table 3](#). Among patients with additional ocular findings, the 19-64 age group was the most frequently affected, with traffic accidents and injuries with blunt objects being the most common causes.

Primary suturing was performed in all patients, and in most cases, the tissues could be approximated to their normal anatomical position. Lateral canthotomy was performed in 3 patients who had tissue loss. Conjunctival suturing was performed in 16 patients, while repair of penetrating eye injuries was performed in 14 patients. Lens extraction and anterior vitrectomy were performed in 1 patient ([Figure 5](#)).

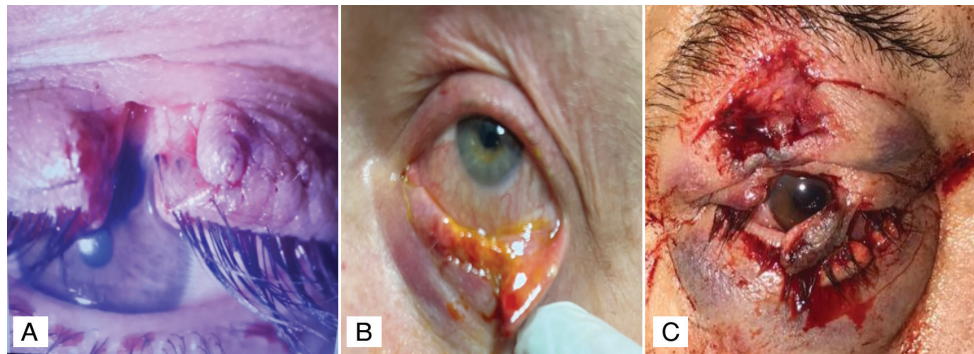
For patients with open-globe injury, reparation was performed prior to eyelid repair to prevent further damage due to increased intraocular pressure. In cases of canalicular lacerations, monocanalicular silicone intubation was performed in 20 patients and annular intubation in 10 patients. Among patients who underwent canalicular repair, anatomical success was achieved in 96.6% and functional success was achieved in 86%.

During follow-up, most of the patients had acceptable aesthetic outcomes. Only 4 patients showed lid notching, and 1 patient developed ectropion. In the early period, 5 patients underwent re-suturing due to wound dehiscence caused by tension at the wound site or improper wound configuration leading to lid malposition. In 2 patients who had irregularity at the wound site, fusiform excisions or Z-plasty was used to improve the appearance of scars and eliminate contracture, after the scar tissue was removed. The patient with ectropion was followed until scar maturation, and spontaneous resolution was observed after a period of 3-6 months. Of the patients with canalicular injury, 4 had epiphora. In 2 of these patients, the silicone stents spontaneously detached from their lacrimal passages, while the other 2 patients had their silicone stents removed early due to foreign body sensation and pain.

### Discussion

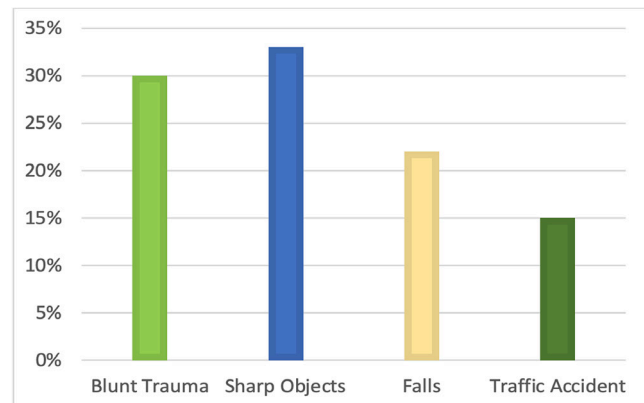
EL are common ophthalmic injuries that require prompt assessment and appropriate management to minimize the risk of complications. The incidence of EL in the US has been reported as approximately 1.7 million cases per year, while in the UK this rate has been reported as 8.3 to 13.2 cases per 100,000 population per year.<sup>1</sup> In a study conducted in our country, this rate was reported as 5.9%.<sup>7</sup>

Consistent with other studies, our results showed that EL are more common in men, with a ratio of 3.9:1.<sup>2,3</sup> In a publication conducted in Türkiye, similar to our results, the reported ratio was 3.75:1.<sup>7</sup> This may be related to the more frequent participation of men in activities that can increase the risk of eye injury, such as occupational or industrial



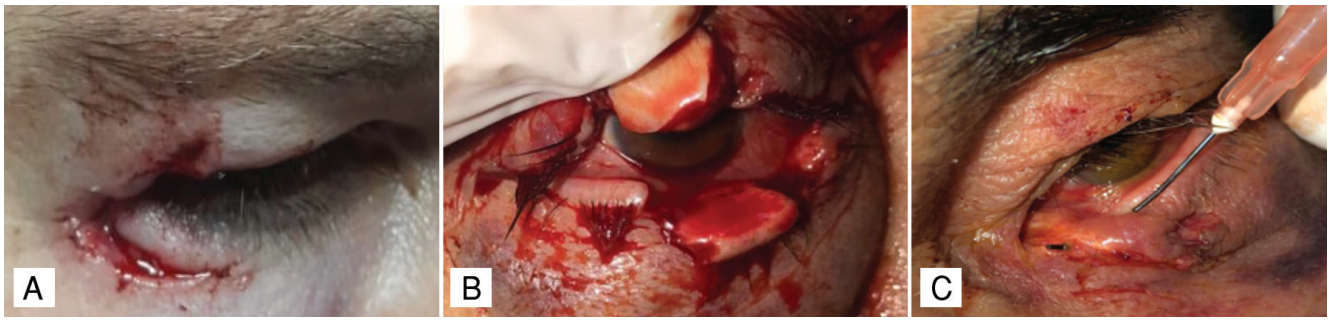
**Figure 1.** Preoperative photos of patients. (A) Patient with upper eyelid laceration. (B) Patient with lower eyelid laceration. (C) Patient with both upper and lower eyelid laceration

Table 1. Demographic characteristics of eyelid lacerations		
	n	%
Age (years), mean ± SD	37.0±18.6	
≤18	29	21.4
19-64	93	68.8
≥65	65	9.6
Gender		
Female	29	21.4
Male	106	78.5
Laterality		
Right	68	50.3
Left	67	49.6
Eyelid		
Lower	54	40
Upper	70	51.8
Both	11	8.1
Trauma type		
Periocular	68	50.3
Full-thickness	37	27.4
Canalicular	30	22.2
SD: Standard deviation		

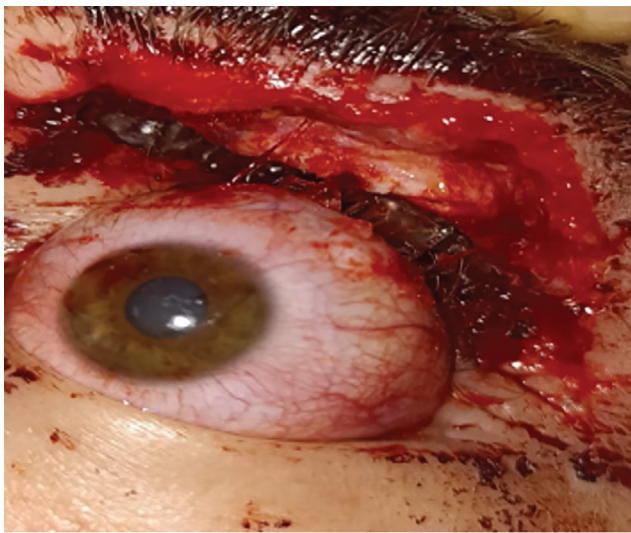


**Figure 2.** Causes of eyelid lacerations

Table 2. Causes of eyelid lacerations by age group								
Age (years)	Sharp objects		Blunt trauma		Falls		Traffic accidents	
	n	%	n	%	n	%	n	%
≤18	14	73.6	6	20.6	5	17.2	4	13.7
19-64	30	32.2	33	35.4	13	13.9	17	18.2
≥65			1	7.6	12	92.3		



**Figure 3.** Preoperative photos of patients. (A) Patient with periocular laceration. (B) Patient with full-thickness laceration with lid margin involvement on both lower and upper eyelids. (C) Patient with lower canalicular tear

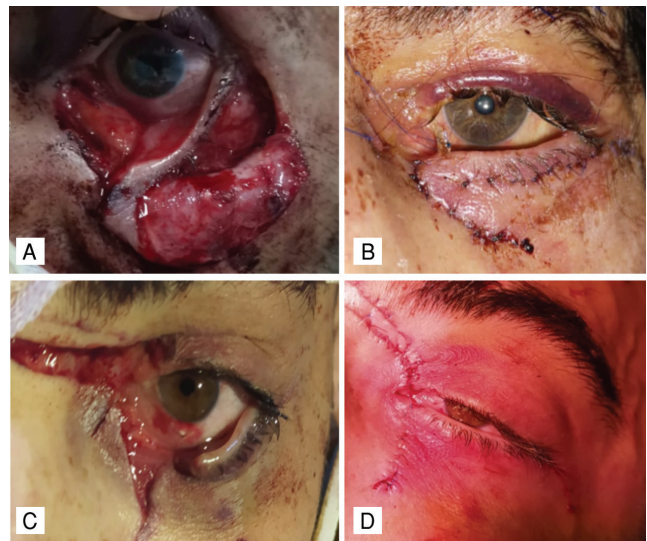

**Figure 4.** Patient with periocular laceration with multiple foreign bodies (glass) in the upper bulbar space

activities (construction, manufacturing), sports or recreational activities (contact sports, shooting, hunting), and certain hobbies (woodworking, metalworking).<sup>8</sup>

Considering the distribution of EL by age group in the literature, most injuries were reported in adolescence and the average age was around 30 years. Of the total, 23% of patients were between the ages of 0-9 years, 18% were between the ages of 9-18 years, and 6% were aged 60 and over.<sup>9</sup> These results may be attributed to a higher level of active work participation among individuals aged 20-50. The results of our study are consistent with the literature. Most of the patients (68.8%) were between the ages of 19-64, the mean age was 37.0±18.6 years, 21.4% all patients were aged 18 years or younger, and 9.6% were aged 65 and over.

Considering the etiology of injury in the literature, the prevalence in different countries may vary due to differences in geographical location and socio-economic status. Regional variations in lifestyle, occupational hazards, and cultural practices may also influence the etiology of EL. In a study conducted in the US, object-related injuries were reported to be the most common cause of EL overall and the most common cause among children.<sup>1</sup>



**Figure 5.** Preoperative and postoperative photos of patients. (A) Preoperative photo of a patient with periocular and full-thickness laceration with lower canalicular tear. (B) Postoperative photo of the same patient. (C) Preoperative photo of a patient with lower and upper canalicular tear with full-thickness laceration. (D) Postoperative photo of the same patient

	n	%
Conjunctival laceration	23	17
Open-globe injury	14	10.3
Corneal abrasion	10	7.4
Vitreous hemorrhage	9	6.6
Hyphema	6	4.4
Retinal detachment	5	3.7
Comotio retina	3	2.2
Lens subluxation	1	0.7

In a study from Iran, Tabatabaei et al.<sup>10</sup> reported that 62.5% of patients had blunt ocular trauma, while 37.5% had trauma with sharp objects. They reported that blunt moving objects, motor vehicle accidents, falls, and fighting were the other main causes of EL. In another study conducted in India, 59.9% of EL were caused by road accidents, followed by assault (13.6%), animal attacks (12.7%), and falls (9%).<sup>3</sup>

Considering the age disruption, common causes of EL in children and adolescents include falls, accidents during play, sports-related injuries, and animal bites.<sup>11,12</sup> In our study, trauma with sharp objects (73.6%) was the most common cause in children, followed by trauma with blunt objects and falls. In young adults and adults, EL are mostly due to occupational hazards, accidents, and trauma. Our study results showed that trauma with blunt objects (35.4%) and sharp objects (32.2%) occurred at similar proportions. In older adults, it especially occurs as a result of falls or accidental injuries associated with age-related changes like decreased vision, impaired balance, and frailty.<sup>13,14</sup> Cade et al.<sup>1</sup> reported that falls were the most common factor for older patients, accounting for 74% of cases. Consistent with the literature, patients 65 and over in our study were usually injured in falls (92.3%).

Considering EL types, the incidence of periocular, full-thickness, and lacrimal passage-involving EL represented 91%, 6.5%, and 2.6% of cases, respectively, in a study conducted in the US.<sup>1</sup> Zhao et al.<sup>15</sup> reported that out of 303 EL cases, 56% were periocular, followed by 24% with canalicular involvement and 20% crossing the eyelid margin. Similar to these results, our study showed that 50.3% of the patients had periocular, 27.4% had full-thickness, and 22.2% had full-thickness laceration involving the lacrimal passage.

Foreign bodies frequently accompany eyelid trauma, especially when due to mechanisms such as high-speed trauma, occupational hazards, or outdoor activities. Studies have reported foreign body prevalence rates ranging from 18% to 30%.<sup>16,17</sup> In our study, 11.1% of the patients had a foreign body in the trauma region.

EL are often accompanied by canalicular trauma, and the prevalence ranges from about 10% to 30%.<sup>7,9</sup> With a rate of 22.2%, our study results were compatible with the literature, and falls was the most common etiologic factor in these cases. Zhao et al.<sup>15</sup> reported that animal bite or scratch was the most common etiology of canalicular-involving lacerations (29%). In another study conducted in Türkiye, this rate was reported as 30.2% and the most common causes were traffic accidents, assault, and animal bites.<sup>8</sup> Similar to our study, Adıbelli and Cakmak<sup>18</sup> reported the incidence of lower canaliculus injury as 65.6%. In the literature, the anatomical success rate of canalicular laceration repair ranges between 75% and 100%, while the functional success rate is in the range of 58-96%.<sup>19,20</sup> Our study results were compatible with the literature, with rates of 96.6% and 86%, respectively. Qin et al.<sup>6</sup> reported that epiphora following canalicular trauma might be associated with the time elapsed from injury to repair, duration of stent placement, structural abnormalities in the medial canthus, and distance between the distal cut end and the lacrimal punctum.

The incidence of accompanying ocular injuries has been reported as 17-24% in various studies. Kumar and Batham<sup>3</sup> reported that the most common accompanying finding was subconjunctival hemorrhage, followed by hyphema, conjunctival laceration, traumatic lens injury, and corneal laceration. Tabatabaei et al.<sup>10</sup> reported that globe injury was present in 6.1%

of the cases. In a study conducted in our country, open-globe injuries accompanied 15.7% of cases.<sup>8</sup> However, Chaudhary et al.<sup>21</sup> reported globe perforation in about 50% of cases. In our study, the most common accompanying ocular findings were conjunctival laceration (17%), open-globe injury (10.3%), corneal abrasion (7.4%), vitreous hemorrhage (6.6%), and hyphema (4.4%). Patients with additional ocular findings were most frequently in the 19-64 age group, and traffic accidents and injuries with blunt objects were more common etiologic factors. Zhao et al.<sup>15</sup> reported that assaults were more likely to present with concomitant ophthalmic injuries. Schmidt et al.<sup>22</sup> reported that EL following blunt trauma such as falls or blows are frequently accompanied by corneoscleral perforations extending to the posterior pole. Therefore, they stated that the visual prognosis is worse in these cases.

Similar to our results, the most commonly reported late complication of EL is lid notching, which usually results from improper approximation or development of a wound gap.<sup>9</sup> Kumar and Batham<sup>3</sup> also reported lid notching (6.3%), hypertrophic scars (1.8%), ptosis (2.7%), tearing (2.7%), and lagophthalmos (0.9%) as other complications. Most complications can be prevented through careful and effective primary closure. Complications tend to arise when closure is delayed or when tissue approximation is poorly executed.

#### Study Limitations

The limitations of our study include the small sample size and the fact that it was conducted at a single center, which may limit the generalizability of the findings. Another reason for the small sample size was the exclusion of patients who were being treated in the intensive care unit for systemic reasons. Additionally, the study had a relatively short follow-up period, which limited our ability to observe long-term outcomes and complications.

#### Conclusion

Like other types of trauma, EL are more commonly observed in young adults and men. Considering this, it is crucial to provide preventive advice and implement safety measures in workplaces to reduce the incidence of preventable injuries. The most frequent mechanisms of injury involve trauma with sharp objects, while falling is the leading cause among older adults. Notably, EL involving the lacrimal passage are predominantly associated with falls. It is important to note that eyelid traumas are often accompanied by severe ocular pathologies such as conjunctival laceration, hyphema, corneal abrasion, and corneoscleral perforation. In particular, traffic accidents and injuries caused by blunt objects were the most commonly reported etiologic factors in patients presenting with these ocular pathologies.

Overall, a comprehensive understanding of EL, their etiologic factors, associated ocular injuries, and appropriate management strategies is crucial to achieving optimal outcomes and preserving both the functional and aesthetic aspects of the eyelids.

## Ethics

**Ethics Committee Approval:** Approval for this study was received from the Sakarya University Faculty of Medicine Ethics Committee (decision no: E-71522473-050.01.04-241666-111).

**Informed Consent:** Obtained.

## Authorship Contributions

Surgical and Medical Practices: E.D., Ş.B.C., G.A., Concept: E.D., B.G.S., Design: E.D., Data Collection or Processing: E.D., B.G.S., Ş.B.C., G.A., Analysis or Interpretation: E.D., B.G.S., Literature Search: E.D., B.G.S., Writing: E.D.

**Conflict of Interest:** No conflict of interest was declared by the authors.

**Financial Disclosure:** The authors declared that this study received no financial support.

## References

1. Cade KL, Taneja K, Jensen A, Rajaii F. Incidence, Characteristics, and Cost of Eyelid Lacerations in the United States from 2006 to 2014. *Ophthalmol Ther.* 2023;12:263-279.
2. Cillino S, Casuccio A, Di Pace F, Pillitteri F, Cillino G. A five-year retrospective study of the epidemiological characteristics and visual outcomes of patients hospitalized for ocular trauma in a Mediterranean area. *BMC Ophthalmol.* 2008;8:6.
3. Kumar J, Batham S. Clinical study of eyelid and periorbital injuries and their management. *Journal of Dental and Medical Sciences.* 2020;19:54-60.
4. Kennedy RH, May J, Dailey J, Flanagan JC. Canalicular laceration. An 11-year epidemiologic and clinical study. *Ophthalmic Plast Reconstr Surg.* 1990;6:46-53.
5. Chiang E, Bee C, Harris GJ, Wells TS. Does delayed repair of eyelid lacerations compromise outcome? *Am J Emerg Med.* 2017;35:1766-1767.
6. Qin YY, Li ZH, Lin FB, Jia Y, Mao J, Wang CY, Liang XW. Risk factors for persistent epiphora following successful canalicular laceration repair. *Int J Ophthalmol.* 2021;14:106-111.
7. Türkoğlu EB, Tök L, Yalçın Tök Ö, Dikci S, Akbaş Kocaoğlu F, Örnek F. Epidemiologic Evaluation of Ocular Trauma with, Eyelid Injuries. *MN Ophthalmol* 2014;21:56-62.
8. Herzum H, Holle P, Hintschich C. Lidverletzungen. *Epidemiologische Aspekte [Eyelid injuries: epidemiological aspects]. Ophthalmologie.* 2001;11:1079-1082.
9. Long JA, TannTM. Eyelid and lacrimal trauma. Kuhn F, Pieramici D. *Ocular Trauma: Principles and Practice.* New york: Thieme Medical Publishers; 2002:373-382.
10. Tabatabaei A, Kasaei A, Nikdel M, Shoar S, Esmaeili S, Mafi M, Moradi M, Mansouri M, Eshraghi B, Tabatabaei Z. Clinical characteristics and causality of eye lid laceration in iran. *Oman Med J.* 2013;28:97-101.
11. Koo L, Kapadia MK, Singh RP, Sheridan R, Hatton MP. Gender differences in etiology and outcome of open globe injuries. *J Trauma.* 2005;59:175-178.
12. Ashaye AO. Eye injuries in children and adolescents: a report of 205 cases. *J Natl Med Assoc.* 2009;101:51-56.
13. Chocron IM, Goduni L, Poulsen DM, Mbekeani JN. Patterns of ocular trauma in elderly patients in an urban population-the Bronx experience. *Arq Bras Oftalmol.* 2020;83:113-119.
14. Doğan E, Aksoy N, Çelik E, Alişan S, Çakır B, Özmen S. Characteristics of open-globe injuries in elderly patients. *Turkish Journal of Geriatrics.* 2019;22:418-425.
15. Zhao J, Awidi A, Li X, Ahmad M, Jensen A, Rajaii F, Mahoney N, Justin G, Woreta F. Epidemiology of eyelid lacerations presenting to a level I trauma center in the United States: 2018-2020. *Invest Ophthalmol Vis Sci.* 2022;63:2135-A0163.
16. Yiğit O, Yürüktümen A, Arslan S. Foreign body traumas of the eye managed in an emergency department of a single-institution. *Ulus Travma Acil Cerrahi Derg.* 2012;18:75-79.
17. Kivanç SA, Akova Budak B, Ulusoy MO, Atakan M. Unusual Foreign Bodies in Eyelids in Childhood. *Clin Exp Ocul Trauma Infect.* 2019;116-121.
18. Adibelli FM, Cakmak SS. The repair of canalicular lacerations with an annular silicone tube and round-tipped pigtail probe. *Asian J Ophthalmol.* 2020;17:188-195.
19. Murchison AP, Bilyk JR. Canalicular laceration repair: an analysis of variables affecting success. *Ophthalmic Plast Reconstr Surg.* 2014;30:410-414.
20. Naik MN, Kelapure A, Rath S, Honavar SG. Management of canalicular lacerations: epidemiological aspects and experience with Mini-Monoka monocanicular stent. *Am J Ophthalmol.* 2008;145:375-380.
21. Chaudhary A Singh SP, Agasti M, Singh BK. Eyelid trauma and their management. *International Journal of Ocular Oncology and Oculoplasty.* 2016;2:240-243.
22. Schmidt GW, Broman AT, Hindman HB, Grant MP. Vision survival after open globe injury predicted by classification and regression tree analysis. *Ophthalmology.* 2008;115:202-209.