



# Surgical Treatment of a Patient with Recurrent Bleb Leak and Glaucoma: Bleb Excision Combined with Gonioscopy-Assisted Transluminal Trabeculotomy

© Ceyda Erişti Bölük\*, © Zeynep Aktaş\*\*

\*Gazi University Faculty of Medicine, Department of Ophthalmology, Ankara, Turkey

\*\*Atılım University Faculty of Medicine, Department of Ophthalmology, Ankara, Turkey

## Abstract

Here we present a case of intermittent bleb leakage with increased intraocular pressure (IOP) during recovery periods that was treated with gonioscopy-assisted transluminal trabeculotomy (GATT) combined with avascular bleb excision. A 60-year-old woman exhibiting simultaneous leaking bleb and glaucoma underwent GATT and bleb revision. At her final visit, the bleb leakage had resolved and IOP was under control without any further antiglaucoma medication. GATT may be useful for glaucoma patients exhibiting intermittent bleb leakage after failed trabeculectomy.

**Keywords:** Glaucoma, trabeculectomy, gonioscopy-assisted transluminal trabeculotomy, bleb leakage

## Introduction

Trabeculectomy is still one of the most common surgeries performed for the surgical treatment of glaucoma, allowing aqueous humor to flow out from the anterior chamber into the subconjunctival space. However, it has many sight-threatening complications such as hypotonia, choroidal effusion, bleb leakage, and endophthalmitis.<sup>1</sup> Bleb leakage occurs commonly in the early and rarely in the late postoperative period and requires urgent treatment to avoid progression to serious complications such as bleb infection and endophthalmitis. However, intraocular pressure (IOP) can increase significantly despite appropriate medical and surgical treatment, and therefore further glaucoma surgery is needed in many cases.<sup>2</sup>

In the last decade, gonioscopy-assisted transluminal trabeculotomy (GATT) surgery, introduced by Grover et al.,<sup>3</sup> has become popular because it spares the conjunctiva and sclera. Therefore, bleb-related complications are eliminated in this approach.<sup>4</sup> It enables circumferential bypass of the dysfunctional trabecular meshwork. It has been reported to have successful outcomes in primary congenital glaucoma patients and adult-onset open-angle glaucoma.<sup>3,5</sup> Moreover, Grover et al.<sup>6</sup> demonstrated that GATT was also effective in treating patients with failed filtering glaucoma surgery.

Herein, we aimed to present a patient who underwent GATT combined with bleb excision for the treatment of failed trabeculectomy with a thin avascular bleb frequently presenting intermittent bleb leakage.

**Address for Correspondence:** Ceyda Erişti Bölük, Gazi University Faculty of Medicine, Department of Ophthalmology, Ankara, Turkey

E-mail: ceydaeristi@gmail.com **ORCID-ID:** orcid.org/0000-0003-3218-365X

**Received:** 23.01.2022 **Accepted:** 28.06.2022

**Cite this article as:** Erişti Bölük C, Aktaş Z. Surgical Treatment of a Patient with Recurrent Bleb Leak and Glaucoma: Bleb Excision Combined with Gonioscopy-Assisted Transluminal Trabeculotomy. Turk J Ophthalmol 2022;52:352-355

©Copyright 2022 by Turkish Ophthalmological Association  
Turkish Journal of Ophthalmology, published by Galenos Publishing House.

## Case Reports

A 60-year-old woman with bilateral pseudoexfoliation glaucoma, who underwent two trabeculectomy procedures with mitomycin C in both eyes 10 years ago, was referred to our clinic for the surgical treatment of recurrent bleb leakage in her right eye. Best-corrected visual acuities (BCVA) in her right and left eyes were 20/30 and 20/25, respectively. IOP measured by Goldman applanation tonometry was 7 and 20 mmHg in her right and left eyes, respectively. Slit-lamp examination revealed a thin-walled avascular bleb with leakage, which was confirmed by positive Seidel test, at the superior limbus in the right eye (Figure 1). The conjunctiva around the leaking bleb was scarred in the superior quadrant after two trabeculectomies. Topical moxifloxacin was given four times a day and a large-diameter bandage contact lens (BCL) was placed on the right eye. Although the patient responded well to this treatment in the early period, a second bleb leak occurred in the fourth month of follow-up. A large-diameter BCL was placed on the right eye again and bleb excision was planned, but the patient refused further intervention at the time, preferring to be followed with the BCL. Shortly after this visit, she presented again with pain and an unmedicated IOP of 46 mmHg, this time with no leak. Treatment with brinzolamide, timolol maleate, and bimatoprost was initiated. When the patient was able to return for follow-up 2 months later, the IOP in her right eye was measured as 27 mmHg despite maximally tolerated medical therapy and no bleb leak. The conjunctiva was scarred around the large avascular bleb. On gonioscopy, the angle was fully open, the trabecular meshwork was visible in nearly 360 degrees, and there was no peripheral anterior synechia.

Because the patient had recurrent bleb leakage and IOP spikes when there was no leak, a combined bleb revision and GATT procedure was planned.

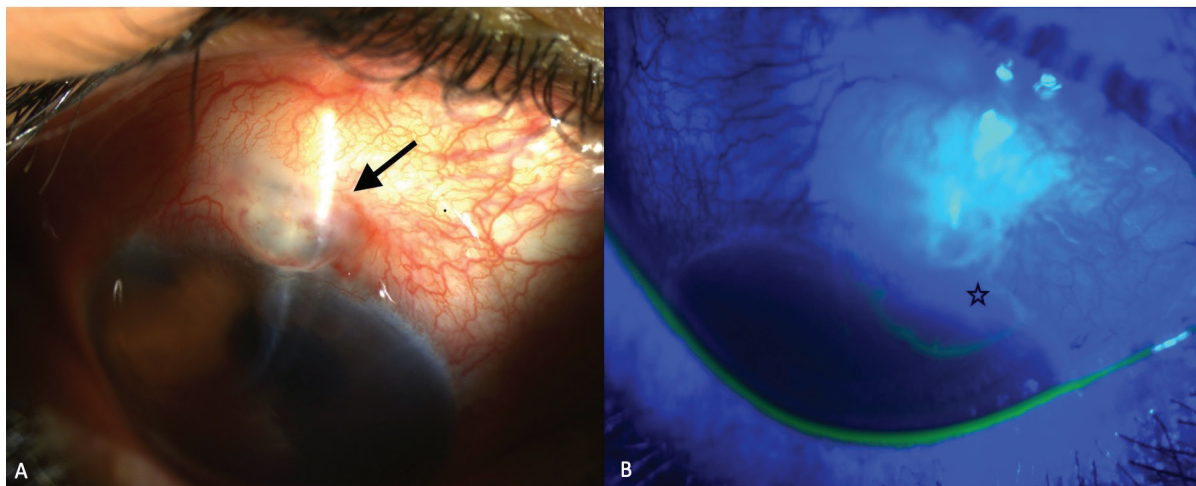
GATT surgery was performed prior to bleb excision to avoid possible obscuring of the gonio-surgical view due to bleeding from the conjunctival surgery above. The tip of a 6-0 Prolene

(polypropylene) needled suture was blunted using a hand-held cautery. After a 1-2 mm goniotomy was performed nasally, the suture was advanced into Schlemm's canal inferiorly. It stopped at the iridectomy area and entered the anterior chamber. The distal tip was grasped with micro-vitreoretinal forceps. Then, approximately 270-degree ab interno trabeculotomy was done. In the second half of the surgery, the avascular bleb and melted scleral flap were both dissected, a dura mater graft was tightly sutured to the sclerotomy area with 10-0 nylon sutures, and the conjunctiva was then closed. Moxifloxacin and dexamethasone eye drops were administered four times a day for two weeks. On the first postoperative day, slit-lamp examination revealed shallow bleb formation and hyphema filling approximately 20% of the anterior chamber, and IOP was 9 mmHg (Figure 2). At postoperative 10 months, no bleb was observed, IOP was 14 mmHg without any IOP-lowering medication, and BCVA was 20/30.

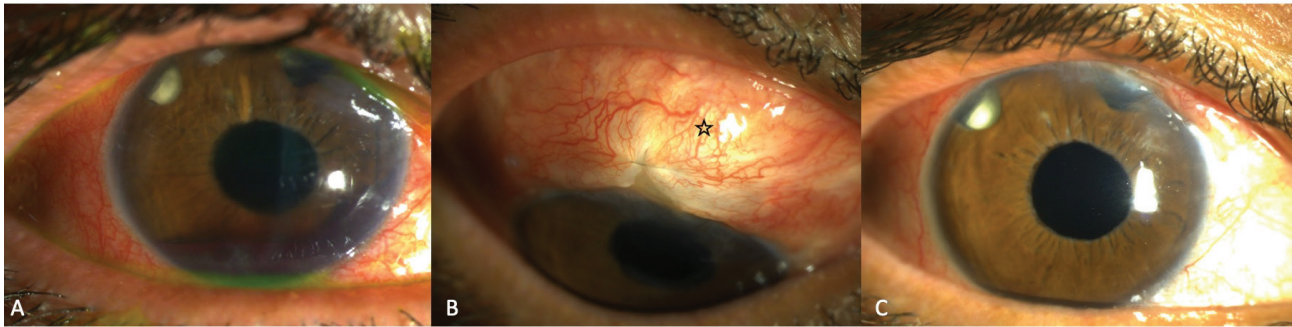
## Discussion

Although trabeculectomy is known as the most effective surgical procedure for the treatment of glaucoma patients, the use of antimetabolites such as 5-fluorouracil (5-FU) and mitomycin C in this surgery has markedly increased the incidence of postoperative bleb leaks.<sup>7</sup> Bleb leaks can cause severe sight-threatening complications including blebitis and even endophthalmitis if not treated.<sup>8</sup> Therefore, once bleb leakage is detected, appropriate treatments should be initiated immediately, even if patient is asymptomatic.<sup>2</sup>

The treatment algorithm for bleb leaks consists of non-surgical and surgical procedures. Non-surgical procedures, considered the first-line treatment, include aqueous suppressant drugs and large-diameter BCLs.<sup>2,9</sup> Generally, incisional methods are used in cases where non-surgical interventions are ineffective or leakage cannot be eliminated completely. Surgical procedures include conjunctival advancement or transplantation, scleral or corneal patch, amniotic membrane transplantation, and



**Figure 1.** Bleb leaks 10 years after trabeculectomy. Slit-lamp visualization of the right eye shows an avascular bleb (black arrow) (A), conjunctival defect, and bleb leaks demonstrated by Seidel test (black star) (B)



**Figure 2.** Slit-lamp photos after GATT and bleb repair surgery show hyphema filling ~20% (A), conjunctival closure overlying a repaired scleral area (black star) (B), and clear cornea with normal IOP at 2-month follow-up (C)

GATT: Gonioscopy-assisted transluminal trabeculotomy

material or pericardium/dura patch applications to the leaking area.<sup>1</sup> However, patients who undergo one of these methods require close follow-up because of the high possibility of leakage recurrence and subsequent IOP elevation.<sup>9</sup> As a result, bleb leaks are sometimes difficult to manage. Furthermore, resuming anti-glaucoma drug therapy is necessary to control IOP in most cases. In such patients with failed trabeculectomy, further glaucoma surgery should be considered if the target IOP cannot be achieved with medication.<sup>10</sup>

As most minimally invasive glaucoma surgery (MIGS) procedures are blebless, they eliminate bleb-related complications. Common favorable features of MIGSs include an ab interno approach, minimal trauma to scleral and conjunctival tissues, high safety and efficacy profiles, and rapid wound healing.<sup>11</sup>

GATT surgery, which is one of these techniques, can be applied successfully in open-angle glaucoma patients with failed tube implant or trabeculectomy. Grover et al.<sup>6</sup> demonstrated that it was possible to increase aqueous outflow by bypassing the trabecular meshwork in eyes unresponsive to previous filtration and drainage implant surgery. Cubuk et al.<sup>12</sup> also reported that the GATT procedure is an effective option for patients with pseudoexfoliative glaucoma who have a history of failed trabeculectomy.

In this case, the patient had a necrotic, nonfunctional, and recurrently leaky bleb. When the leak healed, there were recurrent IOP spikes. Thus, combined bleb excision and glaucoma surgery was planned. Tube surgery was avoided in the current case because we planned simultaneous bleb excision in the superior quadrant. Furthermore, GATT surgery was a better option than tube implant surgery in this case because the whole area around the avascular bleb was scarred from the two previous trabeculectomy surgeries, which may have made tube surgery technically challenging in this case. The bleb area might not be aggressively closed, but since there was no roof to maintain, we preferred to excise it totally and sutured a patch over it. On the other hand, the angle was fully open and the trabecular meshwork was visible in the rest of the angle. Therefore, GATT

surgery to control IOP was performed together with bleb excision in the same surgical session.

In conclusion, instead of tube surgery, the GATT procedure might enable simultaneous conjunctival surgical procedures to be performed in complicated cases while treating IOP spikes secondary to failed trabeculectomies in the same eye.

#### Ethics

**Informed Consent:** Obtained.

**Peer-review:** Externally peer-reviewed.

#### Authorship Contributions

Surgical and Medical Practices: Z.A., C.E.B., Concept: Z.A., Design: Z.A., Data Collection or Processing: C.E.B., Analysis or Interpretation: C.E.B., Literature Search: C.E.B., Writing: C.E.B.

**Conflict of Interest:** No conflict of interest was declared by the authors.

**Financial Disclosure:** The authors declared that this study received no financial support.

#### References

1. Feldman RM, Altaher G. Management of late-onset bleb leaks: *Curr Opin Ophthalmol.* 2004;15:151-154.
2. Bochmann F, Azuara-Blanco A. Interventions for late trabeculectomy bleb leak: *Cochrane Database Syst Rev.* 2012;CD006769.
3. Grover DS, Godfrey DG, Smith O, Feuer WJ, Montes de Oca I, Fellman RL. Gonioscopy-assisted transluminal trabeculotomy, ab interno trabeculotomy: technique report and preliminary results. *Ophthalmology.* 2014;121:855-861.
4. Aktas Z, Ucgul AY, Bektas C, Sahin Karamert S. Surgical outcomes of prolene gonioscopy-assisted transluminal trabeculotomy in patients with moderate to advanced open-angle glaucoma: *J Glaucoma.* 2019;28:884-888.
5. Grover DS, Smith O, Fellman RL, Godfrey DG, Butler MR, de Oca IM, Feuer WJ. Gonioscopy assisted transluminal trabeculotomy: an ab interno circumferential trabeculotomy for the treatment of primary congenital glaucoma and juvenile open angle glaucoma: *Br J Ophthalmol.* 2015;99:1092-1096.
6. Grover DS, Godfrey DG, Smith O, Shi W, Feuer WJ, Fellman RL. Outcomes of Gonioscopy-assisted Transluminal Trabeculotomy (GATT) in Eye With Prior Incisional Glaucoma Surgery: *J Glaucoma.* 2017;26:41-45.

7. Gedde SJ, Schiffman JC, Feuer WJ, Herndon LW, Brandt JD, Budenz DL, Tube versus Trabeculectomy Study Group. Treatment outcomes in the tube versus trabeculectomy (TVT) study after five years of follow-up. *Am J Ophthalmol.* 2012;153:789-803.
8. Edmunds B, Thompson JR, Salmon JF, Wormald RP. The National Survey of Trabeculectomy. III. Early and Late Complications. *Eye (Lond).* 2002;16:297-303.
9. Neeru Gupta. Incision-Free Minimally Invasive Conjunctival Surgery (MICS) for Late-Onset Bleb Leaks After Trabeculectomy (An American Ophthalmological Society Thesis). *Am J Ophthalmol.* 2019;207:333-342.
10. Senthil S, Basia A, Rao HL, Choudhari N, Dikshit S, Mandal AK, Garudadri CS. Outcomes of Bleb Repair for Delayed Bleb Leaks and Sweating Blebs. *J Glaucoma.* 2018;27:33-40.
11. Ahmed IK, Saheb H. Microinvasive glaucoma surgery: current perspectives and future directions. *Curr Opin Ophthalmol.* 2012;23:96-104.
12. Cubuk MO, Ucgul AY, Unsal E. Gonioscopy-assisted Transluminal Trabeculotomy as an Option After Failed Trabeculectomy. *Int Ophthalmol.* 2020;40:1923-1930.