



# Sheath-Preserving Complete Optic Nerve Avulsion Following Closed-Globe Injury: A Case Report

© Seray Şahin, © Onur Furundaoturan, © Mine Esen Barış, © Elif Demirkılınc Biler

Ege University Faculty of Medicine, Department of Ophthalmology, İzmir, Turkey

## Abstract

A 29-year-old man presented with a sudden loss of vision after a closed-globe injury. At presentation, he had no light perception in the right eye and the right pupil was dilated and nonreactive to light. On ophthalmological examination, the area of the optic nerve head was excavated, suggesting optic nerve avulsion. Magnetic resonance imaging scan showed optic nerve avulsion without rupture of the optic nerve sheath. Four months after the injury, the patient's visual acuity remained unchanged. Gliosis developed at the avulsion site. Closed-globe injuries may cause severe posterior injury even if there is no anterior damage in the eye. To prevent unnecessary treatment, trauma patients should be examined carefully appropriate imaging to confirm the diagnosis.

**Keywords:** Traumatic optic nerve avulsion, closed globe injuries, complete optic nerve avulsion, optic nerve sheath

## Introduction

Optic nerve avulsion is the forced disinsertion of the optic nerve from the retina, choroid and vitreous, characterized by retraction of the lamina cribrosa from the scleral rim while the optic nerve sheath is preserved.<sup>1</sup> It is a rare and severe complication of ocular blunt trauma. Optic nerve damage may be complete or partial. In complete avulsion, the damage usually occurs in the optic canal or orbit; the intracranial part of the nerve is rarely involved because of its mobility.<sup>2</sup> Previously published reports and observations of traumatic optic nerve avulsion suggested that a sudden rise in the intraocular pressure, sudden rotation of the globe, anterior luxation, and other factors might be responsible for this unique complication.<sup>1,2,3,4</sup> In this

case report, we describe a young man with complete optic nerve avulsion and intact sheath caused by compressed air hose injury.

## Case Presentation

A 29-year-old man was referred to the emergency department with periorbital edema, pain, and sudden loss of vision in the right eye following blunt trauma with a compressed air hose. In ophthalmological examination, visual acuity in the right eye was no light perception. The right pupil was dilated and nonreactive to light. Proptosis, chemosis, conjunctival laceration, and subconjunctival air bubbles were observed on anterior segment examination of the right eye. The cornea and lens were clear. Posterior segment examination revealed the presence of retinal

**Address for Correspondence:** Mine Esen Barış, Ege University Faculty of Medicine, Department of Ophthalmology, İzmir, Turkey

E-mail: mine.baris@yahoo.com **ORCID-ID:** orcid.org/0000-0003-1341-6737

**Received:** 16.08.2021 **Accepted:** 17.02.2022

**Cite this article as:** Şahin S, Furundaoturan O, Barış ME, Demirkılınc Biler E. Sheath-Preserving Complete Optic Nerve Avulsion Following Closed-Globe Injury: A Case Report. Turk J Ophthalmol 2022;52:216-219

©Copyright 2022 by Turkish Ophthalmological Association  
Turkish Journal of Ophthalmology, published by Galenos Publishing House.

ischemia affecting all quadrants of the fundus with vitreous hemorrhage located inferiorly and preretinal hemorrhages. The area of the optic nerve head was excavated, suggesting optic nerve avulsion, and filled with hemorrhage, with blood emanating into the vitreous and a ring of peripapillary hemorrhage (Figure 1).

Intraocular pressures (IOP) were 12 mmHg in the right eye and 18 mmHg in the left eye. Visual acuity of the left eye was 20/20 without correction and the light reflex of the left pupil was normal. Anterior and posterior segment examinations of the left eye were also normal.

Normal IOP of the right eye suggested that the sclera was intact, but due to excessive chemosis and subconjunctival hemorrhage, urgent explorative surgery was planned in order to search for a rupture site. Otorhinolaryngology and neurosurgery consultations were requested. Neurosurgery recommended a 24-hour follow-up cranial computed tomography (CT) scan for pneumocephalus. The explorative surgery was canceled due to suspected cerebrospinal fluid fistula.

On CT, fractures were observed in the medial wall of the right orbit and ethmoidal cell walls. Magnetic resonance imaging (MRI) and CT scan showed optic nerve avulsion without rupture of the optic nerve sheath and posttraumatic pneumocephalus (Figures 2 and 3).

Flash visual evoked potentials (VEP) revealed delayed latency and decreased P wave amplitude in the right eye.

Four months after injury, the patient's visual acuity remained unchanged. Gliosis developed at the avulsion site (Figure 4)

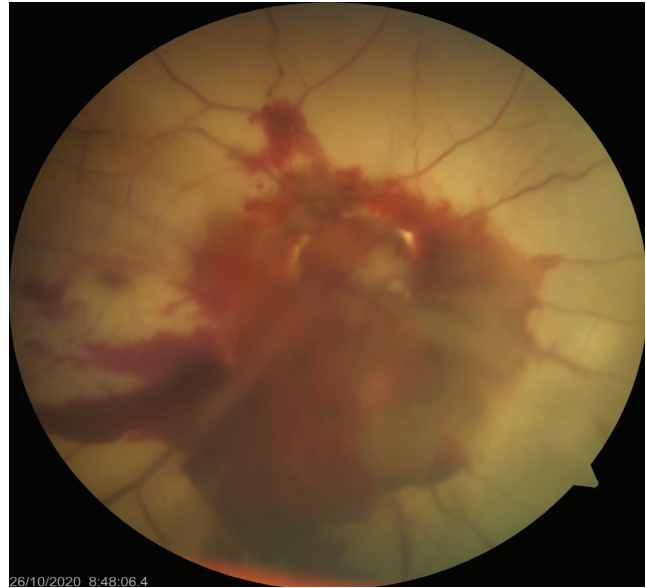## Discussion

In cases of high-velocity injuries to the periorbital structures, the impact of blunt trauma plays a vital role in the displacement of tissues within the orbit. During blunt trauma to the orbital margin, Bell's phenomenon occurs as a natural protective mechanism. This induces certain changes in the anatomical orientation of the globe with respect to the horizontal, vertical, and anteroposterior axes.<sup>5</sup> The loss of myelin and absence of supportive connective tissue septae make the axons at the lamina cribrosa particularly vulnerable.<sup>6</sup>

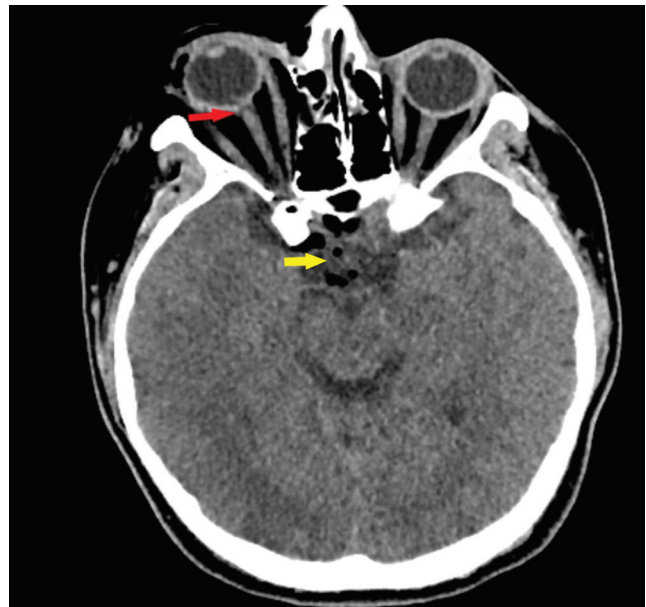
There are several mechanisms reported to be responsible for this rare entity. Pujari et al.<sup>5</sup> reported that anterior globe luxation is more important in the pathomechanism of traumatic optic nerve avulsion, whereas a sudden rise in IOP leading to posterior rupture of the optic nerve appears to be of lesser significance since most cases of ocular blunt trauma are not accompanied by optic nerve avulsion. In our case, we suspect that the whiplash motion of the hose combined with its high velocity might have caused a sudden rotation and perhaps anterior displacement of the globe, resulting in optic nerve avulsion. Optic nerve avulsion is defined as a traumatic disinsertion of the nerve fibers at the disc margin.<sup>4</sup> Although preservation of the optic nerve sheath has rarely been reported in cases in the literature, MRI demonstrated an intact optic nerve sheath in this case.

Optic nerve avulsion mainly presents as a dense hemorrhagic

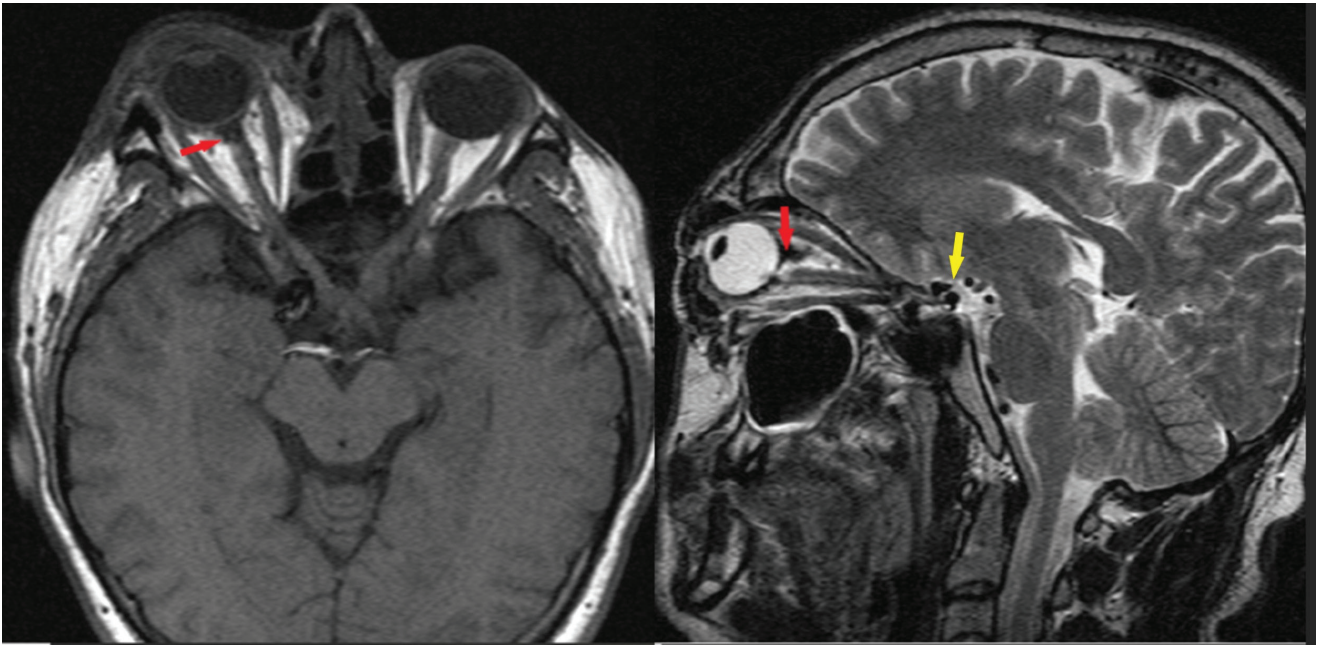
manifestation along the optic nerve head with or without other vascular complications.<sup>5</sup> Retinal ischemia is also observed because of associated central retinal arterial injury. In the literature, avulsion of the optic nerve occurred mostly at the junction of the nerve and globe, but there are cases reported with different avulsion sites. Tamase et al.<sup>7</sup> reported a case in which the optic nerve was split distal to the optic chiasm and temporal hemianopsia developed in the contralateral eye. In our case, the avulsion site was similar to the literature and the fellow eye was



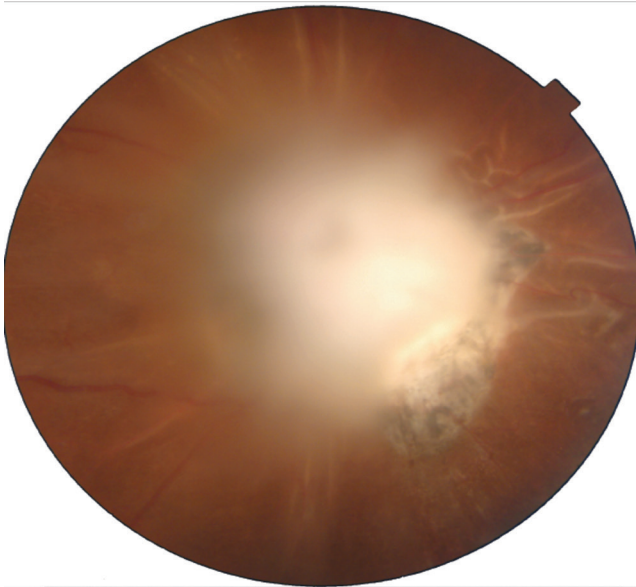
**Figure 1.** Image of total optic nerve avulsion showing an empty optic disc, vitreous hemorrhage, and ischemic retina



**Figure 2.** Initial computed tomography scan showing optic nerve avulsion (red arrow) without rupture of the optic nerve sheath and posttraumatic pneumocephalus (yellow arrow)



**Figure 3.** T1-weighted axial MRI and T2-weighted sagittal MRI showing the site of optic nerve avulsion (red arrows) and pneumocephalus (yellow arrow)  
MRI: Magnetic resonance imaging



**Figure 4.** Gliosis developed months after the incident

not affected.

Optic nerve avulsion has been reported after injuries with various causes, such as iron bars, bear attack, or falling from a tree.<sup>7,8,9</sup> Complete optic nerve avulsion occurred in all of these cases, but the optic nerve sheath was not intact. Mumcuoglu et al.<sup>10</sup> reported a case of partial optic nerve avulsion with

preservation of the sheath.

In the present case, the injury was a result of blunt trauma caused by a compressed air hose. Complete avulsion of the optic nerve rarely occurs with preservation of the optic nerve sheath, as in our case.

Blunt orbital trauma may cause severe posterior injury even if there is no anterior damage in the eye.

Sawhney et al.<sup>1</sup> reported optic disc excavation in traumatic avulsion cases, but the diagnosis can be hidden because of vitreous hemorrhage. It is essential to confirm the diagnosis so that the patient is not subjected to unnecessary treatment such as optic nerve decompression or high-dose steroids.

Patients can be monitored for complications including phthisis bulbi and secondary neovascularization or rubeotic glaucoma.<sup>11</sup>

Lastly, this case once again demonstrates the importance of using safety goggles.

#### Ethics

**Informed Consent:** Obtained.

**Peer-review:** Externally peer reviewed.

#### Authorship Contributions

Concept: S.Ş., O.F., M.E.B., Design: S.Ş., O.F., M.E.B., E.D.B., Data Collection or Processing: S.Ş., M.E.B., Analysis or Interpretation: S.Ş., O.F., M.E.B., E.D.B., Literature Search: S.Ş., O.F., M.E.B., Writing: S.Ş., M.E.B.

**Conflict of Interest:** No conflict of interest was declared by

the authors.

**Financial Disclosure:** The authors declared that this study received no financial support.

## References

1. Sawhney R, Kochhar S, Gupta R, Jain R, Sood S. Traumatic optic nerve avulsion: role of ultrasonography. *Eye (Lond)*. 2003;17:667-670.
2. Mackiewicz J, Tomaszewska J, Jasielska M. Optic nerve avulsion after blunt ocular trauma - Case report. *Ann Agric Environ Med*. 2016;23:382-383.
3. Lohmrer I, Hada M, Agarwal V, Khilnani K. Optic nerve avulsion associated with central retinal artery occlusion following rotational globe injury. *Indian J Ophthalmol*. 2018;66:1040-1041.
4. Foster BS, March GA, Lucarelli MJ, Samiy N, Lessell S. Optic nerve avulsion. *Arch Ophthalmol*. 1997;115:623-630.
5. Pujari A, Saxena R, Phuljhele S, Bhaskaran K, Basheer S, Sharma P. Pathomechanism of optic nerve avulsion. *Med Hypotheses*. 2019;125:28-30.
6. Anand S, Harvey R, Sandramouli S. Accidental self-inflicted optic nerve head avulsion. *Eye (Lond)*. 2003;17:646-647.
7. Tamase A, Tachibana O, Iizuka H. Usefulness of MRI Slices Parallel to the Optic Chiasma in a Case with Traumatic Optic Nerve Avulsion after a Bear Attack. *Neurol Med Chir (Tokyo)*. 2019;59:357-359.
8. Değirmenci MFK, Yalçındağ N, Atilla H. Optic Nerve Avulsion and Retinal Detachment After Penetrating Ocular Trauma: Case Report. *Turk J Ophthalmol*. 2018;48:89-91.
9. Liu Y, Wang J, Zhu D. Avulsion of Optic Nerve and Peripapillary Retina. *Retina*. 2020;40:e22-e23.
10. Mumcuoglu T, Durukan HA, Erdurman C, Hurmeric V, Gundogan FC. Functional and structural analysis of partial optic nerve avulsion due to blunt trauma: case report. *Indian J Ophthalmol*. 2010;58:524-526.
11. Davidson A, Jackson D, Painter S, Parmar B. Traumatic optic nerve head avulsion. *BMJ*. 2017;359:j4881.