

Ocular Motility Improvement in Crouzon Syndrome after Neurosurgical Intervention Without Strabismic Operation

Crouzon Sendromunda Strabismus Cerrahisi Olmaksızın Nöroşirurjik Müdahale Sonrası Göz Hareketlerinde Düzeltme

Betül Tuğcu, Özgür Örum, Şule Ziyhan*, Hamiyet Çamuşcu**, Elif Hocaoğlu***, Ulviye Yiğit

Bakırköy Dr. Sadi Konuk Research And Education Hospital, Eye Clinic, Istanbul, Turkey

**Yeditepe University Medical Faculty, Istanbul, Turkey*

***Bakırköy Dr. Sadi Konuk Research and Education Hospital, Neurosurgery Clinic, Istanbul, Turkey*

****Bakırköy Dr. Sadi Konuk Research and Education Hospital, Radiology Clinic, Istanbul, Turkey*

Summary

We report a case of craniosynostosis showing spontaneous improvement in presumed superior oblique palsy and V-pattern exotropia in long-term follow-up. A 3-year-old girl who presented with head-face anomaly, V-pattern exotropia and abnormal head posture was admitted to our clinic. The diagnosis of Crouzon syndrome was established, and bilateral coronal suture excision and decompression were made by neurosurgeons. After the cranial operation, the patient was followed up for 6 years without further cranial or strabismic operation. At the end of this period, we observed that corrected visual acuity was 20/20 in both eyes and her ocular deviation disappeared in all gaze positions. Strabismus in craniosynostosis may be related to anatomical malposition of the rectus muscles. Spontaneous improvement in ocular deviation may occur, therefore, this possibility must be considered in the planning of surgical intervention. (*Turk J Ophthalmol* 2012; 42: 306-9)

Key Words: Craniosynostosis, Crouzon Syndrome, V-pattern exotropia, magnetic resonance imaging

Özet

Uzun dönem izlemde spontan düzeltme gösteren muhtemel oblik kas felci ve V patern ekzotropiyası olan kraniosinostozlu bir olguyu rapor ettik. Kafa yüz anomalisi, V patern ekzotropiya ve anormal baş pozisyonu olan 3 yaşında kız hasta kliniğimize başvurdu. Crouzon Sendromu tanısı ile beyin cerrahisi tarafında bilateral koronal sütür eksiyonu ve dekompresyon cerrahisi yapıldı. Kranial operasyon sonrasında hasta 6 yıl süre ile başka kranial veya şaşılık operasyonu geçirmeden izlendi. Bu periyodun sonunda düzeltilmiş görme keskinliğinin her iki gözde 20/20 olduğu ve tüm bakış pozisyonlarında kaymanın kaybolduğu görüldü. Kraniosinostozda şaşılık rektus kaslarının anormal anatomik pozisyonu ile ilişkili olabilir. Oküler kaymada spontan düzeltme gerçekleşebilir, bu yüzden cerrahi müdahale planlanırken bu ihtimal göz önünde bulundurulmalıdır. (*Turk J Ophthalmol* 2012; 42: 306-9)

Anahtar Kelimeler: Kraniosinostoz, Crouzon Sendromu, V patern ekzotropiya, MR görüntüleme

Introduction

Craniosynostosis is premature fusion of one or more cranial sutures, often resulting in an abnormal head shape. The severity and type of deformity depends on which sutures close in the development process. The cause of this premature fusion is unknown.¹ It is usually sporadic, but can be syndromic or familial. Birth prevalence is 3-14,1 per 10.000 live births.^{2,3} Children with craniosynostosis may have only cranial deformity or various type of problems such as mental retardation, limb defects, ear

abnormalities, cardiovascular malformations or ocular involvement. Different types of ocular pathologies have been described, changing from strabismus, amblyopia, optic nerve complications to proptosis in craniosynostosis.^{4,5}

Craniofacial surgery is typically the recommended treatment for craniosynostosis syndromes. The goal of treatment is to reduce the pressure in the head and correct the deformities of the face and skull bones.⁶ The optimal time to perform surgery is before the child is 1 year of age since the bones are still very soft and easy to work with. Surgery may be necessary at a much earlier age depending upon the severity of the condition.^{7,8}

Address for Correspondence/Yazışma Adresi: Dr. Betül Tuğcu, Dokuz Eylül University, School of Medicine, Ophthalmology Department, Izmir, Turkey
Gsm: +90 532 446 06 81 E-mail: betultugcu@yahoo.com

Received/Geliş Tarihi: 20.06.2011 **Accepted/Kabul Tarihi:** 02.11.2011

After the initial craniofacial repair, usually at 3 to 4 months of age, strabismus surgery may be contemplated when the ophthalmologist believes that the usual clinical indications are met: reversal of amblyopia after patching or penalization,

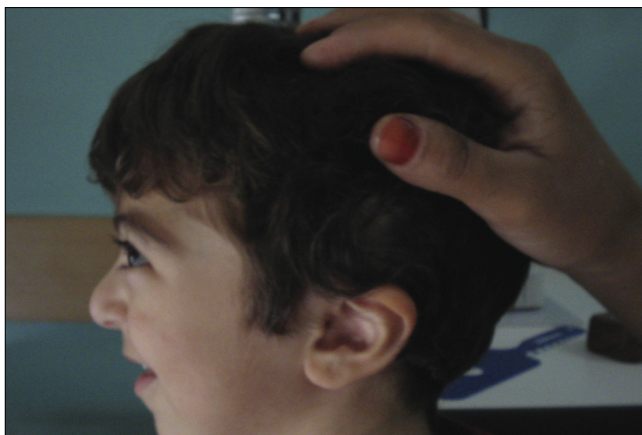

Figure 1. Head-face-ear anomaly of patient

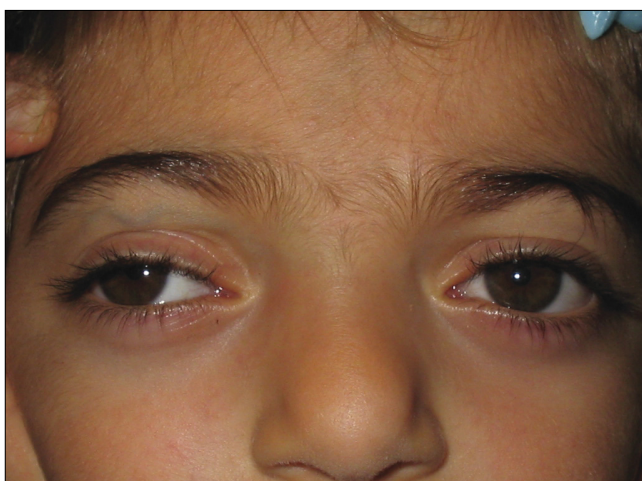

Figure 2. Primer gaze position of patient

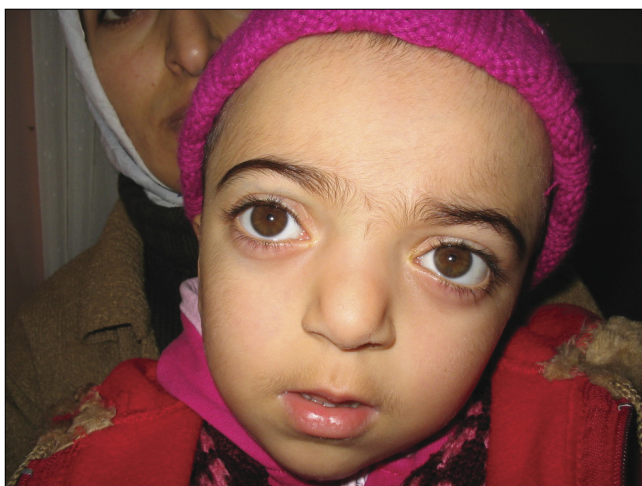

Figure 3. Abnormal head posture of patient

appropriate optical correction and reliable cover tests or light reflex measurements.⁹ Nowadays, most modern strabismologist prefer to operate earlier for obtaining the best opportunity for fusion.¹⁰ Experience has shown that orbital repositioning rarely results in postoperative shift of the strabismus deviation.^{11,12,13} Strabismus in craniofacial dysostosis is complex and difficult to cure with surgery. Coats et al. reported that none of the surgical procedures produced excellent postoperative alignment in these patients.¹⁴

We report herein a case of craniosynostosis showing spontaneous improvement in presumed superior oblique palsy and V-pattern exotropia in long-term follow-up. We got informed consent from the patient's parent.

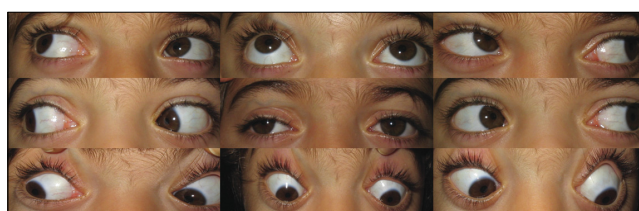

Figure 4. Nine diagnostic positions of gaze

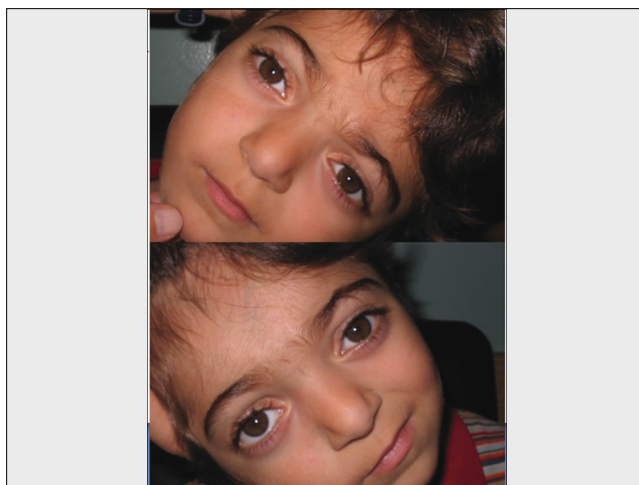


Figure 5. Bielschowsky head tilt test

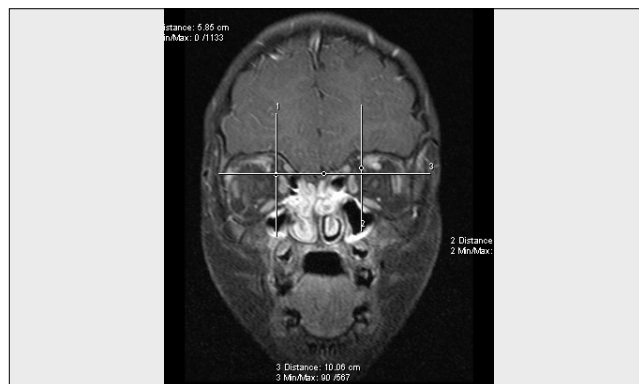


Figure 6. Inferior displacement of right lateral rectus muscle relative to other horizontal muscles

Case Report

A 3-year-old girl presented with head-face anomaly, V-pattern exotropia and abnormal head posture showing right eye hypertropia with left head tilt (Figure 1,2,3). Abnormal head posture to the left shoulder had been noted by her parents when she was 1-year-old. There was no trauma, convulsion and disease history in her anamnesis.

The ocular motility examination showed grade 2 overaction of the right inferior oblique muscle and underaction of the superior oblique muscle on the same side without any limitation of ocular motility in both eyes (Figure 4). The Bielschowsky head tilt test was positive on tilting of the head towards the right shoulder (Figure 5). The Krimsky test demonstrated V-pattern exotropia

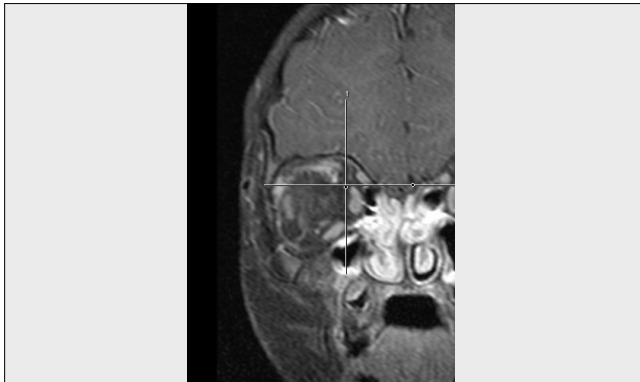


Figure 7. Nasal displacement of right inferior rectus muscle relative to the right superior rectus muscle

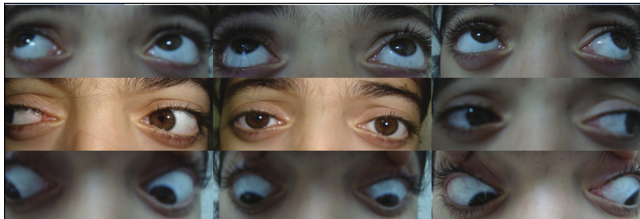

Figure 8. Nine diagnostic positions of gaze

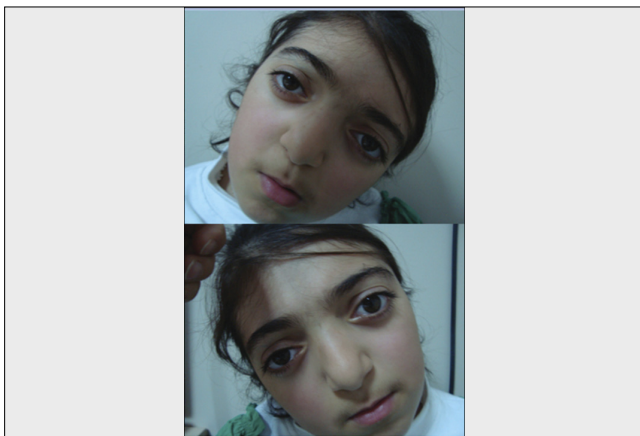


Figure 9. Bielschowsky head tilt test

which was more than 15 PD deviation difference between the upgaze and downgaze positions with 10 PD hypertropia of the right eye with the prism cover test. Bilateral optic disc edema was seen in both eyes.

Premature closure of the coronal sutures was showed by x-ray examination. No anomaly on orbital walls was demonstrated with three-dimensional computerized tomography. Orbital magnetic resonance imaging (MRI) showed bilateral hypoplasia of maxilla, grade 2 proptosis and hypertelorism in which interpupillary distance was 6 cm. Extraocular muscle morphology was evaluated in physiologic range. 2 mm nasal displacement of the right inferior rectus relative to the right superior rectus, and 3mm inferior displacement of the right lateral rectus relative to the right medial rectus were detected with MRI (Figure 6,7).

Pediatric neurologist and neurosurgeon were consulted with suspicion of craniosynostosis. The diagnosis of Crouzon syndrome was confirmed and bilateral coronal suture excision and decompression were made by neurosurgeons. After the cranial operation, the patient was followed up for 6 years without further cranial or strabismic operation. At the end of this period, we observed that corrected visual acuity was 20/20 in both eyes, her ocular deviation disappeared in all gaze positions and Bielschowsky head tilt test (Figure 8,9). Her fixation was foveolar and stereoacuity was 100 seconds of arc with Randot stereotest. In fundoscopic examination, papilledema disappeared but optic discs had crowded appearance. In recent orbital MRI, no asymmetry in extraocular muscle paths was detected (Figure 10).

Discussion

Strabismus is a common condition in 60-70% of patients with craniofacial dysostosis.¹⁴ Deviations are often incomitant. V-pattern strabismus is more common in both esodeviations and exodeviations - the reported range is from 59% to 100%¹⁵ Affected patients typically demonstrate moderate to severe inferior oblique overaction and mild to moderate superior oblique underaction. Multiple theories that have been suggested to explain

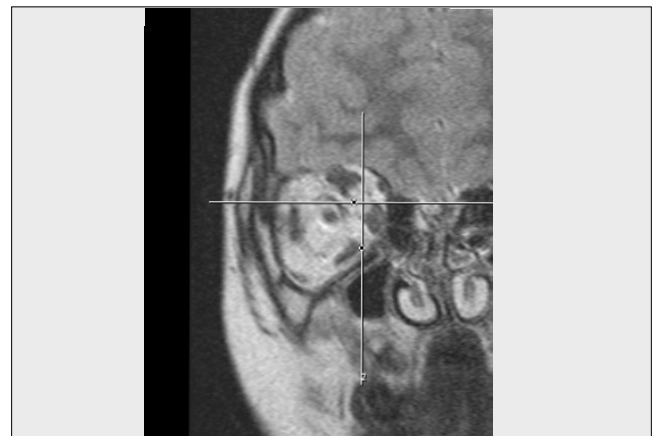

Figure 10. No asymmetry in extraocular muscle paths

these findings are shallow and exorotated orbits, which provide poor support for the globe; short orbital walls that alter the arc of contact of the globe with the extraocular muscles; disordered structure of the cranial base and trochlea, influencing extraocular muscle function; and underaction or absence of the SO.^{4,16,17}

We performed three-dimensional computerized cranial tomography and orbital MRI to evaluate orbital walls and extraocular muscles abnormalities. Orbital images are as varied as the clinical features of the craniosynostosis syndrome. Imaging studies will yield valuable information when documentation of previous surgery is unavailable, when orbital repositioning has been performed, or when there is marked apparent oblique dysfunction (such as IO overaction, SR or SO underaction). In our case, three-dimensional computerized cranial tomography showed normal and symmetrical orbital wall structures on both sides. On the other hand, orbital MRI demonstrated that all extraocular muscles in each eye were present, normal in size and shape but anatomically displaced in the right eye. Coronal views on MRI scan of the right eye showed 2 mm nasal displacement of the right inferior rectus relative to the right superior rectus muscle and 3 mm inferior displacement of the right lateral rectus relative to the right medial rectus muscle.

This counterclockwise rotation of the LR and IR muscles that causes exorotation of the globe led us to consider that the over-elevation in adduction was most likely related to the anatomical displacement of the rectus muscles. A variety of anatomical abnormalities, including anomalies of the extraocular muscles, have been reported in patients with craniofacial dysostosis. Diamond et al. were among the first to suggest that extraocular muscle anomalies were the cause of the bizarre strabismus patterns.¹² V-pattern strabismus in patients with craniosynostosis is usually not due to simple IO overaction. Some amount of IO overaction leading to a V pattern may be related to anomalous muscle vectors because of exorotation of the globe. If the muscle cone is excyclorotated, the possibility that the displaced muscle gains additional vectors, and thus an added effect on muscle action must be considered.

In general, early craniofacial surgery is preferred by the surgeons because full-thickness bone graft which has the ability to regenerate bone may be used rather than partial-thickness graft. Early repair also enhances the child's psychosocial development.^{7,8} Because of the late admission, our patient was three years old when she was operated with the diagnosis of Crouzon syndrome. After initial craniofacial repair, we planned strabismus surgery and informed the parents preoperatively of the unpredictability of the surgical response and the possible need for more than one procedure. Because of these possibilities, the parents did not accept strabismus operation. After the cranial operation, the patient was followed up for 6 years without further cranial or strabismus operation. At the end of this period, her ocular deviation disappeared in all gaze positions. In recent orbital MRI, no asymmetry in extraocular muscle paths was detected.

The change in deviation was more common in Apert syndrome than in Crouzon syndrome and even less frequent in isolated craniofacial syndromes after craniofacial reconstruction operation. Although previous studies have shown that reconstruction surgery rarely results in postoperative shift of the strabismic deviation, in our case, the angle of squint decreased gradually after the cranial operation.¹¹⁻¹³

Conclusion

Strabismus in craniosynostosis may be related to anatomical malposition of the rectus muscles. In these patients, orbital imaging can be a useful diagnostic tool revealing unexpected pathophysiologic mechanisms and aiding surgical planning. Spontaneous improvement in ocular deviation may occur, therefore, this possibility must be considered for early decisions considering surgery.

References

- Bertelson TI. The premature synostosis of the cranial sutures. *Arch Ophthalmol.* 1958;5:47-8.
- Alderman BW, Fernbach SK, Greene C. Diagnostic practice and the estimated prevalence of craniosynostosis in Colorado. *Arch Pediatr Adolesc Med.* 1997;15:159-64.
- French LR, Jackson IT, Melton LJ. A population-based study of craniosynostosis. *J Clin Epidemiol.* 1990;43:69-73.
- Carruthers JD. Strabismus in craniofacial dysostosis. *Graefes Arch Clin Exp Ophthalmol.* 1988;226:230-4.
- Tomaç S, Kalaycı D, Hasırıpı H. Synostotic plagiocephaly causing pseudoparalysis of the superior oblique and ocular torticollis: Report of a case with unique sensory findings. *Binocul Vis Strabismus Q.* 1998;13:267-72.
- Pemberton JW, Freeman JM. Craniosynostosis: A review of experience with forty patients with particular reference to ocular aspects and comments on operative indications. *Am J Ophthalmol.* 1962;54:641-50.
- Fries P, Katowitz JA. Congenital craniofacial anomalies of ophthalmic importance. *Surv Ophthalmol.* 1990;35:87-119.
- Newman SA. Ophthalmic features of craniosynostosis. *Nerosurg Clin North Am.* 1991;2:587-610.
- Carruthers JDA. Strabismus in craniosynostosis syndromes. In: Rosenbaum AL, Santiago AP, eds. *Clinical Strabismus Management.* Philadelphia: WB. Saunders;1999.P393-03.
- Helveston EM. 19 th annual Frank Costenbader Lecture—the origins of congenital esotropia. *J Pediatr Ophthalmol Strabismus.* 1993;30:215-32.
- Choy AE, Margolis S, Breinin GM. Analysis of preoperative and postoperative extraocular muscle function in surgicaltranslocation of bony orbits. A preliminary report. In: *Symposium on Diagnosis and Treatment of Craniofacial Anomalies,* St Louis, CV Mosby, 1979.
- Diamond GR, Katowitz JA, Whitaker LH. Ocular alignment after craniofacial reconstruction. *Am J Ophthalmol.* 1980;90:248-50.
- McCarthy JG. Extraocular muscle function following craniofacial surgery. In: *Proceedings of the Sixth International Congress of Plastic and Reconstructive Surgery,* Paris, Masson et Cie, 1975.
- Coats DK, Paysse EA, Stager DR. Surgical management of v pattern strabismus and oblique dysfunction in craniofacial dysostosis. *J AAPOS.* 2000;4:338-42.
- Diamond GR, Whitaker L. Ocular motility in craniofacial reconstruction. *Plast Reconstr Surg.* 1984;73:31-7.
- Cheng H, Burdon MA, Shun-Shin GA. Dissociated eye movement in craniosynostosis: A hypothesis revived. *Br J Ophthalmol.* 1993;77:563-8.
- Ortiz-Monasterio S, Feunte del Campo A, Limon-Brown E. Mechanism and correction of V syndrome in craniofacial dysostosis. In: *Symposium on Plastic Surgery in the Orbital Region,* St. Luis, CV Mosby; 1976.P. 246.